

**PELVIC ULTRASOUND FINDINGS AND ITS HISTOPATHOLOGICAL
COMPARISON IN POST MENOPAUSAL PATIENTS PRESENTING WITH
UTERINE BLEEDING AT MOI TEACHING AND REFERRAL HOSPITAL**

BY:

AYIRO, SHIVOGO ALLAN

**A THESIS PRESENTED TO SCHOOL OF MEDICINE IN PARTIAL
FULFILLMENT FOR THE AWARD OF THE DEGREE OF MASTERS IN
RADIOLOGY AND IMAGING OF MOI UNIVERSITY.**

© 2019

DECLARATION

I declare that this is my original work and has not been presented in any other university or institution for an award of any degree or any academic credit. No part of this work may be reproduced or transmitted in any form without prior permission from the author or Moi University.

AYIRO, Shivogo Allan

SM/PGR/12/15

Department of Radiology and Imaging, Moi University

Signature:..... Date

Supervisors Declaration:

This research thesis has been submitted for consideration with our approval as university supervisors

Dr. Abuya J. M

Senior Lecturer,

Department of Radiology and Imaging,

School of Medicine, Moi University.

Signature:..... Date

Dr. Omenge Orang'o

Senior Lecturer

Department of Reproductive Health,

School of Medicine, Moi University

Signature:..... Date

DEDICATION

I would to dedicate this work first and foremost to God who makes it possible at all times. Secondly to Gloria and Midika Ayiro my biggest cheerleaders and finally to my Dad, Chahilu Ayiro, a great example of sacrifice and unwavering support.

ACKNOWLEDGEMENT

I would sincerely like to thank my supervisors, Dr. J.M. Abuya and Dr. Omenge Orang'o for their guidance and support during the development of this thesis. I would also like to recognize my fellow residents for their encouragement and critique. I want to recognize Elvis Mackenzie for his encouragement and effort during the writing of this thesis.

TABLE OF CONTENTS

DECLARATION.....	ii
DEDICATION	iii
ACKNOWLEDGEMENT.....	iv
TABLE OF CONTENTS	v
LIST OF TABLES	viii
LIST OF FIGURES.....	ix
LIST OF ABBREVIATIONS:	x
ABSTRACT	xi
CHAPTER ONE	1
1.1 Introduction	1
1.2 Problem Statement.....	2
1.3 Justification of the Study.....	2
1.4 Study Limitations	3
1.5 Research Questions	3
1.6 Objective.....	4
1.6.1 Main Objective.....	4
1.6.2 Specific Objectives.....	4
CHAPTER TWO: LITERATURE REVIEW.....	5
2.1 Epidemiology of Postmenopausal bleeding	5
2.2 Normal anatomy of a postmenopausal uterus	5
2.3 Sonographic evaluation of a postmenopausal uterus.....	6
2.4 Histopathologic Evaluation:	9
CHAPTER THREE	12
RESEARCH METHODOLOGY	12

3.1 Study Design	12
3.2 Study area	12
3.3 Study Population	12
3.4 Sampling techniques.....	13
Sampling method	13
3.5 Eligibility criteria.....	13
3.5.1 Inclusion criteria.....	13
3.5.2 Exclusion criteria	13
3.6 Study Procedure.....	13
3.7 Data Collection and Management	14
3.7.1 Data Collection.....	14
3.7.2 Quality Control.....	15
3.7.3 Data Analysis and Presentation.....	15
3.9 Ethical Considerations.....	16
CHAPTER FOUR.....	17
FINDINGS	17
4.1 Introduction	17
CHAPTER FIVE	27
5.1 Discussion.....	27
5.2 Socio- demographic characteristics:-	27
5.3 Ultrasound Findings.	28
5.4 Other findings:.....	30
5.4.1 Endometrial Fluid:	30
5.4.2 Histological Diagnosis:	31
5.4.3 Endometrial Hyperplasia:.....	31
5.4.4 Endometroid carcinoma:	32
CHAPTER SIX.....	34

6.0 CONCLUSIONS AND RECOMMENDATION	34
6.1: Conclusions	34
6.2 Recommendations:	34
REFERENCES	35
APPENDICES	39
Appendix I: Consent Form	39
Appendix II: Data Collection form.....	41
Appendix III: CAP Protocol 2017	42
Appendix V: Estimated Project Budget	54
Appendix VI:Time Schedule.....	55
Appendix VII: IREC Approval	56
Appendix VI: MTRH Approval	57

LIST OF TABLES

Table 1 : Ultra sound findings	18
Table 2: Endometrial thickness summary per diagnosis	19
Table 3: Age summary per diagnosis	20
Table 4: Years past menopause summary per diagnosis	20
Table 5: Histology findings	24

LIST OF FIGURES

Figure 1: Age distribution	17
Figure 2: Post menopause period distribution	18
Figure 3: Histological diagnosis	19
Figure 4: Correlation between age and years post menopause.....	21
Figure 5: Independent –Samples Kruskal-Wallis Test.....	22
Figure 6: Pairwise Comparisons of dx	23

LIST OF ABBREVIATIONS:

AUB	Abnormal Uterine Bleeding
DnC	Dilatation and Curretage
FIGO	International Federation of Obstetrics and Gynaecology
HRT	Hormone Replacement Therapy.
IREC	Institutional Ethics and Research Committee
IUCD	Intrauterine Contraception Device
KDHS	Kenya Data Health Survey.
KMTC	Kenya Medical Training College
MTRH	Moi Teaching and Referral Hospital
TVS	Transvaginal Ultrasound
US	Ultrasound

**PELVIC ULTRASOUND FINDINGS AND ITS HISTOPATHOLOGICAL
COMPARISON IN POST MENOPAUSAL PATIENTS PRESENTING WITH
UTERINE BLEEDING AT MOI TEACHING AND REFERRAL HOSPITAL
ABSTRACT**

Background: Post menopausal bleeding is a common gynaecologic problem accounting for a significant number of yearly visits to the outpatient gynaecologic clinic.

Indeed it is associated with significant morbidity and mortality outcomes in both the developed and developing countries.

The easy availability of ultrasound as an imaging modality on most settings aids in the early diagnosis of the possible causes.

Comparison with histopathology which is the gold standard will thus help to determine the diagnostic accuracy and further aid in management.

Objective: To ascertain the diagnostic accuracy of pelvic ultrasonographic assessment in the diagnosis of postmenopausal bleeding in patients presenting at Moi Teaching and referral hospital.

Methods: This was a descriptive cross sectional study done between July 2017 and June 2018 at Moi Teaching and Referral Hospital- Eldoret, Kenya.

Consecutive sampling technique was used on consenting patients presenting with a clinical diagnosis of post menopausal bleeding. A total of 67 participants were included in the study. A structured questionnaire which had sociodemographic characteristics, the duration of bleeding and years post menopause, ultrasound findings and histopathology results was administered by the interviewer to the participants.

Categorical data was summarized using frequencies and percentages while continuous variables were summarized using means and medians. Data analysis and statistical computing was done and results presented using tables and graphs.

Results: A total of 67 participants were included in the study. The mean age was at 54.6 years with a minimum and maximum age of 48 and 62 years respectively. The years post menopause ranged from 1-15 years with a mean age of 4.6 years.

Endometrial thickness greater than 5mm was diagnosed in 31 participants accounting for 46.2% of the population. Uterine fibroids were diagnosed in 2 patients accounting for 2% of the participants while endometrial fluid was diagnosed in 2 patients accounting for 2% of the population. On Histological diagnosis, atrophic endometritis accounted for 48% of the cases. Endometrial hyperplasia was at 22%, endometrial carcinoma at 13%, chronic endometritis 8%, endometrial polyp 6% and Normal diagnosis at 3%. A level of agreement for malignancy calculated was found to be 57%.

Recommendations: An atrophic endometrium does not rule out malignancy and follow up is necessary. Chronic endometritis in our set up is a significant finding and further studies to elucidate the cause are recommended.

Conclusion: increasing endometrial thickness is associated with an increased risk in malignancy however it does not rule it out. Chronic endometritis is a significant finding in our set up on histopathological evaluation. The level of agreement between ultrasound and histopathology is low at 53%.

CHAPTER ONE

1.1 Introduction

Abnormal uterine bleeding is a common finding in patients in post-menopausal age presenting in our ultrasound clinics. Some of the causes of this abnormal uterine bleeding have been associated with a high morbidity and mortality if not diagnosed early.

A study conducted by (Van den Bosch, T, Ameye, et al, 2015) showed that of 1220 post menopausal women that underwent some form of imaging all of those that were subsequently confirmed as having confirmed malignancy after suspicion on imaging were 7% of the study population.

Proper and timely diagnosis therefore goes a long way in helping reduce morbidity and mortality associated with AUB.

Transvaginal Ultrasound in our setting remains the modality of choice in these patients.

Ultrasound as an imaging modality however is limited by the fact that it is quite operator dependent and thus a lot of observer variability exists for example in their study (Straus, Jones et al, 2007) demonstrated that subjective visual assessment of fatty liver had substantial observer variability and that there was need for a more objective and qualitative method of grading fatty liver on sonography would be more reliable.

Minimal data as regards to ultrasound findings in post menopausal bleeding is available especially in our setting and available data would lead to increased specificity in diagnosis and management of post menopausal bleeding in correlation with histopathology.

Tissue diagnosis remain the gold standard as regards the diagnosis on abnormal tissue however it requires specialized equipment and procedures that are limited in our set up and economy hence the importance of ultrasonography in making this diagnosis. In correlating

our findings and sonography we seek to test the accuracy of our diagnosis in ultrasound with the gold standard hence giving a clear picture as appertains diagnosis. Not only saving time but helping in improving the quality of care in our resource deprived setting.

1.2 Problem Statement

Gynaecological malignancies account for 1 in 4 new cases diagnosed in developing countries (Iyoke et al 2013). Abnormal uterine bleeding is a common presentation in the gynaecological unit, the most common presentation is usually in pre-menopausal women, however it has been noted that there is an increase in patients presenting with postmenopausal bleeding (Jones&Bourne, 2001). A study by (Greene et al, 2008) done in Jamaica showed that the estimated 5 year survival rate for endometrial malignancies classified to be above FIGO 3 to be at less than 10%. There is a paucity of data in this group in our setting hence the need to do this study to aide in proper management of these patients.

1.3 Justification of the Study

A large number of patients present with abnormal uterine bleeding in our set up especially in the gynaecology clinics. Different pathology as alluded to, may present with abnormal uterine bleeding- (AUB) posing a diagnostic challenge to the clinician. This can result in miss-management of the patient. Clear understanding of possible findings is therefore important as it leads to adoption of improved and standardized management options for this condition. Post menopausal bleeding has been shown to have a high association with endometriod carcinoma. (AJCC manual, 2017).

While histopathological diagnosis is the gold standard it has largely been left to academic centres in africa (Adeyi OA, 2011).

Ultra sound currently in our set up has been the imaging modality of choice in the evaluation and diagnosis of abnormal uterine bleeding. However with the paucity of information existing in our setting to clearly describe the findings demonstrated by ultrasonography and its histopathology comparison, a gap exists .Ultra sound imaging findings with this comparison will play a significant role in aiding treatment.

By reducing the paucity of knowledge in this area, this study will also help health care providers and policy makers to review and streamline the diagnosis work up and management of patients with post-menopausal AUB. This in turn is expected to reduce the morbidity, mortality, social and economic constraints attributed to this ailment..

1.4 Study Limitations

The most accurate form on pelvic sonography for this particular pathology is trans vaginal scanning. The acceptability to most patients is wanting and this may reduce the accuracy of the diagnosis of the scans done as some will have to be trans abdominal.

The cost of biopsy and histopathology evaluation will also be a challenge given the socio-economic demographics of most of our patients.

1.5 Research Questions

This study sought to answer the following question

1. What are the sonographic findings and the histopathological comparison in post menopausal patients presenting with abnormal uterine bleeding at MTRH.

1.6 Objective.

1.6.1 Main Objective.

The study will seek to answer the following questions:

1. What are the sonographic findings of patients presenting with post – menopausal bleeding and their comparison to histopathological findings.

1.6.2 Specific Objectives

1. To determine the predominant ultra sound findings in patients presenting with abnormal post menopausal uterine bleeding at Moi Teaching and Referral Hospital- MTRH.
2. To compare the ultrasound findings to the histological findings after curettage or biopsy.
3. To ascertain the level of agreement between sonographic and histopathological findings for diagnosis of malignant disease.

CHAPTER TWO: LITERATURE REVIEW

2.1 Epidemiology of Postmenopausal bleeding

Menopause is defined as a continuous 12 month period of amenorrhea. (ACOG).

Post menopausal bleeding refers to any uterine bleeding in a menopausal woman (other than expected cyclic bleeding that occurs in women taking sequential postmenopausal therapy. Indeed in their study at the Nelson Mandela school of medicine in 2012, (Moodley & Robert, 2012) found that it accounted for 5% of all gynecological visits. Vaginal bleeding occurs in 4-11% of postmenopausal women. The most common cause of vaginal bleeding in these women being caused by atrophy of the endometrium and vaginal mucosa according to Smith P et al in their article published in the *minimally Invasive gynecology journal* of 2014.

2.2 Normal anatomy of a postmenopausal uterus

Normal unstimulated postmenopausal endometrium consists only of the basalis layer, there should be no functional layer, the atrophic basalis layer should be less than 1 mm wide when a full thickness single wall is fixed on a slide (Gompell, Silverberg et al, 1994). Sonographically this very thin hyperechoic layer clearly demarcates the endometrium from the hypoechoic layer of myometrium – (Fleischer, Dudley et al 1986) this image is blurred and distorted when glands invade the myometrium – (Fleischer, Kalameris et al ,1987). Or it may probably be due to endometrial cancer or extensive adenomyosis, or when impinged upon by abnormal myometrium, as with myomata or sarcoma, (Fleischer, Dudley et al, 1989).

2.3 Sonographic evaluation of a postmenopausal uterus

Sonographic evaluation of the uterus is mainly done through two main ways. The transabdominal approach and the transvaginal approach. A pelvic ultrasound is a non-invasive diagnostic exam that produces images that are used to assess structures and organs within the female pelvis. Ultrasound uses a transducer that sends out sound waves that are at a high frequency that cannot be heard by the human ear. The choice of type of ultrasound to be done is dependent on the examination to be carried out.

A transabdominal ultrasound involves placing a transducer on the skin of the abdomen after applying coupling gel and the high frequency waves sent that traverse through the body organs and structures within it. The sound waves bounce off the organs like an echo and return to the transducer. The transducer then processes the reflected waves and then they are converted by a computer into an image of the organs or tissue being examined. The use of gel is so as to eliminate the transducer and air interface as sound waves traverse poorly through air.

Transvaginal ultrasound is done akin to a speculum examination. The procedure is done in a sterile manner and the probe is introduced in a 'sterilized' manner by use of a covering or a glove before it is inserted through the vagina to enable visualization of pelvic organs negating the abdominal wall interference. Lesions less than 5 mm in the widest diameter are not accurately reported by transabdominal sonography. Transvaginal sonography is the modality of choice to use as it provides improved resolution albeit with a limited field of view. (Weismann, & Barloon, 1996).

Sonographic size of the endometrium therefore reflects the presence or absence of significant hyperplasia or an intraluminal tumour or lesion. This thus presents the need for

sonography to help evaluate and either recommend or remove the need for biopsy of a senile and symmetrical uterus. Information of the image is thus best done in correlation with past medical history and treatment informed by this functional understanding of the uterus.

The expected uterus image of a normal untreated post-menopausal uterus, viewed in mid sagittal section at an angle of insonation of the uterine axis of between 60degrees and 90 degrees includes two very thin basalis condensed with the specular reflection of the luminal interface into a regular stripe with a thickness of 4mm or less. This measurement should also be correlated with uterine symmetry as asymmetry in this layer is the hallmark of abnormality. (Cecchini, Ciatto et al, 1996)

Many investigations have concluded that there is a sonographic threshold of 4mm for a normal endometrial thickness in bleeding post-menopausal woman below which neither atypical hyperplasia or cancer is likely to be found (Goldstein, Natchigall et al, 1990). A meta analysis done by (Gupta et al , 2002) however showed that a cut off of 5 mm was recommended as the threshold when evaluating the endometrium in post menopausal patients. However it isalso appreciated that malignancy can be found in patients with an endometrial thickness of less than 3 mm and hence emphasizing the need of holistic clinical management. (Doram et al, 1993)

In the article ‘the feasibility of ‘one stop’ ultra sound based clinic for the diagnosis and management of abnormal uterine bleeding’’ (Jones, Bourne et al. 2001) in which they correlated their results with histology, uterine pathology was detected on Transvaginal Scan- (TVS) scan in 47.2% of cases.

(Van den Bosch, Ameye et al, 2012), using the criteria of patient characteristics, bleeding patterns, endometrial thickness and ultrasonography in a study of 1220 women found that of all the 37% that were post menopausal, 3% that had cancer on histopathology, all were post menopausal.

With pelvic ultrasound it has been shown that the average endometrial thickness of a normal atrophic uterus is on average 2.3mm, some studies have however shown that advanced endometrial cancer can exist without noticeable endometrial thickening. (Dorum, Langebrenke et al, 1993) in their meta analysis carried out in studies from 5 centres found the specificity of ultrasound to be 80% when compared to histology and specificity at 60% of the 100 women studied preoperatively in this study. Of the 54 women graded as having uterine thickness of less than 5mm, 3 were found to have malignancy and of the 45 patients with endometrial thickness of more than 5mm 12 were found to have malignancy.

A study done in 1988 by (Coleman, Arger et al, 1988) showed that clinical diagnosis was altered on basis of transvaginal ultrasound findings in 54 of the 240 cases that were involved in the study. This accounted for about 24% of the study population. It also confirmed with certainty 166 cases that were diagnosed on trans abdominal ultrasound and this accounted for atleast 72% of the study population. Only 10% of the cases that were a diagnostic challenge on transabdominal ultrasound were unresolved after a transvaginal ultrasound highlighting its diagnostic superiority as compared to trans abdominal ultrasound. A meta-analysis done by (Smith-Bindman, Kerlikowske et al, 1988) showed that transvaginal ultrasound had a sensitivity of 92% and a specificity of 81%. A study done by (O'Connell. Fries et al, 1998) recommended that all post menopausal women especially should undergo transvaginal sonohysterography instead of regular sonography

due to its high specificity and sensitivity and the likelihood of malignancy in this population so as to be as accurate as possible with the diagnosis.

2.4 Histopathologic Evaluation:

Endometrial assessment by means of biopsy or sampling of endometrial cells is a minimally invasive alternative to dilatation and curettage as a means of uterine evaluation. In a study on the accuracy of outpatient endometrial biopsy in diagnosing endometrial cancer (Clark et al, 2002) showed that outpatient biopsy has a high overall accuracy if an adequate sample is collected.. Biopsy taking involves a mini surgical procedure that allows one to take a small tissue sample either under general anaesthesia or as a side room procedure that is then processed by the pathology department and a microscopic or chemical analysis done. It is the gold standard for any pathological disease process as it studies the cell morphology and chemical characteristics allowing us to distinguish between the normal and abnormal.

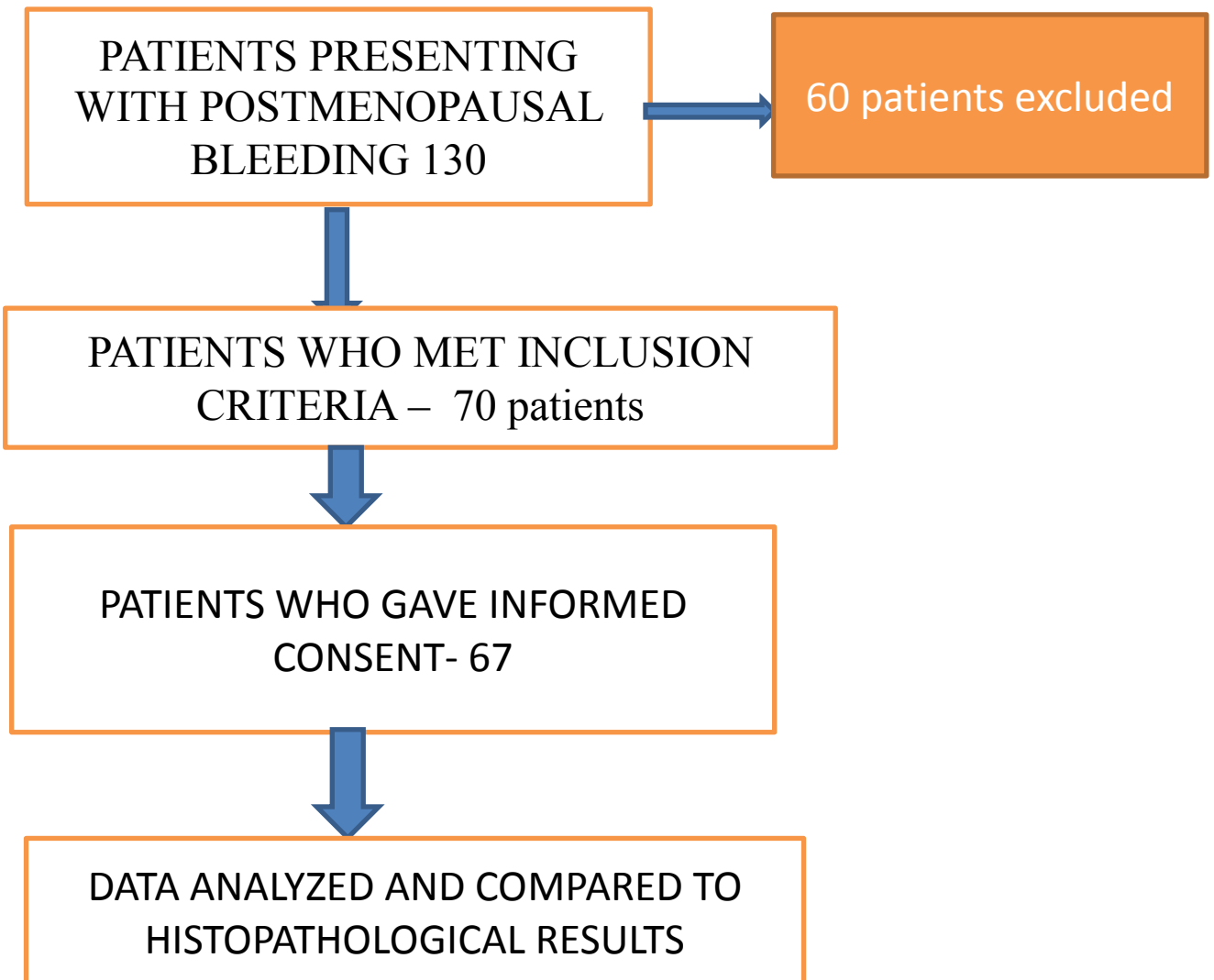
It is however costly and labour intensive as it involves a minor surgical procedure and eventual pathology based evaluation of the tissue sample.

Traditional D and C methods have now been overtaken by hysteroscopy guided biopsies that help in a more accurate detection of focal lesions according to a study by (Kotdawala, Kotdawala et al, 2013).

In a study done by (Dubinsky, Stroehlein et al. 1999) a recommendation based on the findings of histopathology suggested that all women with suspicious endoluminal masses required further evaluation to exclude malignant disease as what had been previously been thought to be benign was on histology found to be malignant in some of the cases. In essence tissue diagnosis should be the main mode of diagnosis however this requires

highly specialized personnel and equipment. This fact is indeed backed by a study done by (Giusa-Chifari, Gonclaves et al, 1996) that showed that histopathology only erred in one of the patients in the study in coming to a final and correct diagnosis. The need for anesthesia and probable surgical procedure raises the cost and the ease of doing histopathology especially in our resource constrained environment. In advanced set ups where biopsy can be carried out in side rooms or clinics, coupled with easy availability of personnel and equipment the routine nature in which this biopsy can be carried put greatly enhances patient care. The reality is that in our set up very few centers have access to pathology evaluation and the availability of ultrasound makes it a significant tool for diagnosis in our set up. When biopsy is required one has to go to specific centres and this is not only crippling in time but also adds a cost to the patient that can be bypassed with increased accuracy of diagnosis by ultrasound aiding in quick and appropriate management like surgical intervention through i.e hysterectomy as one can then safely await for pathologic diagnosis while negating risk of spread or deterioration of the disease.

In this study the biopsy done shall be reported by two consultant pathologist and shall adopt the **COLLEGE OF AMERICAN PATHOLOGIST 2017 PROTOCOL** in reporting the findings for malignant tumors



CHAPTER THREE

RESEARCH METHODOLOGY

3.1 Study Design

This was a cross sectional study where all patients parenting with post menopausal bleeding referred for ultrasound will be evaluated.

3.2 Study area

This was carried out at the radiology and imaging department, wards, and outpatient department of Moi teaching and referral hospital Eldoret. The hospital is within Eldoret town, Uasin Gishu County, which is 300 kilometers North West of Nairobi. MTRH is a level 6 facility serving as a teaching hospital for Moi University School of medicine, Nursing, Public health and dentistry.

Other institutions that utilize the facility are Kenya Medical and Training center (KMTC) University of Eastern Africa Baraton. As well as serving as a training center its also the main referral hospital for the western part of Kenya and has a catchment population of approximately 13 million people.

3.3 Study Population

The study population will be all post – menopausal women presenting with abnormal post menopausal uterine bleeding at MTRH that are referred for ultra sound evaluation. Target population will include both out and inpatients.

3.4 Sampling techniques

Sampling method

This was a census study where we had a total 67 patients (previous year 55 patients presented for ultrasonography.)

3.5 Eligibility criteria

3.5.1 Inclusion criteria

1. New Patients presenting with post menopausal bleeding who are referred to the radiology department and consented to this study.

3.5.2 Exclusion criteria

1. Any patient who is on management for a known abdominopelvic malignancy.
2. Any patient on any hormone replacement therapy
3. Patient who did not consent.

3.6 Study Procedure

All postmenopausal women presenting with abnormal uterine bleeding referred for ultrasonography-(US) and who meet the inclusion criteria will be scanned. All the examinations will be performed by the principal investigator or by a trained assistant on duty using one of the available ultrasound machines.

Pre-warmed coupling gel will be applied to the transducer.

Through aseptic technique the ultrasound probe was covered with a condom,lubricated and consequently introduced through the vagina.

The uterus was then scanned and viewed in a mid saggital section at an angle of insonation of the uterine axis at between 60 and 90 degrees.

Examination will be aimed at localizing the pathologic lesions and uterine texture and consistency, characterizing the lesions in terms of echo-texture, definition of outline, determination of the size and extent of the lesion. Transverse and longitudinal side-by-side images of Data is captured in the form of hard copy sonograms. Images are also saved in the ultrasound machine computer memory and compact disks. Image interpretation will be done by the principal investigator and later reviewed by at least two senior radiologists. The abnormalities detected are described and a diagnosis made on the basis of characteristic sonographic appearances. Standard definitions of ultrasound pathology will be used.

The socio-demographic and radiological data will be entered into a data sheet. The data tools will be kept in a secured cabinet during the study period to ensure no access to unauthorized persons.

3.7 Data Collection and Management

3.7.1 Data Collection

Data was collected between July 2017 and June 2018. Entry was made in the questionnaires and later transferred to a computer database. Double entry was used to ensure accuracy of the data. All patient details were kept confidential and data was only available to the investigator and the supervisors via password access. Patients were given a copy of their results and had autonomy over who else can view their scan result(s).Serial numbers were used in order to protect patients' identity. At the end of each day data collection forms were verified for completeness and coded

3.7.2 Quality Control

All US scans were done at MTRH US room that has internal quality controls. This was done as when the patient was sent for the scan. The scans were done by the Principal Investigator conducting the study. Images were then reviewed by two consultant radiologists. All suspicious findings on scans of patients undergoing sonography were recommended for a biopsy and were done by a consultant gynecologist or a registrar under supervision subjected to histopathological review and the findings were compared.

3.7.3 Data Analysis and Presentation

Data analysis was conducted using STATA version 13 SE. Categorical. Continuous variables such as age were summarized as mean and the corresponding standard deviation if they assumed the Gaussian distribution. If Gaussian assumptions were violated then the median and the corresponding inter quartile range was used to summarize these characteristics. Gaussian assumptions were assessed using Shapiro-Wilk test for normality. Comparison of the continuous variables were done using two sample t-tests if the Gaussian assumptions are satisfied otherwise the nonparametric analogue (two samples Wilcox rank sum test) were used. Correlation between continuous variables were done using Pearson product moment correlation coefficient if the Gaussian assumptions are satisfied otherwise the Spearman rank correlation (a nonparametric analogue) were adopted. Results were presented using tables and graph. Results shall then be presented for publication in refereed journal.

3.9 Ethical Considerations

Approval to carry out the study was sought from the Institutional Research and Ethics Committee (IREC) and the Director of Moi Teaching and Referral Hospital. Informed consent was sought from patients/guardians. All patients/guardians were informed about the study and the procedures involved in the study and the possible benefits and harm to them and that the procedure is generally safe but has potential risks. Regarding the necessity of the investigation for management of the patient, consent was sought from the hospital management and IREC to allow studying of the sonograms of the patients who have undergone evaluation. All patients received medical attention as necessary regardless of whether they did or did not consent to participate in the study. No incentives or inducements were used to lure patients to participate in the study. Patients were informed of their results and appropriate standard treatment given. Confidentiality was maintained throughout the study. The data collection forms used did neither contain the names of the patients nor their personal identification numbers. Data collecting material was kept in a locked cabinet during the study period. The results of the research were presented to the Hospital's management and the university's department of Radiology and Imaging for use as necessary. It will also be available for academic reference in the College of Health Sciences Resource Centre. The results of this research shall be availed for publication in a reputable journal of medicine for use by the wider population in the general improvement of patient management and as a reference for future use.

→

→

→

CHAPTER FOUR

FINDINGS

4.1 Introduction

The findings herein are based on 69 patients who presented with post-menopausal uterine bleeding to MTRH and they had endometrial ultrasound taken. Those who were suspicious endometrial malignancy had biopsy taken for histology. Those whose diagnosis could be a high index of certainty I.E uterine fibroids we not subjected to further histopathologic evaluation.

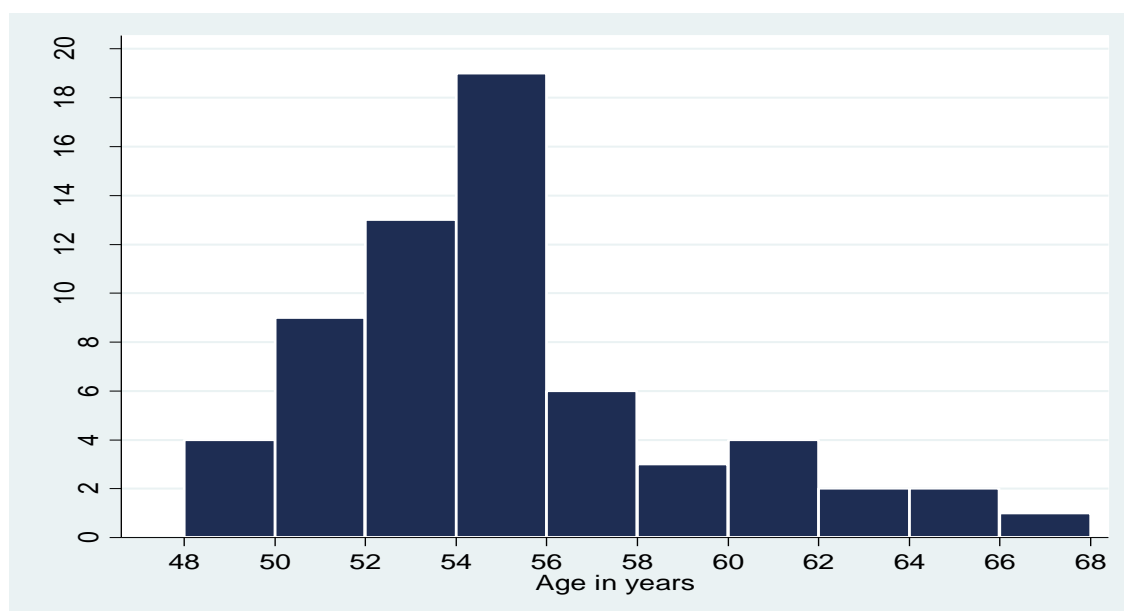


Figure 1: Age distribution

The age distribution of the patients was slightly skewed to the right ($W=0.938$, $p=0.003$), ranging from 48 to 68 years and an average of 54.7 (SD 4.1) years. The median age was 54 years IQR 52, 57).

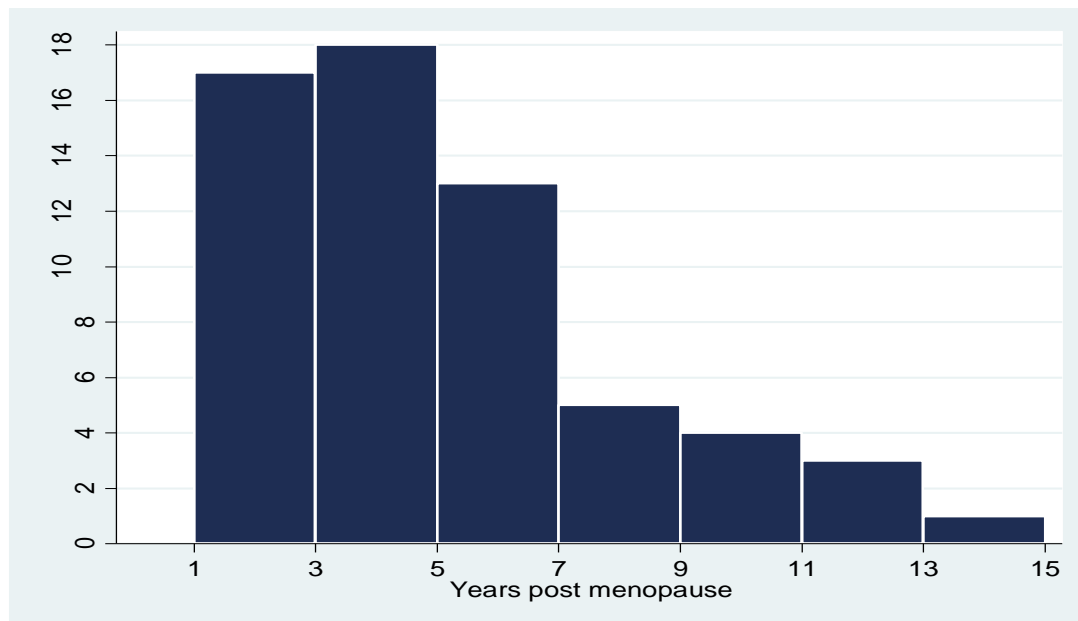


Figure 2: Post menopause period distribution

The years post-menopause ranged from 1 to 15 years with mean of 4.6 (SD 3.1) and a median of 4 (IQR 2, 6). The distribution of post-menopausal period was skewed to the right having more than $\frac{3}{4}$ (79.4%) of the patients whose years were below 7.

Table 1: Ultra sound findings

Findings	Frequency	Percent
<5mm	32	47.8
\geq 5mm	31	46.2
Uterine fibroid	2	3.0
Endometrial fluid	2	3.0

At ultrasound two patients had uterine fibroid and another two had endometrial fluid. This patients were thus not subjected to further histologic evaluation.

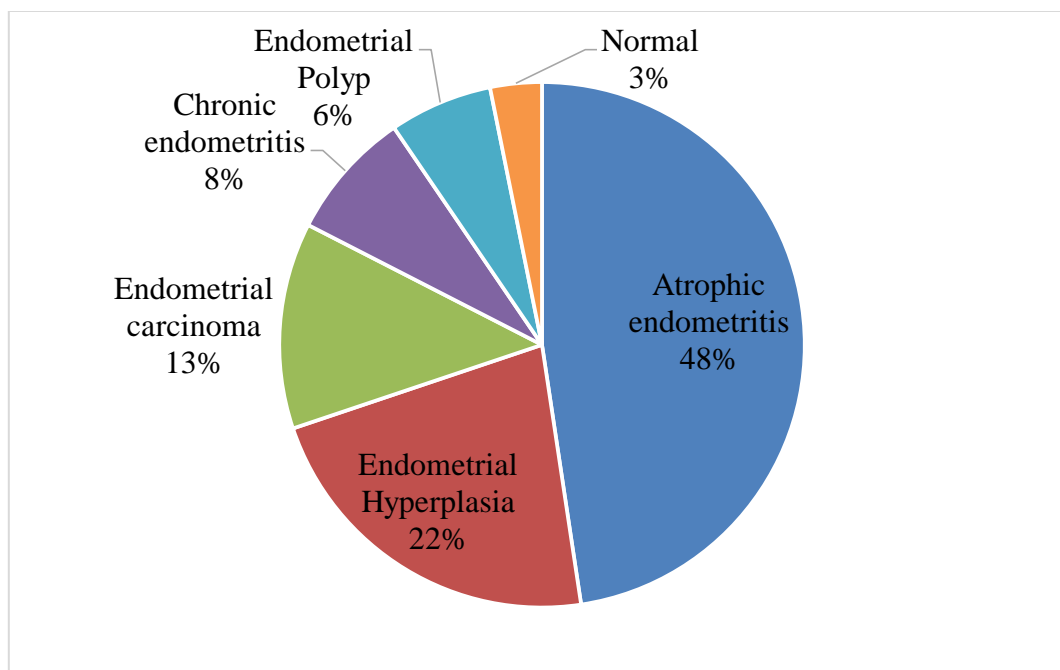


Figure 3: Histological diagnosis

Table 2: Endometrial thickness summary per diagnosis

Diagnosis	N	Ultrasound findings (endometrial thickness in mm)			
		Mean (SD)	Median (IQR)	Minimum	Maximum
Atrophic endometritis	30	3.25(0.47)	3.1(3, 3.5)	2.5	4.2
Chronic endometritis	5	5.78(0.72)	5.6(5.4, 6)	5	6.9
Endometrial hyperplasia	14	5.94(0.43)	6(5.5, 6.4)	5.2	6.5
Endometrial polyp	4	6.65(0.3)	6.6(6.4, 6.9)	6.4	7
Endometrial carcinoma	8	6.1(1.63)	6.5(5.1, 7.1)	3.4	8
Normal	6	5.8(0.28)	5.8(5.6, 6)	5.6	6

Table 3: Age summary per diagnosis

Diagnosis	N	Age in Years			
		Mean (SD)	Median (IQR)	Minimum	Maximum
Atrophic endometritis	30	52.33(2.35)	52.5(50, 54)	48	57
Chronic endometritis	5	55.20(1.09)	55.0(55, 55)	54	57
Endometrial hyperplasia	14	56.79(3.53)	56.0(54, 60)	52	64
Endometrial polyp	4	51.75(1.71)	51.5(50.5, 53)	50	54
Endometrial carcinoma	8	61.37(3.46)	60.0(59, 63.5)	58	68
Normal	6	53.5(0.71)	53.5(53, 54)	53	54

Table 4: Years past menopause summary per diagnosis

Diagnosis	N	Years past menopause			
		Mean (SD)	Median (IQR)	Minimum	Maximum
Atrophic endometritis	30	2.77(1.07)	3(2, 3)	1	5
Chronic endometritis	5	5.7(0.67)	6(5,6)	5	6.5
Endometrial hyperplasia	14	6.36(2.90)	5(4, 7)	4	12
Endometrial polyp	4	2(0.82)	2(1.5, 2.5)	1	3
Endometrial carcinoma	8	9.75(2.60)	9(8, 11)	7	15
Normal	6	3(1.4)	3(2, 4)	2	4

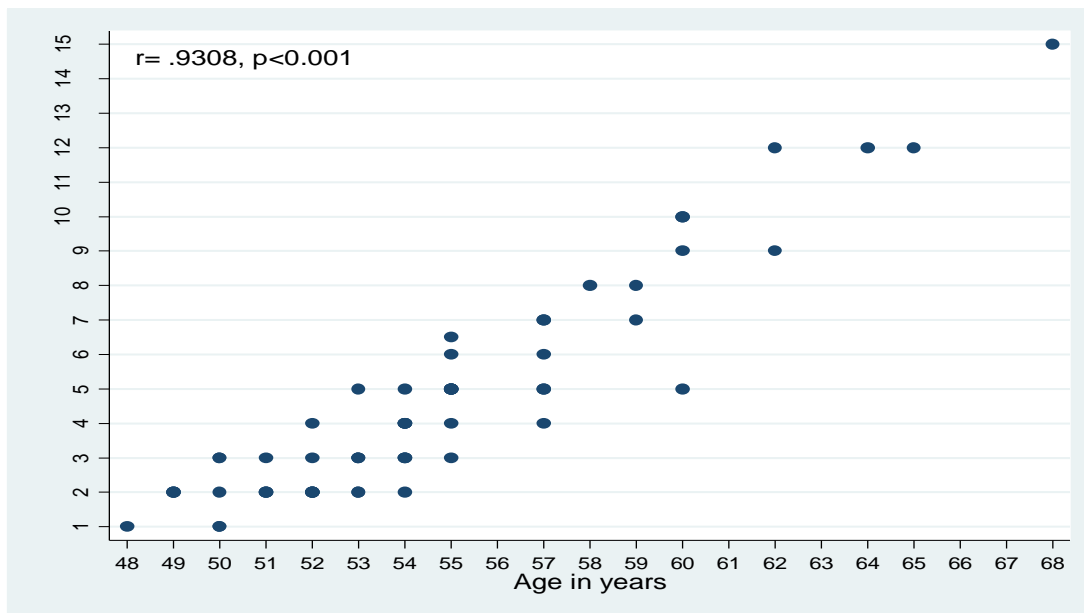
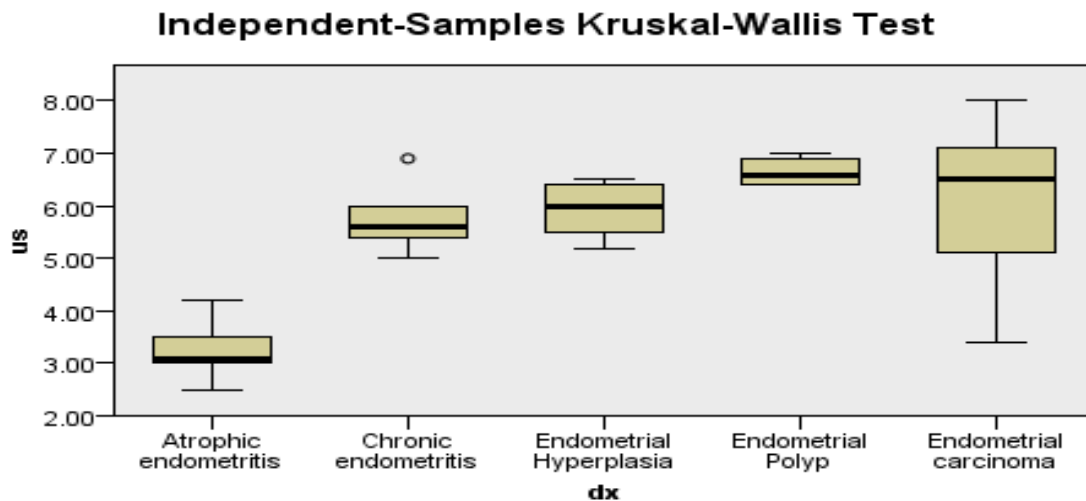


Figure 4: Correlation between age and years post menopause

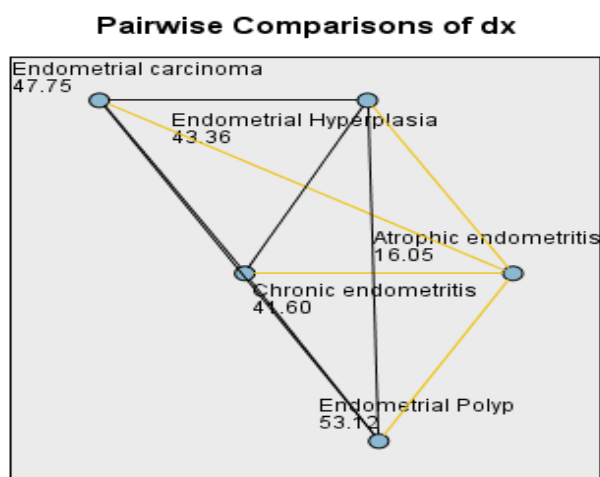
Women in this study tend to have same age at the start of menopause, the youngest at the start of menopause was 47 years and oldest 55 years.



Total N	61
Test Statistic	43.379
Degrees of Freedom	4
Asymptotic Sig. (2-sided test)	.000

1. The test statistic is adjusted for ties.

Figure 5: Independent –Samples Kruskal-Wallis Test



Each node shows the sample average rank of dx.

Sample1-Sample2	Test Statistic	Std. Error	Std. Test Statistic	Sig.	Adj.Sig.
Atrophic endometritis-Chronic endometritis	-25.550	8.555	-2.986	.003	.028
Atrophic endometritis-Endometrial Hyperplasia	-27.307	5.733	-4.764	.000	.000
Atrophic endometritis-Endometrial carcinoma	-31.700	7.047	-4.498	.000	.000
Atrophic endometritis-Endometrial Polyp	-37.075	9.427	-3.933	.000	.001
Chronic endometritis-Endometrial Hyperplasia	-1.757	9.227	-.190	.849	1.000
Chronic endometritis-Endometrial carcinoma	-6.150	10.097	-.609	.542	1.000
Chronic endometritis-Endometrial Polyp	-11.525	11.881	-.970	.332	1.000
Endometrial Hyperplasia-Endometrial carcinoma	-4.393	7.850	-.560	.576	1.000
Endometrial Hyperplasia-Endometrial Polyp	-9.768	10.041	-.973	.331	1.000
Endometrial carcinoma-Endometrial Polyp	5.375	10.846	.496	.620	1.000

Each row tests the null hypothesis that the Sample 1 and Sample 2 distributions are the same. Asymptotic significances (2-sided tests) are displayed. The significance level is .05.

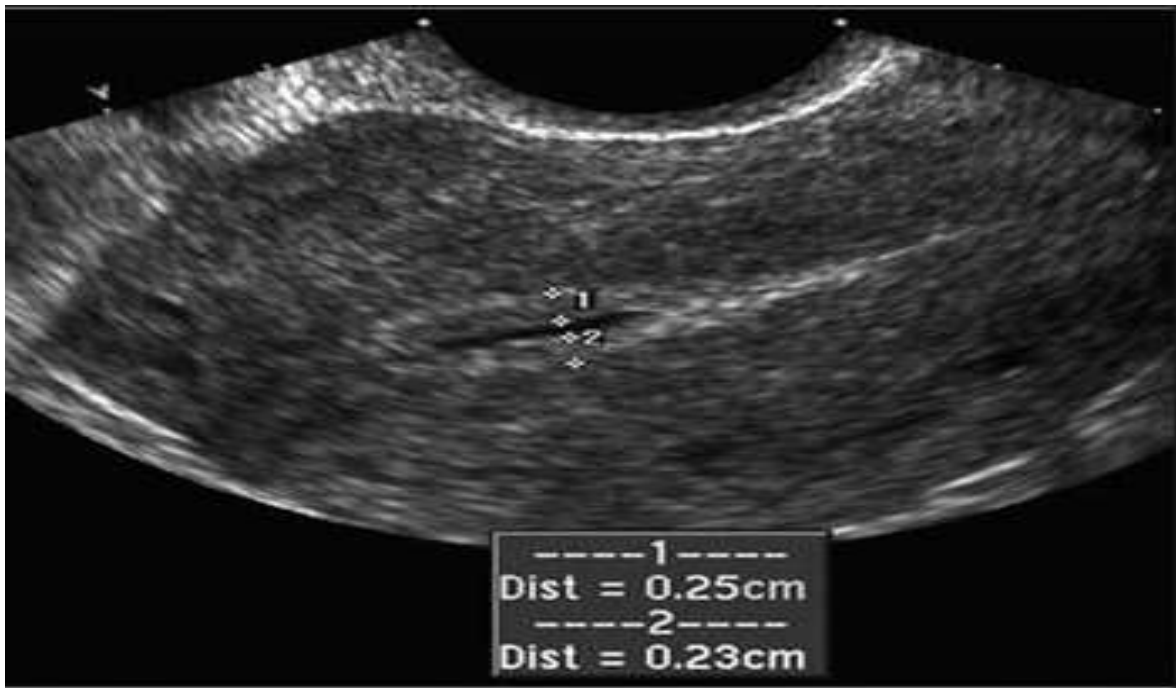Figure 6: Pairwise Comparisons of dx

Table 5: Histology findings

US findings	Histology findings		Total
	Malignant	None malignant	
Suspicious ($\geq 5\text{mm}$)	6	25	31
Benin ($< 5\text{mm}$)	2	34	36
Total	8	55	67

The total row level of agreement was $36/67=53\%$

Sample images

**Figure 7: Atropic endometrium**

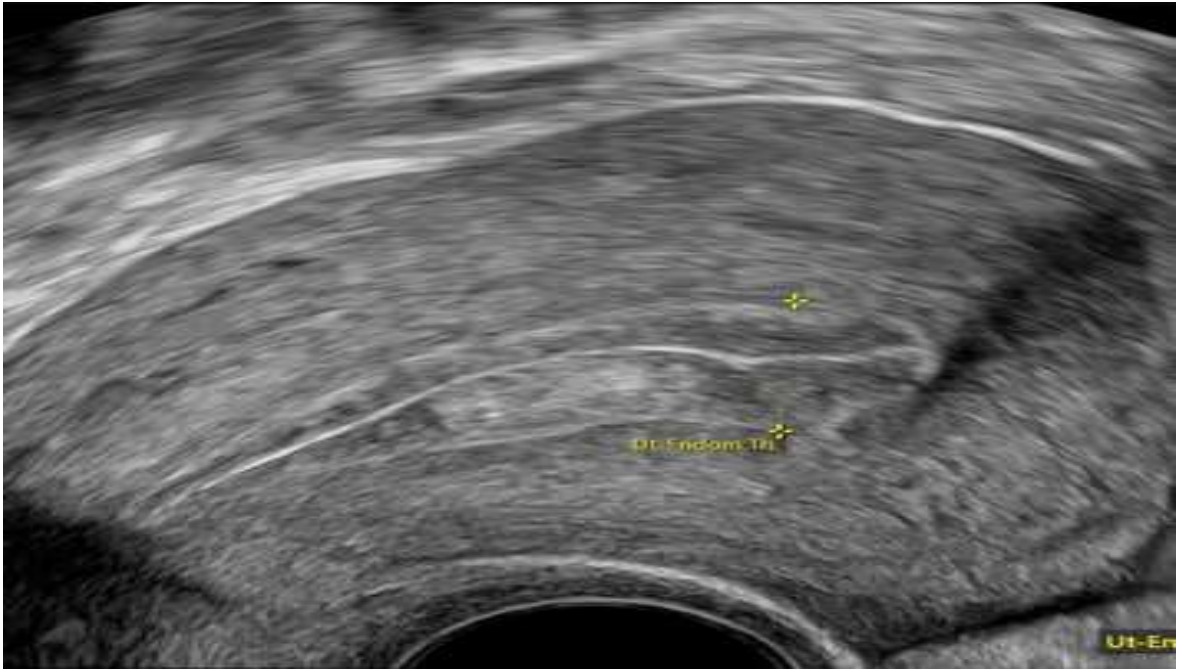


Figure 7: Thickened Endometrium

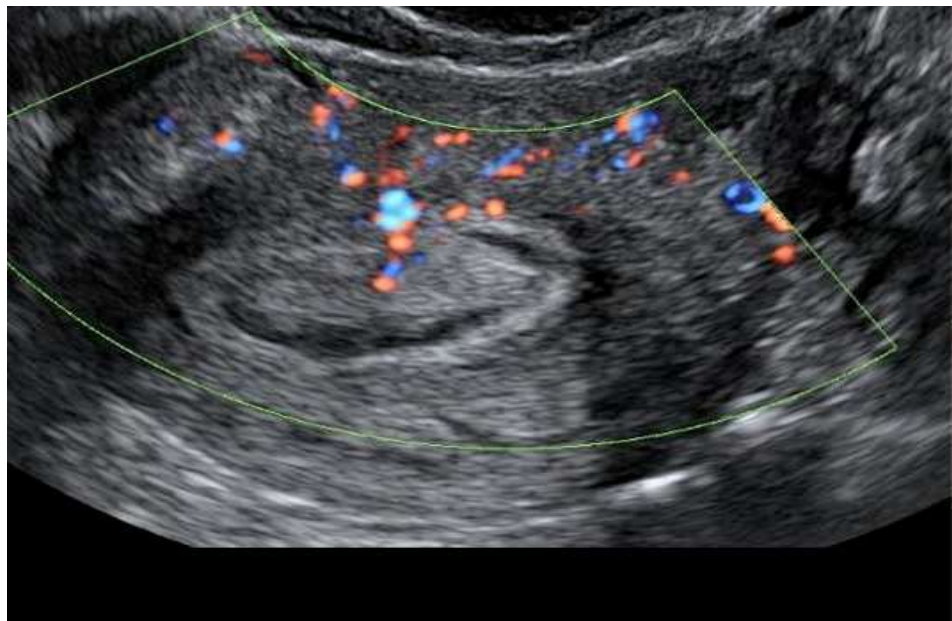


Figure 8: Endometrial Polyp

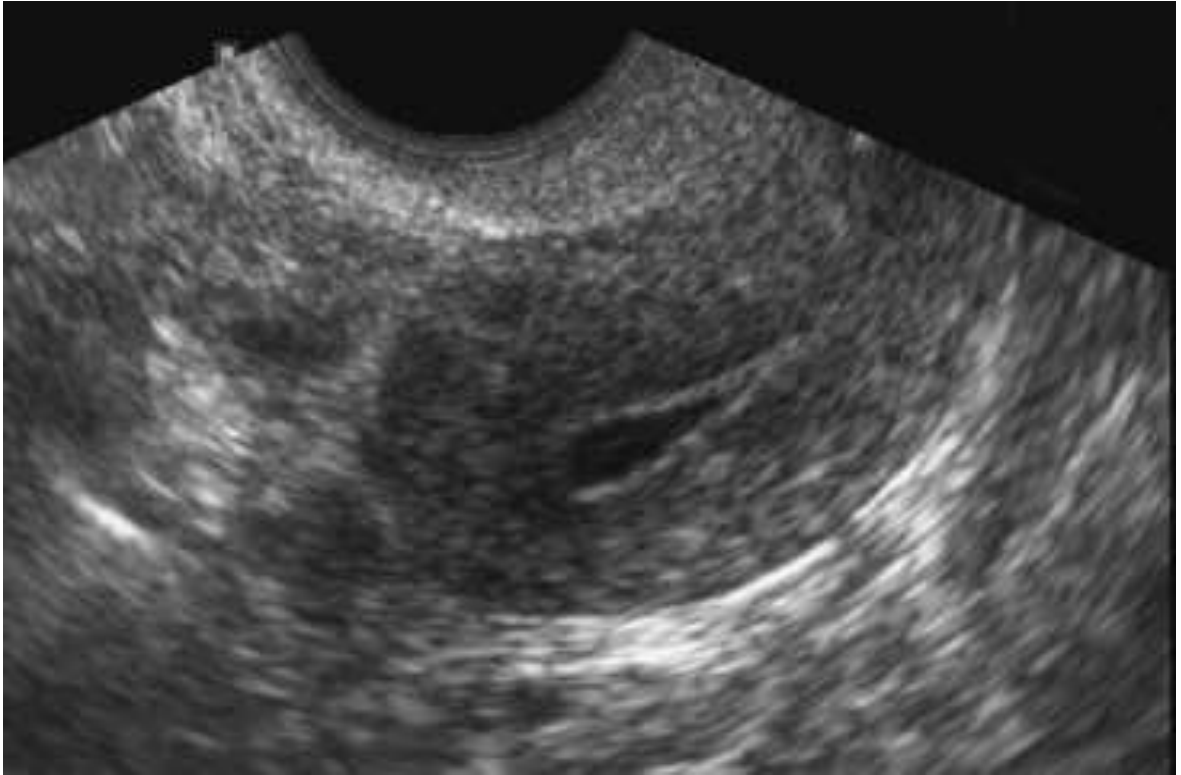


Figure 9:Endometrial Fluid

CHAPTER FIVE

5.1 Discussion

The purpose of this study was to determine the reliability of sonography to detect malignancy in comparison to post surgical histopathologic findings with the use of histopathology as the gold standard.

According to (Arthur and Stephen, 2001) sonography has become the modality of choice in the initial evaluation of gynaecological pathology like masses.

Sonography in this regard helps in localization of pathology in relation to its location , size and likely diagnosis.

In many circumstances it also aides in differentiation of likely malignant lesions from benign lesions. Sonography thus greatly aides in decisions that appertain to clinical management of patients with gynaecological ailments and will determine if there is a need for surgical intervention. (Jabeen, 2006).

5.2 Socio- demographic characteristics:-

Majority of the study participants, 74% hail from Uasin Gishu and Elgeyo Marakwet counties.

This reflects the utilization pattern of MTRH. Patients are also referred from other counties in Nyanza, Western and Rift Valley region.

The mean age of the participants was 54.6 years of age with a distribution range of 48-62 years with a majority being above 50 years of age. The mean age of those with benign masses was 53 years compared to 59 years for those confirmed by histology to have malignancies. Gynaecologic pelvic masses are widely recognized to occur in women of all ages in varying frequencies,. Borgfeldt and Andolf, 1999).

Advancement in age is a strong determinant in the occurrence of malignancy in women. Malignancies have been shown to be common in those aged above 50 years and benign lesions dominate the under 50 category. (Hernandez, Miyazawa, 1988) .(Ch Schem, Bauersclag, Meinhold-Heerlin, Fischer, Maas, 2007).

In this study the mean age of malignant causes was 59 years. Which is in keeping with the increase in age statistic.

In a study by (Gonzalez- Bosquet, Martinez-Palopez, Garcia-Jiminez, Xercaviris, 1997). It was found that the mean age of development of sarcomas was 60 years of age.

This findings thus have serious practical implications on radiologists when evaluating pelvic masses in women of advanced post menopausal age. A high index of suspicion should be a guiding paradigm in this group of patients as the likelihood of malignancy is high.

5.3 Ultrasound Findings.

Ultrasound provides an important adjunct to clinical examination in the evaluation of gynaecologic maladies. According to (Munir, Sultani and Amin , 2010). Ultrasonography is key to confirmation of the presence of a mass, its origin, size and consistency. This characteristics aid greatly in determining the likelihood of the benign or malignant nature of a lesion.

In this study the most common sonographic finding was uterine atrophy which accounted for 48.7% of our study population. This is in agreement with (Goldstein et al, 1988) who in their study found uterine atrophy to be the most common presentation in patients presenting with post menopausal bleeding.

(O'Connor et al, 1991), has endometrial hyperplasia as the most common presentation in their study and this could be possibly explained by the increased age post menopausal of their study participants.

(Ferrazi et al 1996), through their study showed that one can safely with a measurement of below 4mm safely predict endometrial atrophy and hence justify expectant management of this patients.

On average patients in our study who had an endometrial thickness greater than 5mm in whom a diagnosis of endometrial hyperplasia was made had a mean thickness of 6.2mm on ultrasound.

A number of studies have indeed validated sonography in the evaluation of gynaecologic masses.

In Ong's study (Ong, Duffy & Murphy, 1996) Showed that sonography had a high positive predictive value for the anatomic characteristics of masses. A study done in south Africa by (Phillip et al, 2003) compares favourably with this study in terms of measurement classified as hyperplasia with their study recording a mean of 6.99mm as compared to this study that had a mean of 6.2mm

However a study done in Sweden by Nasri et al, 1966) sharply contrasts with our findings and this could be attributed to the fact that there is widespread use of hormone replacement therapy in their setting contrasting with our set up. Moreover the advent of late menopause in their setup due to HRT use also contributes to this factor.

In our study we found that at least 3% of our findings we diagnosed as uterine fibroids. In general uterine fibroids are the most common gynaecologic masses found in the general population.

However the relative risk is greatly reduced from 0.6 to 0.1 in post menopausal women. (Pazzini et al 1988). This phenomenon is explained by the drastic decline in estrogen and progesterone levels in post menopausal women. Ovarian activity is essential for fibroid growth and most fibroids shrink after menopause.

Most studies on gynaecological malignancy showed that cervical cancer was the most common cause of gynaecological malignancy. A study by (Ugwu et al 2011) in Nigeria showed that it accounted for 78% of abnormal uterine bleeding.

(Nkyekyer, 2000) in Ghana also had similar findings. Going by this and widespread research cervical cancer remains the biggest cause of abnormal uterine bleeding in both the pre and post menopausal age groups but the incidence is low in our study because this patients are not routinely sent for sonography for initial diagnosis. Clinical diagnosis remains the mainstay with colposcopy and tissue biopsy the next step in management.

5.4 Other findings:

5.4.1 Endometrial Fluid:

Endometrial fluid collection in an otherwise non thickened endometrium was found in 2 subjects. According to a study done by (Curcic et al, 2009). The presence of endometrial fluid detected by transvaginal ultrasound is a good marker for pathologic changes of the endometrium in post menopausal women if the endometrial thickness is greater than 4mm. However if it is less than 4mm the presence of endometrial fluid is not an indication for further invasive investigation of the endometrial cavity, but we must eliminate the possible presence of adnexal or cervical malignant disease in some patients.

It is worthwhile to note that normal atrophic post menopausal endometrium in association with cervical stenosis can also produce endometrial fluid collections. (Goldstein SR, 1994.).

5.4.2 Histological Diagnosis:

Atrophic endometritis accounted for 48% of our study population, N=30 with a mean of 3.25mm on ultrasound in terms of thickness.

With the onset of menopause there is associated decline of oestrogen and progesterone. These hormones are key in maintaining the endometrial integrity during the pre menopausal era.

Post menopausally there is an associated sharp decline in these hormones noted. (Osmers et al, 1996). A study done by (Nasri et al, 2012), compared well with our findings. In their findings they found that up to 51% of patients who presented with post menopausal bleeding had upon histopathological diagnosis been proved to have endometrial atrophy.

(Phillips, et al 2004) in their study in African American women in Jamaica found that 70% of women with endometrial thickness less than 5mm had benign pathology with endometrial atrophy the predominant finding.

5.4.3 Endometrial Hyperplasia:

It is defined as proliferation of glands of irregular size and shape with a noted increase in the glands stromal ratio.

Endometrial hyperplasia is a known precursor to endometrial carcinoma.

In our study it accounted for 22% of the cases in histopathology. This accounted for 14 of the total 67 participants. On ultrasound these patients had a mean thickness of 6.36 with SD (2.90). A study by (Escoffrey & Blake, 2002) in Jamaica showed similarity to our study as endometrial hyperplasia on histopathology accounted for 22.3% of their patients.

Endometrial hyperplasia though commonly diagnosed in post menopausal women can occur in any woman with an unopposed estrogen exposure. (Montgomery, 2004).

5.4.4 Endometroid carcinoma:

This is the most common gynaecologic malignancy in post menopausal women in the developed countries and the 4th most common in total. The most common histologic variant is endometrioid adenocarcinoma. (Cornelia et al 2006). In our study it accounted for 13 % of the total population. In their study done in United States (Siegel et al, 2015) had a figure of 7 %

Older patients at diagnosis were mostly patients who were on hormone replacement therapy for long periods showing the risk that unopposed estrogen poses. (Tenakawa et al, 1997).

In relation to histologic types the dualistic model is now widely accepted. It is divided into two types- Type 1 and Type 2 according to the Bokhman model. This model is based on the endocrine and metabolic factors.

Type 1 develops when there is a state of hyperestrogenism. This is the most common type 85% and occurs in states such as obesity, anovulation, late menopause and hyperplasia. It has the best prognosis due to moderate differentiation and minimal invasion.

Type 2 develops in atrophy with poor differentiation with a tendency of invading the myometrium and has an increased frequency of metastatic spread. (Bokhan JV, 1983.)

(B Long, FW Liu, 2013) in their study found that at every stage of presentation usually have worse clinical presentation than their white counterparts. This is true in our set up as advanced disease was the most common presentation likely due to both socio economic status and health seeking behaviour amongst our population.

Chronic Endometritis

In our study we found that chronic endometritis accounted for 8 % of the study population. Chronic endometritis is defined as persistent inflammation of the endometrial lining. In premenopausal women it is often associated with Recurrent implantation failure. (Erika B. Johnston- MacAnanny et al 2009). Most other studies have shown that it's a very rare occurrence and our study differs greatly. It is postulated that maybe the cause might be TB endometritis is lieu of the prevalence of Tuberculosis and the immune status of some of our patients. (K. Gungorduk et al 2007) say that it accounted for approximately 1% of the cases occurring of post menopausal bleeding in there study done in Istanbul. Closer home a study done in Nigeria by(Ojo et al, 2008) found the incidence to be only 3 patients out of a possible 661 women and of significance they were pre menopausal women who had presented as cases of secondary infertility.

CHAPTER SIX

6.0 CONCLUSIONS AND RECOMMENDATION

6.1: Conclusions

This chapter covers the conclusions drawn from the study and the recommendations thought appropriate as a result.

1. The mean age of onset of menopause from our participants was 54.6 years
2. The mean age of onset of bleeding post menopause was 4.6 years with a range of 1-15 years.
3. Increase in endometrial thickness is associated with an increase risk for malignancy however it does not definitively rule it in or out.
4. Chronic endometritis is a significant finding in our set up.
5. Endometrioid Adenocarcinoma is the most common histopathologic subtype amongs malignant patients in our study.

6.2 Recommendations:

There is a significant number of patients with chronic endometritis and further studies to elucidate the cause should be undertaken.

An atrophic or normal endometrium in the setting of clinical symptoms does not rule out malignancy and a high index of suspicion when scanning elderly patients should be employed.

REFERENCES

- Astrup, K., & Olivarius, N. D. F. (2004). Frequency of spontaneously occurring postmenopausal bleeding in the general population. *Acta obstetricia et gynecologica Scandinavica*, 83(2), 203-207.
- Aziz, H., Rotman, M., Hussain, F., Smith, G., Chan, E., Choi, K., ... & Fruchter, R. (1993). Poor survival of black patients in carcinoma of the endometrium. *International Journal of Radiation Oncology* Biology* Physics*, 27(2), 293-301.
- Bakour, S., Dwarakanath, L., Khan, K., Newton, J., & Gupta, J. (1999). The diagnostic accuracy of ultrasound scan in predicting endometrial hyperplasia and cancer in postmenopausal bleeding. *Acta obstetricia et gynecologica Scandinavica*, 78(5), 447-451.
- Bokhman, J. V. (1983). Two pathogenetic types of endometrial carcinoma. *Gynecologic oncology*, 15(1), 10-17.
- Bulun, S. E. (2013). Uterine fibroids. *New England Journal of Medicine*, 369(14), 1344-1355.
- Cecchini, S., Ciatto, S., Bonardi, R., Grazzini, G., & Mazzotta, A. (1996). Endometrial ultrasonography-An alternative to invasive assessment in women with postmenopausal vaginal bleeding. *Tumori Journal*, 82(1), 38-39.
- Clark, T. J., Voit, D., Gupta, J. K., Hyde, C., Song, F., & Khan, K. S. (2002). Accuracy of hysteroscopy in the diagnosis of endometrial cancer and hyperplasia: a systematic quantitative review. *Jama*, 288(13), 1610-1621.
- Coleman, B. G., Arger, P. H., Grumbach, K., Menard, M. K., Mintz, M. C., Allen, K. S., ... & Lamon, K. A. (1988). Transvaginal and transabdominal sonography: prospective comparison. *Radiology*, 168(3), 639-643.
- Ćurčić, A., Đurđević, S., Mihaldžić-Tubić, S., Mladenović-Segedi, L., & Maksimović, M. (2009). Ultrasound detection of endometrial fluid in postmenopausal women. *Medicinski pregled*, 62(7-8), 337-341.
- Dørum, A., Kristensen, G. B., Langebrekke, A., Sørnes, T., & Skaar, O. (1993). Evaluation of endometrial thickness measured by endovaginal ultrasound in women with postmenopausal bleeding. *Acta obstetricia et gynecologica Scandinavica*, 72(2), 116-119.
- Dubinsky TJ, Stroehlein K, Abu-Ghazzer, Y. Pawey HR, Maklad N. (1999) Prediction of benign and malignant endometrial disease. Hysterosonographic- pathologic Correlation. *Radiology*.: 210;: 393-7.

- Ferrazzi, E., Torri, V., Trio, D., Zannoni, E., Filiberto, S., & Dordoni, D. (1996). Sonographic endometrial thickness: a useful test to predict atrophy in patients with postmenopausal bleeding. An Italian multicenter study. *Ultrasound in Obstetrics and Gynecology: The Official Journal of the International Society of Ultrasound in Obstetrics and Gynecology*, 7(5), 315-321.
- Fleischer, A. C., Dudley, B. S., Entman, S. S., Baxter, J. W., Kalemeris, G. C., & James Jr, A. E. (1987). Myometrial invasion by endometrial carcinoma: sonographic assessment. *Radiology*, 162(2), 307-310
- Fleischer, A. C., Kalemeris, G. C., & Entman, S. S. (1986). Sonographic depiction of the endometrium during normal cycles. *Ultrasound in medicine & biology*, 12(4), 271-277
- Giusa-Chiferi, M. G., Goncalves, W. J., Baracat, E. G., de Albuquerque Neto, L. C., Bortoletto, C. C. R., & de Lima, G. R. (1996). Transvaginal ultrasound, uterine biopsy and hysteroscopy for postmenopausal bleeding. *International Journal of Gynecology & Obstetrics*, 55(1), 39-44.
- Goldstein, S. R., Nachtigall, M., Snyder, J. R., & Nachtigall, L. (1990). Endometrial assessment by vaginal ultrasonography before endometrial sampling in patients with postmenopausal bleeding. *American journal of obstetrics and gynecology*, 163(1), 119-123
- Gompel, C., & Silverberg, S. (1985). *Pathology in gynecology and obstetrics*. Philadelphia, Pa: Lippincott.
- Gonzalez-Bosquet, E., Resident, J., Martinez-Palones, J. M., Gonzalez-Bosquet, J., & Jimenez, A. (1997). Uterine Sarcoma: A Clinicopathological Study Of 93 Cases. *European journal of gynaecological oncology*, 18(3), 192-195.
- Gungorduk, K., Ascioglu, O., Ertas, I. E., Ozdemir, I. A., Ulker, M. M., Yildirim, G., ... & Sancı, M. (2014). Comparison of the histopathological diagnoses of preoperative dilatation and curettage and Pipelle *biopsy European Journal of Gynaecological Oncology* 35(5), 539-543.
- Johnston-MacAnanny, E. B., Hartnett, J., Engmann, L. L., Nulsen, J. C., Sanders, M. M., & Benadiva, C. A. (2010). Chronic endometritis is a frequent finding in women with recurrent implantation failure after in vitro fertilization. *Fertility and sterility*, 93(2), 437-441.
- Jones, K., & Bourne, T. (2001). The feasibility of a 'one stop' ultrasound-based clinic for the diagnosis and management of abnormal uterine bleeding. *Ultrasound in obstetrics & gynecology*, 17(6), 517-52.
- Long, B., Liu, F. W., & Bristow, R. E. (2013). Disparities in uterine cancer epidemiology, treatment, and survival among African Americans in the United States. *Gynecologic oncology*, 130(3), 652-659.

- Montgomery, B. E., Daum, G. S., & Dunton, C. J. (2004). Endometrial hyperplasia: a review. *Obstetrical & gynecological survey*, 59(5), 368-378.
- Moodley, M., & Roberts, C. (2004). Clinical pathway for the evaluation of postmenopausal bleeding with an emphasis on endometrial cancer detection. *Journal of Obstetrics and Gynaecology*, 24(7), 736-741.
- Munir, S., Amin, D., Sultana, M., & Saeed, T. A. R. I. Q. (2010). Ovulation induction using laparoscopic ovarian drilling in women with polycystic ovarian syndrome: predictors of success. *Biomedica*, 26(2), 130-134
- Nasri, M. N., & Coast, G. J. (1989). Correlation of ultrasound findings and endometrial histopathology in postmenopausal women. *BJOG: An International Journal of Obstetrics & Gynaecology*, 96(11), 1333-1338
- Nkyekyer, K. (2000). Pattern of gynaecological cancers in Ghana. *East African medical journal*, 77(10).
- O'Connell, L. P., Fries, M. H., Zeringue, E., & Brehm, W. (1998). Triage of abnormal postmenopausal bleeding: a comparison of endometrial biopsy and transvaginal sonohysterography versus fractional curettage with hysteroscopy. *American journal of obstetrics and gynecology*, 178(5), 956-961.
- Ong, S., Duffy, T., & Murphy, J. (1996). Transabdominal ultrasound and its correlation with clinical findings in gynaecology. *Iranian Journal of Medical science*, 165 (4), 268-270
- Phillip, H., Dacosta, V., Fletcher, H., Kulkarni, S., & Reid, M. (2004). Correlation between transvaginal ultrasound measured endometrial thickness and histopathological findings in Afro-Caribbean Jamaican women with postmenopausal bleeding. *Journal of Obstetrics and Gynaecology*, 24(5), 568-572.
- Schem, C., Bauerschlag, D., Meinhold-Heerlein, I., Fischer, D., Friedrich, M., & Maass, N. (2007). Benigne und borderline-tumoren des ovars. *Therapeutische Umschau*, 64(7), 369-374.
- Smith-Bindman, R., Kerlikowske, K., Feldstein, V. A., Subak, L., Scheidler, J., Segal, M., ... & Grady, D. (1998). Endovaginal ultrasound to exclude endometrial cancer and other endometrial abnormalities. *Jama*, 280(17), 1510-1517.
- Sur, D., & Chakravorty, R. (2016). Correlation of Endometrial Thickness and Histopathology in women with Abnormal Uterine Bleeding. *Reproductive System and Sexual Disorder*, 5(4), 1-3.
- Trimble, C. L., Kauderer, J., Zaino, R., Silverberg, S., Lim, P. C., Burke, J. J., ... & Curtin, J. (2006). Concurrent endometrial carcinoma in women with a biopsy diagnosis of atypical endometrial hyperplasia: a Gynecologic Oncology Group study. *Cancer*, 106(4), 812-819.

- Ugwu, E. O., Iferikigwe, E. S., Okeke, T. C., Ugwu, A. O., Okezie, O. A., & Agu, P. U. (2011). Pattern of gynaecological cancers in University of Nigeria Teaching Hospital, Enugu, south eastern Nigeria. *Nigerian journal of medicine: journal of the National Association of Resident Doctors of Nigeria*, 20(2), 266-269.
- Ugwu, E. O., Iferikigwe, E. S., Okeke, T. C., Ugwu, A. O., Okezie, O. A., & Agu, P. U. (2011). Pattern of gynaecological cancers in University of Nigeria Teaching Hospital, Enugu, south eastern Nigeria. *Nigerian journal of medicine: journal of the National Association of Resident Doctors of Nigeria*, 20(2), 266-269.
- Van den Bosch, T., Ameye, L., Van Schoubroeck, D., Bourne, T., & Timmerman, D. (2012). OP20. 07: The diagnosis of focal uterine intracavitary lesions and endometrial cancer in women with abnormal uterine bleeding. *Ultrasound in Obstetrics & Gynecology*, 40(S1), 115-115.
- Van den Bosch, T., Ameye, L., Van Schoubroeck, D., Bourne, T., & Timmerman, D. (2015). Intra-cavitary uterine pathology in women with abnormal uterine bleeding: a prospective study of 1220 women. *Facts, views & vision in Obstetrics & Gynecology*, 7(1), 17.
- Weissman, A. M., & Barloon, T. J. (1996). Transvaginal ultrasonography in nonpregnant and postmenopausal women. *American family physician*, 53(6), 2065-2072.

APPENDICES

Appendix I: Consent Form

English Version

Investigator: My name is Dr. Allan Ayiro. I am a qualified doctor, registered with the Kenya Medical Practitioners and Dentists Board. I am currently pursuing a Masters degree in Radiology and Imaging at Moi University. I would like to recruit you into my research which is to study the Ultrasound findings in post menopausal patients with abnormal uterine bleeding presenting at Moi Teaching and Referral hospital.

Purpose: This study will seek to determine the sonographic findings among patients presenting with abnormal uterine bleeding after menopause.

Procedure: All patient with abnormal post menopausal uterine bleeding -referred for ultrasound scanning and for whom consent has been given will undergo US evaluation. Demographic data will be obtained and the patients subjected to a physical examination. Both the clinical and radiologic data will be collected on data collection forms. Data collecting material will be kept in a locked cabinet during the study period

Benefits: There will be no direct benefits of participating in this study. Study subjects will be accorded same quality of management as non-study subjects

Risks: There are no anticipated risks to the participants attributable to this study.

Confidentiality: All information obtained in this study will be treated with utmost confidentiality and shall not be divulged to any unauthorized person

Rights to Refuse: Participation in this study is voluntary, there is freedom to refuse to take part or withdraw at any time. This study has been approved by the Institutional Research and Ethics Committee (IREC) of Moi University/Moi Teaching and Referral Hospital

Sign or make a mark if you agree to take part in the study

Parent/Guardian:..... Investigator:Date:.....

Kiswahili version

Mimi ni Daktari Allan Ayiro. Nimehitimu na kusajiliwa na bodi ya madaktari mchini Kenya.(Kenya Medical Practitioners and Dentists Board) kama daktari .

Mimi ni mwanafunzi wa shahada ya juu.Natarajia kufanya utafiti wa kulinganisha picha ya kipelelezo cha Ultrasound na Majibu ya Maabara kutokana na mapendekezo baada ya picha ili kuona na kudhibitisha ukweli wa tashwishi tunayoepana kama wapiga picha tukilinganisha na majibu ya maabara.

Wagonjwa amabao watakuja kutibiwa kwa shida hii ya kuvuja damu watasajiliwa ikiwa watapeana hiari yao.

Hakutakuwepo na manufaa yoyote zaidi na yale ya kwaida kwa wale watakao kubali kusajiliwa katika utafiti huu. Majibu ya upelelezi huu yatawekwa katika hospitali na hakuna yeyote Yule isipokuwa mgonjwa ambaye atapewa majibu haya.

Kila mgonjwa ako na haki ya kukataa kujumuishwa katika utafiti huu na bado atapokea matibabu bila ubaguzi.

Utafiti huu umeidhinishwa na kitengo that upelelezi cha hospitali ya MTRH.

Jina la Mgonjwa /Mzazi..... Sahihi..... Tarehe :.....

Jina la Mpelelezi..... Sahihi..... Tarehe :.....

Appendix II: Data Collection form

Name: _____

Age: _____

County of origin _____

Years post menopause : _____

Duration of abnormal uterine bleeding

Ultrasound findings

ml _____

Others _____

Appendix III: CAP Protocol 2017**ENDOMETRIUM:**

Select a single response unless otherwise indicated.

Procedure (select all that apply) (Note A)

- Total hysterectomy and bilateral salpingo-oophorectomy
- Radical hysterectomy
- Simple hysterectomy
- Supracervical hysterectomy
- Bilateral salpingo-oophorectomy
- Right salpingo-oophorectomy
- Left salpingo-oophorectomy
- Salpingo-oophorectomy, side not specified
- Right oophorectomy
- Left oophorectomy
- Oophorectomy, side not specified
- Bilateral salpingectomy
- Right salpingectomy
- Left salpingectomy
- Salpingectomy, side not specified
- Vaginal cuff resection
- Omentectomy
- Peritoneal biopsies
- Peritoneal washing
- Other (specify): _____

Note: For information about lymph node sampling, please refer to the Regional Lymph Node section.

+ Hysterectomy Type

- + Abdominal
- + Vaginal
- + Vaginal, laparoscopic-assisted
- + Laparoscopic

- + Laparoscopic, robotic-assisted
- + Other (specify): _____
- + Not specified
- + Specimen Integrity (Note A)
- + Intact
- + Opened
- + Morcellated
- + Other (specify): _____
- + Tumor Site (select all that apply)
- + Endometrium
- + Lower uterine segment
- + Endometrial polyp
- + Other (specify): _____
- + Cannot be determined
- + Tumor Size
- + Greatest dimension: cm
- + Additional dimensions: x cm
- + Cannot be determined (explain): _____
- Histologic Type (Note B)
- Endometrioid carcinoma, NOS
- Endometrioid carcinoma with squamous differentiation
- Endometrioid carcinoma, villoglandular variant
- Endometrioid carcinoma with secretory differentiation
- Endometrioid carcinoma, other variant (specify): _____
- Serous endometrial intraepithelial carcinoma
- Serous carcinoma
- Carcinosarcoma (malignant mixed Müllerian tumor)
- Mucinous carcinoma
- Clear cell carcinoma
- Small cell neuroendocrine carcinoma
- Large cell neuroendocrine carcinoma

___ Mixed cell carcinoma (specify types and percentages):

___ Undifferentiated carcinoma

___ Dedifferentiated carcinoma

___ Other histologic type not listed (specify): _____

Histologic Grade (required only if applicable) (Note C)[#]

___ FIGO grade 1

___ FIGO grade 2

___ FIGO grade 3

___ Other (specify): _____

___ Cannot be assessed (explain): _____

International Federation of Gynecology and Obstetrics (FIGO) Grading System applies to endometrioid and mucinous carcinomas only. Serous, clear cell, transitional, small cell and large cell neuroendocrine carcinomas, undifferentiated/ dedifferentiated carcinomas, and carcinosarcomas are generally considered to be high grade and it is not recommended to assign a histologic grade to these tumor types.

Myometrial Invasion (Note D)

___ Not identified

___ Present

Depth of invasion (millimeters): ___ mm

Myometrial thickness (millimeters): ___ mm

Percentage of myometrial invasion: ___%

OR, if exact percentage of invasion cannot be determined, state:

___ Depth of myometrial invasion cannot be determined (explain):

___ Myometrial thickness cannot be determined (explain): _____

Percentage depth of myometrial invasion Estimated less than 50% myometrial invasion Estimated greater than or equal to 50% myometrial invasion Cannot be determined (explain): _____**+ Adenomyosis** Not identified Present, uninvolved by carcinoma Present, involved by carcinoma Cannot be determined**Uterine Serosa Involvement** Not identified Present Cannot be determined (explain): _____**+ Lower Uterine Segment Involvement (Note E)** Not identified Present Superficial (non-myoinvasive) Myoinvasive Cannot be determined (explain): _____**Cervical Stromal Involvement (Note F)** Not identified Present Cannot be determined (explain): _____

6 Other Tissue/Organ Involvement (select all that apply)

Note: Any organ not selected is either not involved or was not submitted.

Not applicable

Not identified

Right ovary

Left ovary

Ovary (side not specified)

Right fallopian tube

Left fallopian tube

Fallopian tube (side not specified)

Vagina

Right parametrium

Left parametrium

Parametrium (side not specified)

Pelvic wall

Bladder wall

Bladder mucosa

Rectal wall

Bowel mucosa

Omentum

Other organs/tissue (specify): _____

Cannot be determined (explain): _____

+ Peritoneal/ Ascitic Fluid (Note G)

+ Not submitted/unknown

+ Negative for malignancy (normal/benign)

+ Atypical and/or suspicious (explain): _____

+ Malignant (positive for malignancy)

+ Unsatisfactory/nondiagnostic (explain): _____

+ Results pending

Margins (required only if cervix and/or parametrium/paracervix is involved by carcinoma) (Note H)

Ectocervical/Vaginal Cuff Margin

___ Cannot be assessed (explain): _____

___ Involved by carcinoma

___ Uninvolved by carcinoma

+ Distance of invasive carcinoma from margin (centimeters): ___ cm

Parametrial/Paracervical Margin

___ Cannot be assessed (explain): _____

___ Involved by carcinoma

___ Uninvolved by carcinoma

+ Distance of invasive carcinoma from margin (centimeters): ___ cm

Lymphovascular Invasion (Note I)

___ Not identified

___ Present

___ Cannot be determined

Regional Lymph Nodes

Note: Lymph nodes designated as pelvic, parametrial, obturator, internal iliac (hypogastric), external iliac, common iliac, sacral, presacral and para-aortic are considered regional lymph nodes. Any other involved nodes should be categorized as metastases (pM1) and commented on in the distant metastasis section. Presence of isolated tumor cells no greater than 0.2 mm in regional lymph node(s) is considered N0 (i+).

___ No lymph nodes submitted or found

Lymph Node Examination (required only if lymph nodes are present in the specimen)

Pelvic Lymph Nodes

Note: Includes parametrial, obturator, internal iliac (hypogastric), external iliac, common iliac, sacral and presacral nodes.

___ No pelvic nodes submitted or found

Pelvic Node Examination (required only if pelvic nodes are present)

Number of Pelvic Nodes with Macrometastasis (greater than 2 mm): _____

___ Number cannot be determined (explain): _____

Number of Pelvic Nodes with Micrometastasis (greater than 0.2 mm and up to 2 mm):

___ Number cannot be determined (explain): _____

Number of Pelvic Nodes with Isolated Tumor Cells (0.2 mm or less)[#]: _____

___ Number cannot be determined (explain): _____

[#] Reporting the number of lymph nodes with isolated tumor cells is required only in the absence of macrometastasis or micrometastasis in other lymph nodes.

Laterality of Pelvic Node(s) with Tumor (if applicable): _____

Total Number of Pelvic Nodes Examined (sentinel and non-sentinel): _____

___ Number cannot be determined (explain): _____

Number of Pelvic Sentinel Nodes Examined: _____

___ Number cannot be determined (explain): _____

Laterality of Pelvic Node(s) Examined: _____

Para-aortic Lymph Nodes

___ No para-aortic nodes submitted or found

Para-aortic Node Examination (required only if para-aortic nodes are present)

Number of Para-aortic Nodes with Macrometastasis (greater than 2 mm): _____

___ Number cannot be determined (explain): _____

Number of Para-aortic Nodes with Micrometastasis (greater than 0.2 mm and up to 2 mm):

___ Number cannot be determined (explain): _____

Number of Para-aortic Nodes with Isolated Tumor Cells (0.2 mm or less) (if applicable)[#]:

___ Number cannot be determined (explain): _____

[#] Reporting the number of lymph nodes with isolated tumor cells is required only in the absence of macrometastasis or micrometastasis in other lymph nodes.

Laterality of Para-aortic Node(s) with Tumor (if applicable): _____

Total Number of Para-aortic Nodes Examined (sentinel and non-sentinel): _____

___ Number cannot be determined (explain): _____

Number of Para-aortic Sentinel Nodes Examined: _____

___ Number cannot be determined (explain): _____

Laterality of Para-aortic Node(s) Examined: _____

Pathologic Stage Classification (pTNM, AJCC 8th Edition) (Note J)

Note: Reporting of pT, pN, and (when applicable) pM categories is based on information available to the pathologist at the time the report is issued. Only the applicable T, N, or M category is required for reporting; their definitions need not be included in the report. The categories (with modifiers when applicable) can be listed on 1 line or more than 1 line.

TNM Descriptors (required only if applicable) (select all that apply)

___ r (recurrent)

___ y (posttreatment)

Primary Tumor (pT)

___ pTX: Primary tumor cannot be assessed

___ pT0: No evidence of primary tumor

___ pT1: Tumor confined to the corpus uteri, including endocervical glandular involvement

___ pT1a: Tumor limited to endometrium or invading less than half of the myometrium

___ pT1b: Tumor invading one-half or more of the myometrium

___ pT2: Tumor invading the stromal connective tissue of the cervix but not extending beyond the uterus. This does NOT include endocervical glandular involvement

___ pT3: Tumor involving serosa, adnexa, vagina, or parametrium

___ pT3a: Tumor involves serosa and/or adnexa (direct extension or metastasis)

___ pT3b: Vaginal involvement (direct extension or metastasis) or parametrial involvement

___ pT4: Tumor invading the bladder mucosa and/or bowel mucosa (bullous edema is not sufficient to classify a tumor as T4)

Regional Lymph Nodes (pN) (select all that apply)

Modifier

___ (sn)[#]

[#] *Note: Suffix (sn) is required if applicable and added to the N category when only sentinel lymph node biopsy is performed. If after a sentinel node biopsy, the patient then undergoes a complete lymph node dissection, the (sn) suffix is not used.*

Category (pN)

___ pNX: Regional lymph nodes cannot be assessed

___ pN0: No regional lymph node metastasis

___ pN0(i+): Isolated tumor cells in regional lymph node(s) no greater than 0.2 mm

___ pN1: Regional lymph node metastasis to pelvic lymph nodes

___ pN1mi: Regional lymph node metastasis (greater than 0.2 mm but not greater than 2 mm in diameter) to pelvic lymph nodes[#]

___ pN1a Regional lymph node metastasis (greater than 2 mm in diameter) to pelvic lymph nodes

___ pN2: Regional lymph node metastasis to para-aortic lymph nodes, with or without positive pelvic lymph nodes

___ pN2mi: Regional lymph node metastasis (greater than 0.2 mm but not greater than 2 mm in diameter) to para-aortic lymph nodes, with or without positive pelvic lymph nodes[#]

___ pN2a: Regional lymph node metastasis (greater than 2 mm in diameter) to para-aortic lymph nodes, with or without positive pelvic lymph nodes

[#] *Note: Even one metastasis >2.0 mm would qualify the classification as pN1a and pN2a.*

Distant Metastasis (pM) (required only if confirmed pathologically in this case)

___ pM1: Distant metastasis (includes metastasis to inguinal lymph nodes, intraperitoneal disease, lung, liver, or bone. It excludes metastasis to pelvic or para-aortic lymph nodes, vagina, uterine serosa, or adnexa)

Specify site(s), if known: _____

+ FIGO Stage (2015 FIGO Cancer Report)

- + ___ I: Tumor confined to the corpus uteri
- + ___ IA: No or less than half myometrial invasion
- + ___ IB: Invasion equal to or more than half of the myometrium
- + ___ II: Tumor invades cervical stroma, but does not extend beyond the uterus
- + ___ III: Local and/or regional spread of the tumor
- + ___ IIIA: Tumor invades the serosa of the corpus uteri and/or adnexae
- + ___ IIIB: Vaginal involvement and/ or parametrial involvement
- + ___ IIIC: Metastases to pelvic and/or para-aortic lymph nodes
- + ___ IIIC1: Positive pelvic nodes
- + ___ IIIC2: Positive para-aortic nodes with or without positive pelvic lymph nodes
- + ___ IV: Tumor invades bladder and/or bowel mucosa, and/or distant metastases
- + ___ IVA: Tumor invasion of bladder and/or bowel mucosa
- + ___ IVB: Distant metastasis, including intraabdominal metastases and/or inguinal nodes
- + Additional Pathologic Findings (select all that apply) (Note K)
- + ___ None identified
- + ___ Atypical hyperplasia/endometrial intraepithelial neoplasia (EIN)
- + ___ Other (specify): _____
- + Ancillary Studies

Note: For reporting molecular testing, immunohistochemistry, and other cancer biomarker testing results, the CAP endometrium biomarker template should be used. Pending biomarker studies should be listed in the Comments section of this report.

+ Clinical History (select all that apply) (Note L)

+ ___ Lynch syndrome

+ ___ Other (specify): _____

+ Comment(s)

Appendix V: Estimated Project Budget




The estimated budget for this project is as illustrated below. The financial resources required to fund this research project shall be the researcher's own.

ITEM	QUANTITY	UNIT PRICE(ksh)	TOTAL(Ksh)
Laptop computer	1	70,000	70,000
Printer and photocopier	1	10000	10000
Stationary	-	6000	6000
Digital camera	1	15000	15000
CDs(CT Images storage)	60	20	1200
Statistical consultation	-	-	15000
Internet services and communication	-	-	10000
Publication	-	-	50000
Miscellaneous	-	-	17720
GRAND TOTAL	-	-	194920

Appendix VI: Time Schedule

ACTIVITY	START	COMPLETE
Proposal concept Development	OCTOBER 2015	JANUARY 2016
Proposal Writing	JANUARY 2016	MARCH 2016
IREC Approval	JUNE 2016	JULY 2017
Research	JULY 2017	8 JUNE 2018
Data Analysis	JUNE 2018	AUGUST 2018
Thesis Writing	AUGUST 2018	NOVEMBER 2018

Appendix VII: IREC Approval

 <p>MOI TEACHING AND REFERRAL HOSPITAL P.O. BOX 3 ELDORET Tel: 334711/2/3</p>	 <p>INSTITUTIONAL RESEARCH AND ETHICS COMMITTEE (IREC)</p>	<p>MOI UNIVERSITY COLLEGE OF HEALTH SCIENCES P.O. BOX 4606 ELDORET</p>												
<p>Reference: IREC/2016/136 Approval Number: 0001919</p> <p>Dr. Allan Shivogo Ayiro, Moi University, School of Medicine, P.O. Box 4606-30100, ELDORET-KENYA.</p> <p>Dear Dr. Ayiro,</p> <p>RE: FORMAL APPROVAL</p> <p>The Institutional Research and Ethics Committee has reviewed your research proposal titled:-</p> <p><i>"Transabdominal Pelvic Ultrasound Findings and Histopathological Correlation in Post Menopausal Patients Presenting with Abnormal Uterine Bleeding at Moi Teaching and Referral Hospital"</i></p> <p>Your proposal has been granted a Formal Approval Number; FAN: IREC 1919 on 12th July, 2017. You are therefore permitted to begin your investigations.</p> <p>Note that this approval is for 1 year; it will thus expire on 11th July, 2018. If it is necessary to continue with this research beyond the expiry date, a request for continuation should be made in writing to IREC Secretariat two months prior to the expiry date.</p> <p>You are required to submit progress report(s) regularly as dictated by your proposal. Furthermore, you must notify the Committee of any proposal change (s) or amendment (s), serious or unexpected outcomes related to the conduct of the study, or study termination for any reason. The Committee expects to receive a final report at the end of the study.</p> <p>Sincerely,</p> <p style="text-align: center;"></p> <p>PROF. E. WERE CHAIRMAN INSTITUTIONAL RESEARCH AND ETHICS COMMITTEE</p>	<p>12th July, 2017</p> <div style="border: 2px solid blue; padding: 5px; width: fit-content; margin: 10px auto;"> <p style="text-align: center; margin: 0;">INSTITUTIONAL RESEARCH & ETHICS COMMITTEE</p> <p style="text-align: center; margin: 0; color: red; font-size: 1.2em;">12 JUL 2017</p> <p style="text-align: center; margin: 0; font-weight: bold;">APPROVED</p> <p style="text-align: center; margin: 0; font-size: 0.8em;">P. O. Box 4606-30100 ELDORET</p> </div>													
<table border="0" style="width: 100%; border-collapse: collapse;"> <tr> <td style="width: 33%;">cc</td> <td style="width: 33%;">CEO - MTRH</td> <td style="width: 33%;">Dean - SOP</td> </tr> <tr> <td></td> <td>Principal - CHS</td> <td>Dean - SON</td> </tr> <tr> <td></td> <td></td> <td>Dean - SOM</td> </tr> <tr> <td></td> <td></td> <td>Dean - SOD</td> </tr> </table>			cc	CEO - MTRH	Dean - SOP		Principal - CHS	Dean - SON			Dean - SOM			Dean - SOD
cc	CEO - MTRH	Dean - SOP												
	Principal - CHS	Dean - SON												
		Dean - SOM												
		Dean - SOD												

Appendix VI: MTRH Approval



MOI TEACHING AND REFERRAL HOSPITAL

Telephone: 2033471/2/3/4
 Fax: 61749
 Email: ceo@mtrh.go.ke
Ref: ELD/MTRH/R&P/10/2/V.2/2010

P. O. Box 3
 ELDORET

14th July, 2017

Dr. Allan Shivogo Ayiro,
 Moi University,
 School of Medicine,
 P.O. Box 4606-30100,
ELDORET-KENYA.

APPROVAL TO CONDUCT RESEARCH AT MTRH

Upon obtaining approval from the Institutional Research and Ethics Committee (IREC) to conduct your research proposal titled:-

"Transabdominal Pelvic Ultrasound Findings and Histopathology Correlation in Post Menopausal Patients Presenting with Abnormal Uterine Bleeding at Moi Teaching and Referral Hospital".

You are hereby permitted to commence your investigation at Moi Teaching and Referral Hospital.

Wilson K. Aruasa
DR. WILSON K. ARUASA
CHIEF EXECUTIVE OFFICER
MOI TEACHING AND REFERRAL HOSPITAL

CC - Deputy Director (CS)
 - Director of Nursing Services (DNS)
 - HOD, HRISM