

**SONOGRAPHIC FINDINGS IN PATIENTS WITH LOWER  
LIMB SWELLING, SEEN AT MOI TEACHING AND  
REFERRAL HOSPITAL, ELDORET- KENYA.**

**BY**

**Dr. Ochako Agnes Kwamboka**

**A Research thesis submitted to School of Medicine in partial fulfillment  
of the requirements for the award of the Degree of Master of Medicine  
in Radiology and Imaging, of Moi University.**

**©2015**

**SONOGRAPHIC FINDINGS IN PATIENTS WITH LOWER LIMB SWELLING,  
SEEN AT MOI TEACHING AND REFERRAL HOSPITAL, ELDORET- KENYA.**

**INVESTIGATOR**

Dr. Ochako Agnes Kwamboka, MBChB (Moi), Registrar in Radiology and Imaging,

Moi University, School of Medicine

**SUPERVISORS**

Prof. G. D. Onditi Elias, MBChB (UON), M.Med (UON), Fellow in Imaging (USA),

FRP (IAEA), Associate professor of Radiology and Imaging,

Department of Radiology and Imaging, School of medicine

College of Health Sciences,

Moi University

Dr Joseph M. Abuya, MBChB (UON), M.Med (UON), Senior Lecturer

Department of Radiology and Imaging, School of medicine

College of Health Sciences

Moi University

## DECLARATION

### **Student Declaration**

This thesis is my original work and has not been presented for a degree in any other university to the best of my knowledge. No part of this thesis may be reproduced without prior written permission of the author and Moi University.

Dr. Ochako Agnes Kwamboka

Registration No.: SM/PGR/05/11

Registrar, Department of Radiology and Imaging,

Moi University, School of Medicine

Signature.....Date: .....

### **Supervisors' Declaration**

This thesis has been submitted for assessment on our approval as university appointed supervisors:

Prof. G. D. Onditi Elias

Associate Professor in Radiology,

Department of Radiology and Imaging,

Moi University, School of Medicine

Signature.....Date .....

Dr. Joseph. M. Abuya

Senior Lecturer,

Department of Radiology and Imaging

Moi University, School of Medicine

Signature.....Date .....

## **DEDICATION**

To my dear husband Nehemiah Onger, my children Nicole, Adrian, Jewel and my dear parents. You mean everything to me.

## ABSTRACT

**Title:** Sonographic findings in patients with lower limb swelling, seen at Moi Teaching and Referral Hospital, (MTRH),- Eldoret- Kenya.

**Background:** Lower limb swelling is a nonspecific clinical presentation of various pathologies that have significant impact in clinical outcomes. Due to this non-specific nature, identifying the specific diagnosis is crucial for proper management. Imaging modalities play a major role in this and Ultrasonography has been shown to have comparable outcome with other techniques like Venography, in venous disorder diagnosis and MRI in soft tissue imaging.

**Objective:** To describe the Sonographic findings of lower limb swelling among patients presenting at Radiology and Imaging department of MTRH.

**Research design and Methodology:** This was a cross sectional study done at the Moi Teaching and Referral Hospital, Radiology and Imaging Department. The study population was patients with lower limb swelling, presenting to the department for imaging. A sample size of 103 was reached using Fisher's formula. Consent was administered; the participant's history, physical examination and sonographic findings were recorded. Data was analyzed using STATA version 10. Descriptive statistics (mean, median and range) were used for continuous variables while frequency listings were used for categorical variables. Correlation was done for clinical findings and Sonographic findings and Chi square test was used to assess associations between these categorical variables.

**Results:** There were 103 participants. Their median age was 41 years and the majority were women 67 (65%). The main complaints were unilateral lower limb swelling 80 (77.7%), and pain in 54 (52.4%). Trauma and immobility were in 18 (17.5%) and 19 (18.4%) respectively. The main clinical examination findings were localized swelling in 63 (61.2%), the commonest location being in the lower leg 52 (50.5%). Redness was in 31 (30.1%) while tenderness was demonstrated in 41 (39.8%) cases. The most frequent Sonographic findings were deep venous thrombosis (DVT) 39 (37.9%). Lymphadenopathy and oedema were 9 (8.7%) each while varicose veins and cellulitis were 7 (6.8%) and 6 (5.8%) respectively. Arterial atherosclerosis and aneurysm, Baker's cyst, pyomyositis and soft tissue tumour were less frequent findings. There was no association between onographic finding and gender, age or occupation. However, there was association between DVT and immobility ( $p<0.001$ ), diffuse unilateral swelling ( $p=0.002$ ) and tenderness ( $p<0.001$ ).

**Conclusion and Recommendations:** DVT was the commonest sonographic pattern (37.9%). There was association between DVT and history of immobility ( $p<0.001$ ).

**LIST OF ABBREVIATIONS:**

CFA- Common Femoral Artery

CFV- Common Femoral Vein

CT- Computed Tomography

CVI – Chronic Venous Insufficiency

DVT- Deep Venous Thrombosis

IREC- Institutional Research and Ethics Committee

M.Med. - Master of Medicine

MRI- Magnetic Resonance and Imaging

MTRH- Moi Teaching and Referral Hospital

PAD- Peripheral Arterial Disease

PRF- Pulse Repetition Frequency

SFV- Superficial Femoral Vein

US- Ultrasound

## OPERATIONAL DEFINITION OF TERMS

**Augmentation** – An assessment of patency of veins whereby a distal compression followed by quick release results in temporary increase of flow in the veins towards the heart in a normal vein

**Lower limb** – Is the entire lower extremity of the human body, including the inguinal, thigh, popliteal, lower leg, ankle and foot. In this study, the inguinal region refers to the region 2cm above and below the inguinal ligament, popliteal region is 10 cm above and below the tibial tuberosity, lower leg is the region between 10cm below the tibial tuberosity, to the ankle region.

**Valsalva maneuver** – a forceful attempt at expiration when the airway is closed resulting in increased abdominal pressure and therefore increased venous pressures in the iliac and femoral veins used to assess the patency of the proximal deep veins and the sapheno-femoral junction.

**Aneurysm**- A localized widening (dilatation) of an artery or a vein. At the point of an aneurysm, there's typically a bulge. The wall of the blood vessel or organ is weakened and may rupture.

**Orthostasis**- Prolonged maintenance of an upright posture.

## TABLE OF CONTENTS

DECLARATION.....	iii
DEDICATION .....	iv
ABSTRACT .....	v
LIST OF ABBREVIATIONS:.....	vi
OPERATIONAL DEFINITION OF TERMS.....	vii
TABLE OF CONTENTS.....	viii
LIST OF TABLES .....	x
LIST OF FIGURES .....	xi
ACKNOWLEDGEMENTS .....	xii
CHAPTER ONE: INTRODUCTION .....	1
1.1 Background Information .....	1
CHAPTER TWO: LITERATURE REVIEW .....	5
2.1 Epidemiology of lower limb patterns .....	5
2.2 Sonographic and clinical presentations of lower limb swelling .....	7
2.3 Problem Statement .....	11
2.4 Research Question. ....	11
2.5 Justification.....	11
2.6 Objectives .....	12
2.6.1 Broad objective .....	12
2.6.2 Specific Objectives.....	12
CHAPTER THREE: METHODOLOGY .....	13
3.1 Setting .....	13
3.2 Study population.....	13
3.3 Study design: .....	13
3.4 Sample size .....	13
3.5 Inclusion and exclusion criteria .....	14
3.5.1 Inclusion criteria .....	14
3.5.2 Exclusion criteria .....	14
3.6 Sampling technique.....	15
3.7 Data collection protocol .....	15
3.8 Sonographic examination .....	16
3.8.1 Ultrasound equipment .....	16
3.8.2 Lower limb ultrasound examination procedure .....	16
3.9 Outcome measures .....	19
3.10 Quality control.....	19
3.11. Data management and analysis.....	19
3.12 Data dissemination.....	20



3.13 Ethical considerations .....	20
3.14 Study limitation .....	21
CHAPTER FOUR: RESULTS .....	22
4.1 Socio-demographic data:.....	22
4.2 Clinical history .....	23
4.3 Physical Examination.....	23
4.4 Sonographic findings .....	25
4.5 Sonographic findings by gender .....	26
4.6 Associations of sonographic findings with clinical presentation .....	30
4.7 Sample Sonographic images.....	32
CHAPTER FIVE: DISCUSSION, CONCLUSIONS, AND RECOMMENDATIONS ...	33
5.1 Discussion .....	33
5.2 Conclusions .....	38
5.3 Recommendations.....	38
REFERENCES.....	39
APPENDIX I.....	46
APPENDIX II: CONSENT FORM (ENGLISH VERSION) .....	49
APPENDIX III : CHETI CHA RUHUSA:.....	51
APPENDIX IV : CHART SHOWING FLOW OF PATIENTS .....	53
APPENDIX V: WORK PLAN .....	54
APPENDIX VI: BUDGET .....	55
APPENDIX VII: IREC APPROVAL LETTER .....	56
APPENDIX VIII: MTRH APPROVAL LETTER.....	57

## LIST OF TABLES

Table1: Demographic characteristics .....	22
Table 2: Summary of Sonographic findings per age categories and occupation .....	27
Table 3: Summary of clinical presentation by Sonographic findings. ....	29
Table 4: Cross tabulation of main Sonographic finding by key variable .....	30
Table 5. Clinical presentations of lower limbs patterns .....	31

## LIST OF FIGURES

Figure 1. Anatomy of venous system, the deep (A) and the superficial veins (B) .....	2
Figure 2: Arterial anatomy of the lower limb, anterior view (A) and posterior view (B) ...	3
Figure 3: A bar chart showing location of lower limb swelling .....	24
Figure 4: A bar chart showing Sonographic Findings .....	25
Figure 5: A bar chart showing Sonographic findings by gender.....	26
Figure 6. DVT in 37 year old male.....	32
Figure 7. Varicose veins, 58yr old female .....	32
Figure 8: Pyomyositis, 26 year old male with intramuscular mass. Aspirated pus.....	32

## ACKNOWLEDGEMENTS

I would like to express my sincere gratitude to my supervisors: Prof. G.D Onditi Elias and Dr. J. Abuya for their fruitful guidance and input towards the development of this thesis. The entire Department of Radiology and Imaging is highly appreciated with special thanks to Dr. Wanene and Dr. Kimutai for assistance in interpretation of Sonography examinations and providing expert advice. I am grateful to the staff in the ultrasound unit for their direct and indirect support during data collection period. I am also grateful to Dr. Mwangi for her input on statistical management.

Much gratitude goes to my immediate family: My husband Dr. Onger Angwenyi, daughters Nicole, Jewel and son Adrian, for their patience, perseverance and above all, their love and constant encouragement. Special thanks go to my dear parents Nelson Ochako Swanya, and Peninnah Gechemba for their support, encouragement, and prayers. I thank my sisters Mary Nyamoita, Nancy Moraa and brothers, Isaiah Dan, and Shidah Ondieki for constant support and encouragement.

Finally, gratitude goes to the Ministry of Medical Services for offering me the scholarship and the study leave to undertake this postgraduate work. I thank the Moi University and MTRH for their support in this study.

## CHAPTER ONE: INTRODUCTION

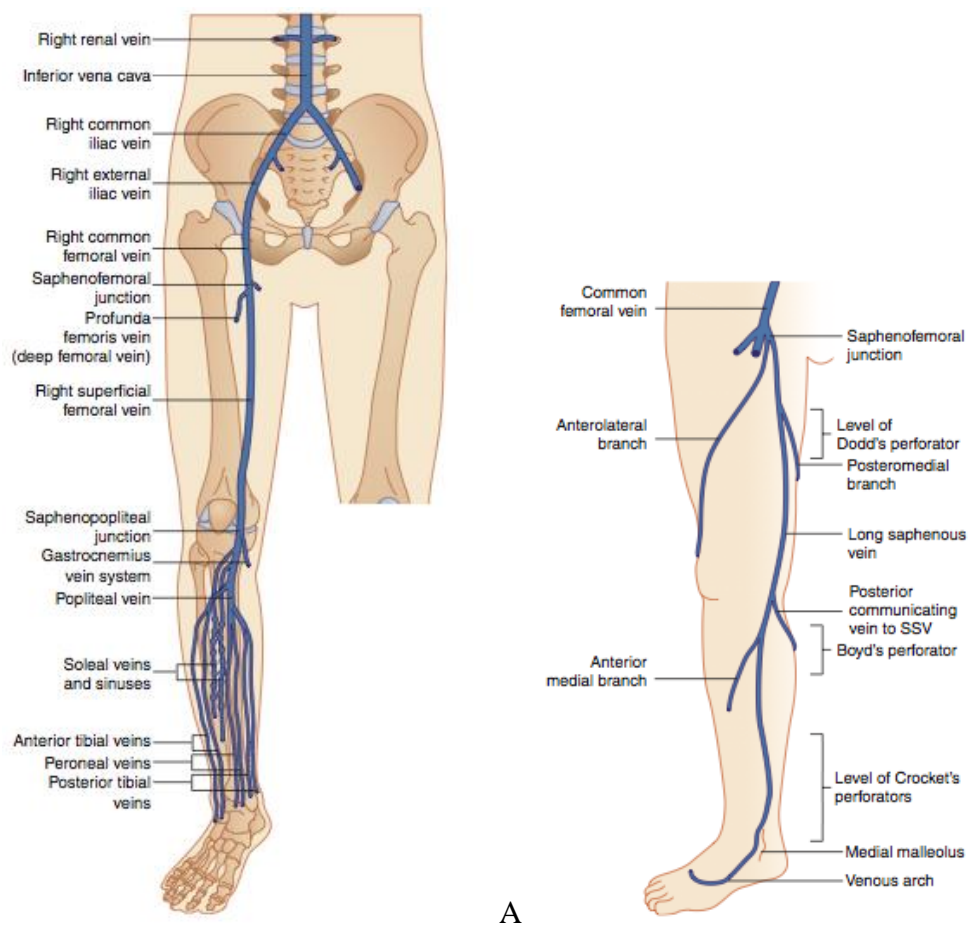
### 1.1 Background Information

Lower limb swelling is an expansion of all or part of the lower extremity due to increase in any tissue component (muscle, fat, blood etc.). It is therefore not a disease entity but a sign or symptom of many clinical conditions, systemic or non- systemic, requiring a correct diagnosis to be made for it to be managed adequately. Clinically, lower limb swelling may present as acute or chronic, unilateral or bilateral, localized or generalized and congenital or acquired. Bilateral lower limb swelling usually suggests a systemic or more central cause of oedema like cardiac failure, nephrotic syndrome among other causes. However, previous studies have demonstrated that regional causes like deep venous thrombosis may present with symmetric lower limb swelling, though less frequently.<sup>1,2</sup>

A number of studies have been documented that Doppler Sonography has comparable results to Venography and Arteriography, in diagnosis of various lower limb arterial and venous pathologies. In a study done by Aywak et al, they found that venous Sonography had a sensitivity of 88.9%, specificity of 91.8% and accuracy of 90.9% in comparison with an invasive, serious side effect laden contrast Venography, which is considered the gold-standard technique for DVT diagnosis<sup>3</sup>. Other venous pathologies diagnosed by US are chronic venous insufficiency (CVI) and thrombophlebitis<sup>4,5</sup>. Ultrasound use in detection of peripheral artery disease (PAD) has sensitivity and specificity of 88% and 95% above knee and 84% and 93% for below knee respectively in comparison with the gold standard Arteriography<sup>6</sup>. The normal peripheral arterial velocity waveform is triphasic with a forward flow systolic peak, then a reversal of flow in early diastole and a forward flow in

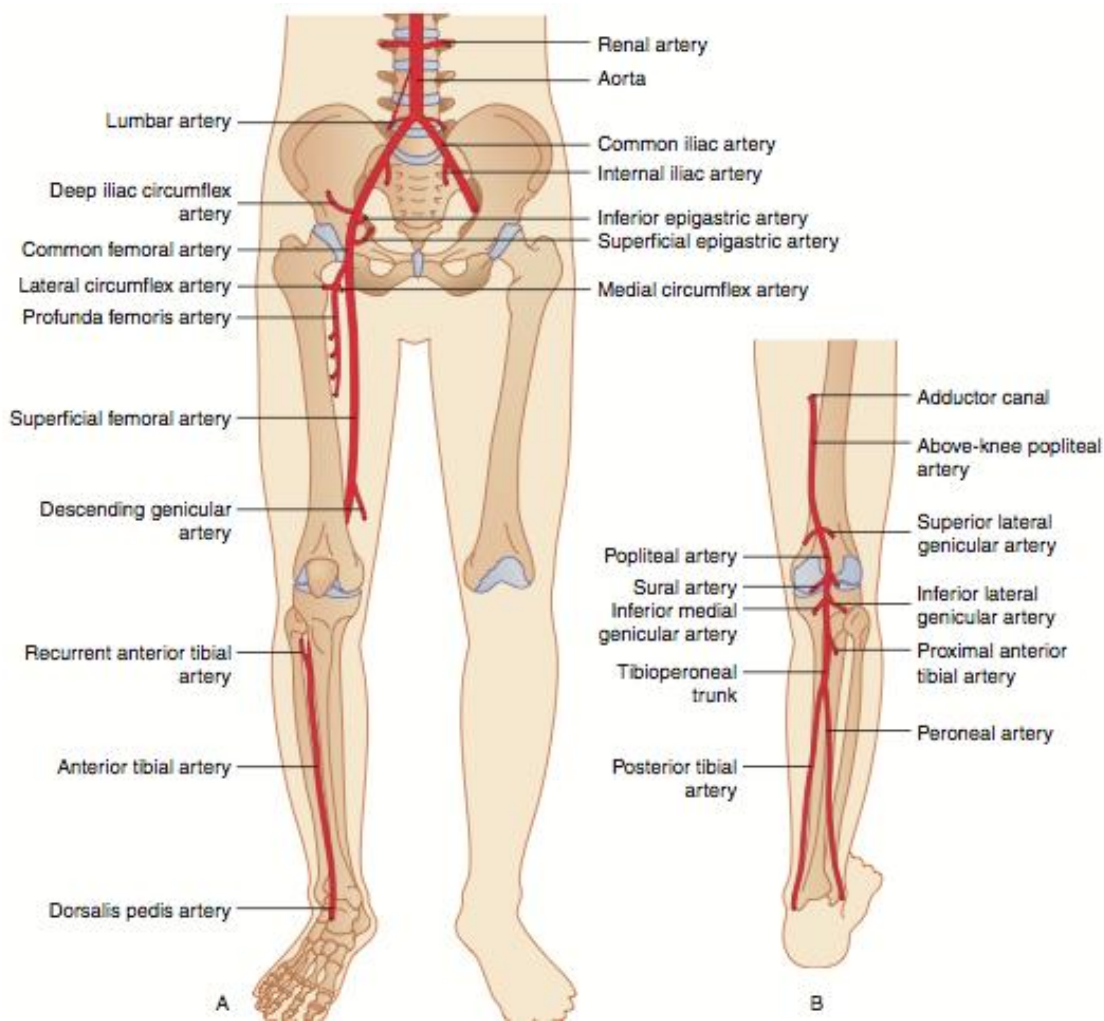
late diastole. With progressive PAD, the reverse flow is eliminated, the peak decreases and the flow in diastole increases<sup>6,7</sup>.

Knowledge of the anatomy of the venous and arterial system is paramount in diagnosis. The venous system of the lower limb is divided into the deep and superficial veins located in two main compartments. This anatomy is summarized in Figure 1.



**Figure 1. Anatomy of venous system, the deep (A) and the superficial veins (B)**

The lower limb arterial anatomy is summarized in figure 2.



**Figure 2: Arterial anatomy of the lower limb, anterior view (A) and posterior view (B)**

Other causes of lower limb swelling that are amenable to Sonography are lymphoedema (failure of lymphatic drainage system), cellulitis, Bakers cyst, pyomyositis/ abscesses and tumors/masses. Lymphoedema is usually unilateral with characteristic hardy swelling and difficulty impression<sup>8</sup>. It has three clinical stages: reversible swelling (stage 1), irreversible swelling (stage 2) and elephantiasis (stage 3). Confirmation of lymphoedema requires

lymphoscintigraphy, as Ultrasound use in its diagnosis is suboptimal<sup>9</sup>. Cellulitis on the other hand is an inflammatory condition of the skin and subcutaneous tissue, characterized by, swelling, erythema, warmth and pain. It is a relatively common medical emergency whose severity ranges from mild to severe. Cellulitis can progress to abscess formation and distinction between these two clinical entities is crucial to choose the appropriate therapy as cellulitis is treated with systemic antibiotics, while abscesses require incision and drainage, in addition to antibiotics. Sonography has been shown to be highly sensitive tool in diagnosis of these two entities and more so in distinction between the two<sup>10-12</sup>.

Baker's cysts also known as popliteal cysts are a common occurrence in children and adults<sup>13,14</sup>. They present as swelling in the popliteal fossa due to enlargement of the gastrocnemius-semimembranosus bursa which lies between these two muscles and on the medial side of the fossa slightly distal to the center crease in the back of the knee. Popliteal cysts are fairly uncommon, may not be found on physical examination and require imaging preferably Sonography, as it is comparable to MRI in sensitivity and specificity, to be identified<sup>14,15</sup>. Soft tissue tumors and pyomyositis commonly present with focal swelling<sup>16,17</sup>.



## CHAPTER TWO: LITERATURE REVIEW

### 2.1 Epidemiology of lower limb patterns

Deep venous thrombosis (DVT) is a common clinical problem that complicates many medical and surgical disorders<sup>18</sup>. It is a worldwide problem and affects one or two people per 1000 people in the general population with the incidence increasing from one in 10 000 people in the less than 40 years of age group, to 1 in 100 for those older than 60 years of age<sup>6</sup>. It has been shown to affect males more commonly<sup>19</sup>. A study by Bauersachs et al., found the prevalence to be 37% (658/1778) in men as compared to 24.3% (730/2998) in women<sup>20</sup>. Andreou et al, which surveyed outpatients, recorded similar findings in another study, where the prevalence in men was 14% and women 9.4% (n=1838) in the study<sup>21</sup>. However some studies have found it to be more in women like in the study in Eritrea, on DVT among intensive care unit, found the ratio of female to male of 0.9:1<sup>22</sup>.

In two different studies, it was found that DVT commonly presents as unilateral swelling. In these studies, bilateral DVT was present in 31% (n =1029) and 5% (n=159) respectively<sup>1,2</sup>.

In a comprehensive review of published data from 1942 to 2004 by Jennifer L et al, focusing on chronic venous insufficiency, prevalence of chronic venous insufficiency varies substantially in different parts of the world, being highest in the western world<sup>23</sup>. It ranges from <1% to 76% in women and 2% to 56% in men for varicose veins. In this review it was established that the risk factors include older age, female gender, pregnancy,

and family history of venous disease, obesity and occupations associated with orthostasis. Factors like diet, physical activity and exogenous hormone use were not well documented. A population-based study done by Patrick et al in France that set out to assess prevalence, risk factors and clinical presentation showed there was a high prevalence of venous disorders of the lower limbs<sup>24</sup>. In the same study, varicose veins were found in 50.5% in women versus 30.1% in men whereas venous symptoms were more common in women than men too, 51% versus 20.4%<sup>47</sup>. A similar whole population study based in San Valentino in Italy found the prevalence of varicose veins being 7% (n=30,000)<sup>49</sup>. The Framingham study in Finland found the incidence of varicose veins ranged from 9-19 per 1000 persons in men and from 19-26 per 1000 in women, therefore demonstrating higher incidence in women<sup>25</sup>.

Edinburg vein study found the prevalence of varicose veins in men at 40% and 32% in women (n=1566), it was noted that prevalence increased with age<sup>26</sup>.

Depending on the population under study and the imaging technique used, Baker's cyst has a prevalence of between 5% to 32% of knee problems with two peak ages; 4 – 7 years and 35 – 70 years<sup>27</sup>. In older patients there are co-existent intra-articular knee pathologies whereas in children the cyst can be isolated and the knee joint is normal<sup>13,27</sup>. However in one prospective study of children, the prevalence of asymptomatic popliteal cyst was 2.4%<sup>28</sup>. In symptomatic children with knee arthritis including Juvenile rheumatoid arthritis, spondyloarthritis, psoriatic, septic and lupus arthritis, popliteal cysts had a prevalence of 61% with 37% having bilateral cysts<sup>29</sup>.

The worldwide prevalence of lower extremity peripheral artery disease is between 3 -12 %<sup>30-32</sup>. By the year 2010, 202 million people around the world were living with PAD<sup>33</sup>. The majority 69.7% of these people live in low / middle income regions of the world. In a study that surveyed 2174 patients by use of the Ankle Brachial Index (ABI) as a screening tool, it showed the prevalence of 0.9% (n=2174) between the ages of 40 and 49 years, 2.5% between the ages of 50 to 59 years, 4.7% between the ages of 60 to 69 years, and 14.5% for those above 70 years<sup>7</sup>.

## **2.2 Sonographic and clinical presentations of lower limb swelling**

Limb swelling has been a frequent clinical presentation in both inpatient and outpatient setups. Frequently in profiling the patients, clinicians think of deep venous thrombosis (DVT) first in view of the consequences of missing the diagnosis and end up with fatal pulmonary embolism. Against this background, the bulk of the research narrows down onto the two common etiologies: Cellulitis and Deep venous thrombosis. However, nested results from some of the studies bring into light variety of alternative diagnosis<sup>3,34,35</sup>.

Aywak et al, study done at Kenyatta National Hospital involving 55 patients with lower limb swelling found 19 (34.5%) patients with positive DVT using sonography<sup>3</sup>. Sonography was more useful as alternative diagnoses were found in 18 (48.6%) cases of those who were negative of DVT cases. The alternative diagnoses found during this study were; 10 cases with valvular insufficiency, 4 cases of lymphadenopathy and cellulitis, 2 each for post phlebitis syndrome and lymphoedema. A similar study done in Uganda by Mangeni et al, where lower limbs were examined in 86 subjects who were suspected to have DVT, by Sonography found 38 (48%) cases had DVT, with 2 cases having bilateral

DVT. Other diagnoses found were; 5 cases lymphadenopathy, cellulitis in 2 cases. Baker's cyst was found in 1 case, and gastrocnemius tumour in 1 case<sup>35</sup>. This study showed that male to female ratio was 1:1. The risk factors for DVT found include immobility (52.6%), Trauma (10.5%), pregnancy and contraception (7.9%), limb swelling (97.5%) and Pain (87.5%). DVT was associated with immobility (p-value=0.004) and unilateral lower limb swelling (p-value=0.022). However, the Mangeni et al study noted that when lower limb swelling is unilateral and diffuse, then the probability of DVT occurring significantly increases (p=0.001).

In a study done by Borgstede et al that followed 886 patients with lower limb swelling over a one-year period, DVT was positive in 229 (25.8%). Of the 657 cases who tested negative for DVT, alternative diagnosis was found in 51 (11.25%). These diagnoses were believed to account for the patients' symptoms though initially not given consideration. The study underscored the importance of thinking outside the traditionally common etiologies of lower limb swelling like DVT and cellulitis<sup>34</sup>.

It has also been shown that clinical manifestation of DVT in both history and physical examination finding is of limited value in its management. Furthermore, the study found that there is no association between DVT and immobility (OR=1.57), age (OR=1.0), gender (OR=1.68), trauma (OR=1.42), tenderness (OR=1.14), and diffuse swelling (OR=1.28)<sup>36</sup>. This study that set out to confirm DVT by Sonography in patients suspicious for DVT confirmed only 29% (n=1325) to be the positive cases. Therefore, several conditions may mimic it<sup>37,38</sup>. In a study by Langsfield et al., to determine incidence of

Baker's cyst discovered during Sonography examination to rule out DVT, he found that 3.1% (95/3072) were Bakers Cysts, and 7 of the 95 cysts were coexisting with DVT.

In Lymphoedema, there is fluid accumulation in the interstitial space due to anomalous development or injury of the lymphatic system<sup>39</sup>. Primary (idiopathic) lymphoedema is rare with incidence of 1.2 cases per 100 000 persons younger than 20 years of age<sup>40</sup>. Secondary lymphoedema is more common but the total burden of lymphoedema in general population is largely unknown<sup>41</sup>. Sonographic diagnosis of this entity is suboptimal with Lymphoscintigraphy being the method of choice<sup>9</sup>.

Sonography for a long time has been used to complement clinical examination in diagnosis of lower limb cellulitis; a life threatening pathological processes<sup>10</sup>. It's prevalence in Africa is largely unknown as data is missing, but is estimated to be 3.7%<sup>42</sup>. This is according to a population-based study in Minnesota, which also found that the incidence of cellulitis in the lower extremity significantly increased with age. There was no statistically significant difference between the genders. Due to overlapping nature of the clinical presentation of DVT and cellulitis, studies have been done to evaluate presence of coexisting DVT in patients with cellulitis. Maze MJ, found only 0.5% (n=200) of cellulitis had DVT also<sup>43</sup>. This was a rare finding, which only occurred in those with additional risk factors such as pelvic malignancy or injection drug use. Other studies have also demonstrated same findings<sup>44,45</sup>.

Sonography is important in confirmation of cellulitis and more so in determining presence of abscesses<sup>11</sup>. A study on the effect of soft-tissue ultrasound on the management of cellulitis in the emergency department revealed that soft tissue ultrasound changed the

physician's management in 56% of cases<sup>10</sup>. The studies done by Vivek et al and Adhikari et al also found that ultrasound provide valuable information in detection of occult abscess, prevention of invasive procedures and guidance for further imaging and consultation<sup>10,11</sup>.

Doppler ultrasound has become the mainstay of lower limb venous assessment in patients with chronic venous insufficiency, which is manifested typically by varicose veins<sup>46</sup>. It is noninvasive and can therefore be repeated, if necessary, without discomfort. Here the imaging component provides anatomic information which allows the identification of the venous segment being examined and will show any structural abnormalities, such as internal echoes in a thrombosed vein, or thickened walls in patients who have had previous episodes of thrombophlebitis<sup>5</sup>.

In a retrospective review of images by Ward et al, comparing the Magnetic resonance imaging (MRI) and Sonographic ability to detect Baker's cyst using MRI as a gold standard, review of the Sonographic images showed 100% sensitivity, specificity, positive predictive value, negative predictive value and accuracy in the diagnosis of Baker's cyst<sup>15</sup>. This study however identified minimal weakness of ultrasound to diagnose meniscal cysts and myxoid liposarcomas erroneously misdiagnosing them as Baker's cyst in one case of each.

Tumors could arise from a variety of soft tissue types on the lower extremities and Sonography play an important part in defining the tissues of origin and other characteristics of these masses, awareness of which can be important in the establishing correct diagnosis and guiding optimal management<sup>16</sup>. Soft tissue sarcomas are uncommon but when present,

they are commonly in the lower extremities (80-95%) and Sonography and MRI are the preferred modes of imaging<sup>17,47</sup>.

### **2.3 Problem Statement**

Lower limb swelling is a non-specific clinical presentation in many pathological entities that have different clinical outcomes. These entities range from acute fatal conditions like DVT that has potential to embolization into the pulmonary vasculature and cellulitis if not treated, to chronic debilitating conditions, which cause significant socioeconomic impact, like varicose veins and atherosclerosis. For instance, the total cost of CVI (an entity of lower limb swelling) to society, both direct and indirect, is estimated to be \$1 billion (US dollars) in Germany, France, and the United Kingdom.<sup>4</sup>

### **2.4 Research Question.**

What are the Sonographic features of lower limb swelling among patients presenting at Moi Teaching and Referral Hospital in Eldoret (MTRH)?

### **2.5 Justification**

Ultrasonography of lower limb has been shown to have comparable outcome with known gold standard techniques such as Venography, Arteriography and MRI. Due to non-specific nature of lower limb swelling pathologies, it is paramount to identify the specific diagnosis for correct management, as these etiologies are treatable and preventable.

In literature, there is scanty information on sonographic features of the lower limb swelling and more especially in our local setup (Kenya and East Africa). There is therefore need to document our own local data, outlining:

1. Sonographic features of lower extremity swelling
2. Clinically valuable information
3. Improve diagnostic and management protocols.

## **2.6 Objectives**

### **2.6.1 Broad objective**

To describe the Sonographic features of lower limb swelling among patients referred to the Radiology and Imaging department of Moi Teaching and Referral Hospital (MTRH), from January 2013 to October 2013.

### **2.6.2 Specific Objectives**

1. To describe sonographic findings of lower limb swelling among patients presenting at MTRH, from January 2013 to October 2013.
2. To describe demographic characteristics of patients presenting with lower limb swelling at MTRH, from January 2013 to October 2013.
3. To determine associations between Sonographic findings and clinical & demographic characteristics of patient presenting with lower limb swelling at MTRH, from January 2013 to October 2013.



## CHAPTER THREE: METHODOLOGY

### 3.1 Setting

The study was carried out at the Moi Teaching and Referral Hospital (MTRH) Eldoret, in the Radiology and Imaging department. This is the referral hospital for Western Kenya, Nyanza province and North Rift Valley region in Kenya. It also doubles as a teaching Hospital for the Moi University School of medicine.

The setting was chosen because it is a referral hospital for the western Kenya and North Rift Valley regions hence a big catchment area and also due to availability of resources and facilities to facilitate this study.

### 3.2 Study population

The study population was patients with lower limb swelling, seen at the Radiology and Imaging Department of the Moi Teaching and Referral Hospital- Eldoret.

### 3.3 Study design:

Cross sectional study.

### 3.4 Sample size

This was determined using the Fisher et al. (1998) formula equation:

$$n = \frac{Z^2 (1-\alpha/2) \cdot p (1-p)}{D^2}$$

Where

n = sample size;

Z = the z-value corresponding to 95% confidence (1.96);

$\alpha$  = significance level (5% i.e. 0.05);

p = estimated proportions of cases of lower limb swelling based on Doppler ultrasound numbers in MTRH Annually

D = precision (0.05)

Using p = 7 %

This is as per MTRH ultrasound records in 2012.

$$n = (1.96)^2 * 0.07(1-0.07) / (0.05)^2$$

$$= 100$$

### **3.5 Inclusion and exclusion criteria**

#### **3.5.1 Inclusion criteria**

1. Patients who present with lower limb swelling for the first time in the Radiology and Imaging Department.
2. Informed written consent given by patient of sound mind or parent/guardian if below 18 years.

#### **3.5.2 Exclusion criteria**

1. Patients not able to provide consent (too sick, mentally unstable, below 18 years without accompanying parent/guardian).

### **3.6 Sampling technique**

Consecutive sampling was used to identify the patients with lower limb swelling referred Radiology and Imaging Department for imaging. All the selected participants were eligible to participate. The researcher introduced herself/ himself to the participants who met the inclusion criteria; she explained to them the procedure verbally and provided a written version of it (in Kiswahili and English) and requested them to take part in the study (Appendix 2 and 3)

Once the participants made an informed decision, they signed the consent form. In case where the participant was a minor (below 18 years of age), both the guardian/parent and the minor were taken through the same process of the patient. The patient then assented and the guardian endorsed this decision. Where the minor declined, the guardian complied with patient's wish.

### **3.7 Data collection protocol**

Data was collected from January 2013 to October 2013. All patients presenting for investigations at the Radiology Department were screened. The ones with lower limb swelling were identified and consent administered. By consecutive sampling, 103 patients were eventually selected as shown in patient flow chart (Appendix IV). The researcher took a clinical history and did physical examination as per the data collection sheet (Appendix I). This data was then transferred to a computer database; double entry was used to ensure accuracy of the data. All patient details were kept confidential and data was and will only be available to the Investigator and the Supervisors via password protection.

## **3.8 Sonographic examination**

### **3.8.1 Ultrasound equipment**

High specification ultrasound equipment with B mode and M mode with color flow, spectral and power Doppler measurement capabilities were used in all cases. Both linear and curved array transducers with frequencies of at least 5MHz were available. Throughout the study period US machine (Phillips HD 11XE, Best-Eindhoven, Netherlands) was used.

### **3.8.2 Lower limb ultrasound examination procedure**

For ultrasound examination of the lower limbs, no preparation was required before the scan. Procedure was explained clearly to the patient who was then requested to lie on the examination couch in supine position. Patients were positioned so that the feet were substantially lower than the heart in order to generate sufficient hydrostatic pressure to assess the competency of the venous valves and for adequate filling of vessels when assessing for DVT. Vessels at the thigh were imaged with patient supine and leg slightly externally rotated. Popliteal vessels were studied with the patient in prone or lateral decubitus position with the knee flexed approximately 30 degrees. Tibial peroneal vessels were examined with the patient supine and knee slightly flexed and internally rotated for anterior tibial and peroneal vessels but externally rotated for posterior tibial vessels. Patients suspected to have chronic venous insufficiency were further imaged while erect.

Ultrasound examination was carried out starting with venous system examination (Venous Doppler), arterial system (Arterial Doppler) and then soft tissue sonographic examination for those who had focal swelling that needed further characterization.

### **3.8.2.1 Lower limb Venous Doppler**

The venous system was imaged as follows; a lower limb venous preset was selected and this typically set the pulse repetition frequency (PRF) at a 1000 Hz. A 5-7.5MHz linear array transducer was used for scanning deep and superficial veins. However, a 3 MHz curved array transducer was used whenever there was need to visualize the iliac veins to rule out iliofemoral disease, and in obese cases. All venous segments were examined in both longitudinal and transverse axis assessing the following; compressibility, flow pattern on colour Doppler and spectral Doppler. The assessment of venous reflux was performed using valsalva and augmentation maneuvers for proximal and distal areas respectively, with the transducer in a longitudinal plane to the vein. DVT was considered positive if there was absence of normal compressibility, a focal flow void with colour Doppler or absence of visible flow within a segment of a vessel on spectral Doppler. Venous incompetence was considered present if there was significant retrograde flow spontaneous or with distal augmentation on colour Doppler. On spectral Doppler, incompetence was diagnosed when the reflux duration was 1second or more. The sites that were assessed for venous reflux were; the common Femoral Vein above and below the Sapheno-femoral Junction, The Greater Saphenous Vein at its origin, The Popliteal Vein above and below the Lesser Saphenous Vein origin and at the origin of the Lesser Saphenous Vein. Varicosities were demonstrated by presence of tortuous dilated elongated vessels in the subcutaneous region, especially along greater or smaller Saphenous vein regions.

### **3.8.2.2 Lower limb Arterial Doppler**

A lower limb arterial setting was then selected for examining the arterial system. All the arterial segments were imaged with patient positioned as described above. Examination

was done using B-mode, colour Doppler and spectral Doppler in all segments. Spectral Doppler velocity measurements were made at an angle of 60° or less in relation to the probe. A normal peripheral artery Sonographic finding included a clear lumen, uniform walls with Uniform colour filling on colour Doppler and triphasic waveform on spectral Doppler. A diagnosis of arterial disease was made if there was demonstration of atheromatous plaques on the walls, filling defects on colour flow and abnormal waveforms. Abnormal dilatations or aneurysms if present were observed on B- mode and they were further assessed for presence of any occluding thrombus on colour Doppler.

### **3.8.2.3 Lower limb soft tissue Sonography**

Finally, a soft tissue Sonography was done using the following protocol. Application of copious amount of gel to the skin to enhance focusing on the most superficial layers and minimize transmitted pressure to the patient. With a Linear array probe of same frequency as mentioned above, and preset for subcutaneous selected, the area of interest i.e. swollen or erythematous was scanned in at least two orthogonal planes. Adjacent area and contralateral side scanning was done to help in comparison. Gray scale and Doppler imaging were both used. The sonographic examination included assessment for presence of masses, which were characterized into solid or cystic. Their site, shape, echogenicity, motion on compression and vascularity was also sought to help in sonographic diagnosis.

Subcutaneous tissues were also examined for the presence of oedema that was further characterized into inflammatory oedema as in cellulitis, by use of Doppler to assess for hyperemia and non-inflammatory oedema that does not present with hyperemia.

Gray scale images were printed and acquired for future reference for all the cases.

### **3.9 Outcome measures**

For each participant, the following information was documented: socio-demographic data (age, gender, residence and usual occupation), presenting symptoms, physical examination findings and Sonographic findings.

### **3.10 Quality control**

All sonographic examination findings were interpreted independently by two radiologists, where there was consensus, the findings were documented and if not in agreement, a third radiologist was consulted and the findings adopted.

### **3.11. Data management and analysis**

Data was analyzed using STATA version10. Descriptive statistics such as mean, median were used for continuous data while frequency listings were used for Categorical variables. To assess whether there was any association between categorical variables the chi-square test was used. In all analysis a p-value less than 0.05 was considered significant. The analysis entailed the following:

1. Clinical features (history and physical examination.
2. Analysis of age distribution in the pattern of lesions diagnosed.
3. Frequency of encountered lesions.

### **3.12 Data dissemination**

This thesis will hopefully be published in reputable journals, presented in seminars and conferences. A copy will be given to the management of MTRH to help inform protocols for managing lower limb swelling.

### **3.13 Ethical considerations**

1. Informed oral and written consent was obtained from the participants.
2. Every patient who qualified for the study and consented was recruited.
3. The ones who declined to take part in the study were investigated just as the patients who took part, but their findings were not included in this study but for their routine clinical management.
4. The results of the study will be disseminated through a written thesis and an oral defense in a forum that shall be convened by the department of Radiology and Imaging
5. Confidentiality of patient information is assured.
6. No harm was anticipated and none occurred during the study.
7. There was no material, financial or otherwise inducements.
8. Authority and approval was sought and granted by Institutional Research and Ethics Committee (IREC) and MTRH.



### **3.14 Study limitation**

1. Inability of ultrasound to provide conclusive diagnosis in patients with lymphoedema and lymphadenopathy.
2. Patients with extensive edema and severe tenderness were technically difficult to scan.

## CHAPTER FOUR: RESULTS

### 4.1 Socio-demographic data:

In this study, 103 patients were recruited. The sex distribution was skewed towards the female gender comprising of 68 (65%) with male to female ratio of 1:1.8. The median age was 41 years with age range of 13 to 91years. Table 1 summarizes the findings.

**Table1: Demographic characteristics**

<b>Variable</b>	<b>Female n=67(%)</b>	<b>Male n=36(%)</b>	<b>Total n=103(%)</b>
<b>Age in categories</b>			
<20 years	11 (16.5)	6 (16.6)	17 (16.5)
21-35 years	12 (17.9)	8 (22.3)	20 (19.4)
36-45 years	20 (29.8)	7 (19.5)	27 (26.3)
46-55 years	10 (14.9)	6 (16.6)	16 (15.4)
>55 years	14 (20.9)	9 (25.0)	23 (22.4)
<b>Occupation</b>			
Farmer	8 (11.9)	7 (19.5)	15 (14.6)
Student	10 (14.9)	6 (16.7)	16 (15.5)
Housewife	22 (32.8)	0 (0)	22 (21.4)
Employed	13 (19.4)	15 (41.6)	28 (27.2)
Business	3 (4.6)	1 (2.7)	4 (3.9)
Others	11 (16.4)	7 (19.5)	18 (17.4)

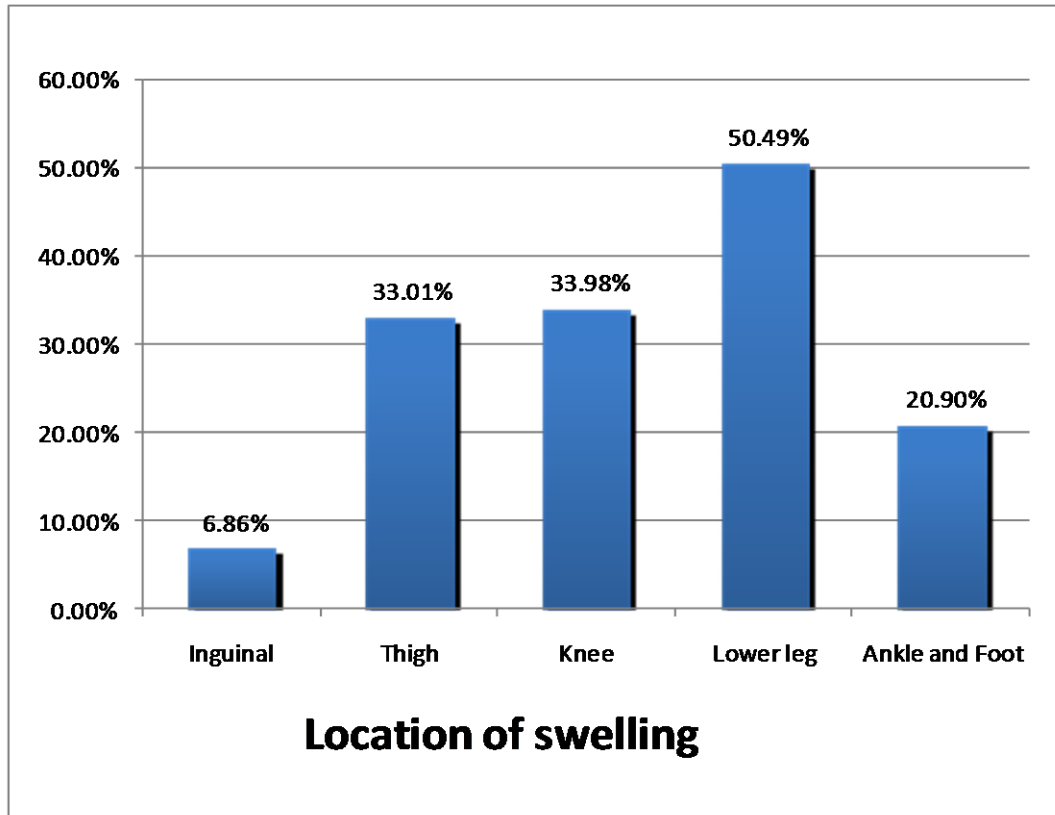
The main occupation of the study population was office employment (self-confessed) 28 (27.2%) followed by housewife 22 (21.4%) and students 16 (15.5%). Business people were the least represented among the participants.

#### **4.2 Clinical history**

In the history, the main presentation was unilateral lower limb swelling 80 (77.7%) and pain in 54 (52.4%) of the cases. Out of the 67 female participants, 5 (7.4%) confessed pregnancy and 20 (29.4%) were using contraceptives; 70% (14/20) of which were hormonal contraception. History of trauma was positive in 18 (17.5%) of the respondents, while prolonged immobility was in 19 (18.4%).

#### **4.3 Physical Examination**

Physical examination mainly revealed unilateral lower limb swelling 80 (77.7%), predominantly localized in 63 (61.2%) and diffuse in 40 (38.8%) of the cases

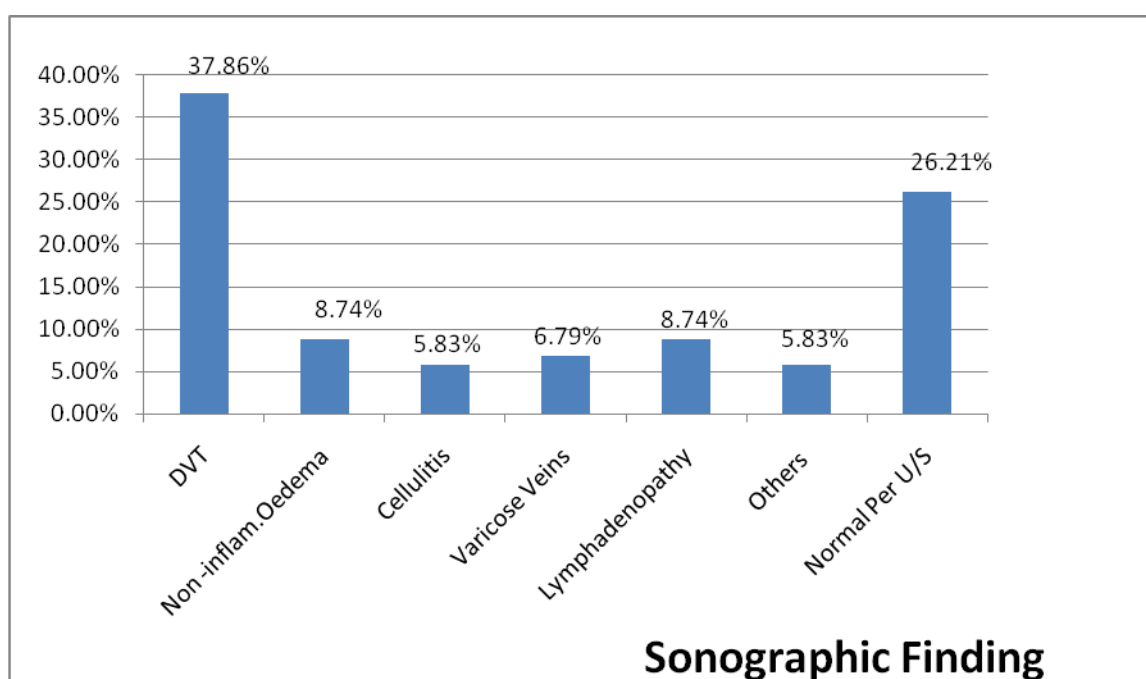


**Figure 3: A bar chart showing location of lower limb swelling**

The location of the swelling mainly involved the lower leg 52 (50.5 %) followed by the knee representing 32 (33.9%). Redness was observed in 31 (30.1%) while tenderness was elicited in 42 (39.8%). These findings are shown in Figure 3.

#### 4.4 Sonographic findings

The findings on Sonography depict deep DVT as the commonest diagnosis in 39 (37.9%) cases followed by Lymphadenopathy and oedema, each represented by 9(8.7%), varicose veins 8 (6.8%) and cellulitis 6 (5.8%). In 27 (26.2%) of the study population their Sonographic examination of the vascular and musculoskeletal system was normal. Details of these findings are shown in figure 4.

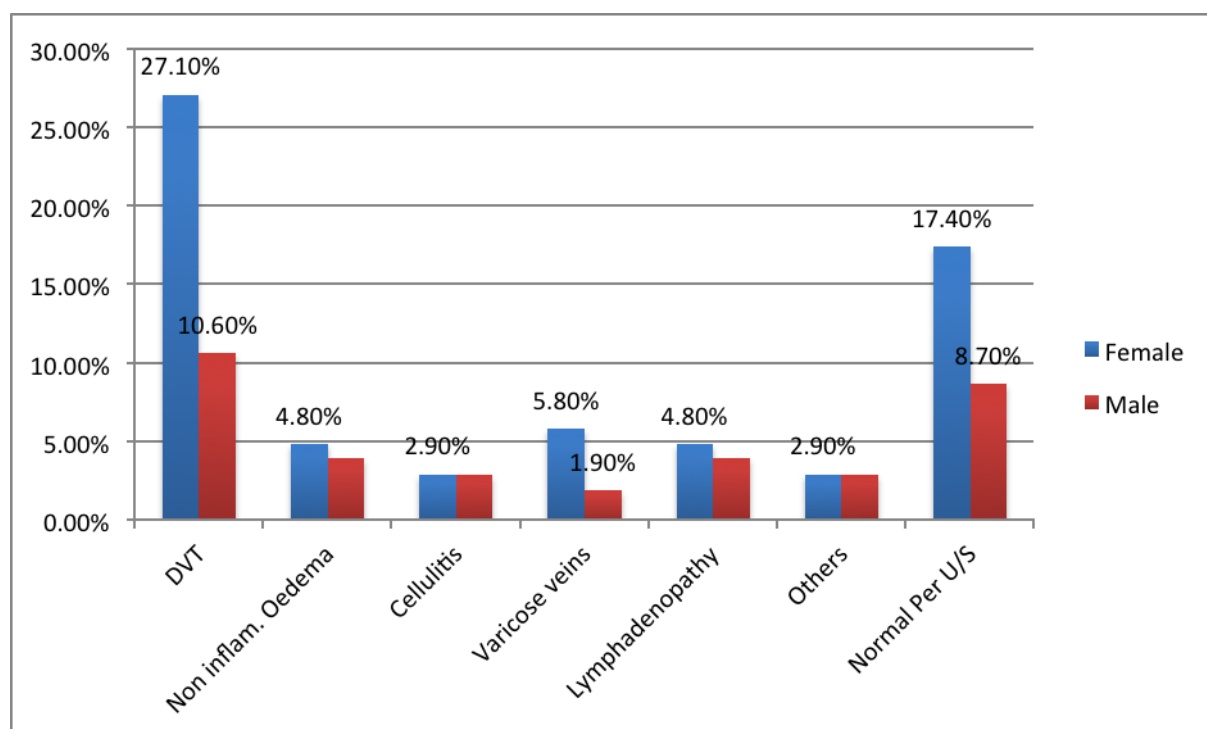


**Figure 4: A bar chart showing Sonographic Findings**

**Legend:** DVT: deep venous thrombosis. **Others:** atherosclerosis, baker's cyst, popliteal aneurysm, soft tissue tumor and pyomyositis

#### 4.5 Sonographic findings by gender

In DVT more women were involved 28(71.8%) than men, however cellulitis affected men and women equally as shown in figure 5.



**Figure 5: A bar chart showing Sonographic findings by gender.**

**Legend:** DVT- deep venous thrombosis. Others: atherosclerosis, baker's cyst, popliteal aneurysm, soft tissue tumor and pyomyositis.

Further analysis showed that DVT was common between the age group of 36-45 years amongst women while cellulitis and varicose veins were common in the above 55years category. This is detailed in table 2.

**Table 2: Summary of Sonographic findings per age categories and occupation**

Variable	DVT		Edema		Cellulitis		Varicose Veins	
	Male (n=11)	Female (n=28)	Male (n=4)	Female (n=5)	Male (n=3)	Female (n=3)	Male (n=2)	Female (n=6)
<b>Age in categories</b>	n/%	n/%	n/%	n/%	n/%	n/%	n/%	n/%
<20 years	2 (18.2)	7 (25.0)	1 (25.0)	0 (0.0)	1 (33.3)	0 (0.0)	0 (0.0)	0 (0.0)
21-35 years	3 (27.3)	5 (17.9)	1 (25.0)	1 (20.0)	0 (0.0)	0 (0.0)	0 (0.0)	0 (0.0)
36-45 years	2 (18.2)	8 (28.6)	0 (0.0)	0 (0.0)	1 (33.3)	2 (66.7)	0 (0.0)	1 (16.7)
46-55 years	2 (18.2)	4 (14.3)	1 (25.0)	0 (0.0)	0 (0.0)	0 (0.0)	1 (50.0)	2 (33.3)
>55 years	2 (18.2)	4 (14.3)	1 (25.0)	4 (80.0)	1 (33.3)	1 (33.3)	1 (50.0)	3 (50.0)
<b>Occupation</b>								
Farmer	3 (27.3)	5 (17.9)	1 (25.0)	1 (25.0)	0 (0.0)	0 (0.0)	1 (50.0)	0 (0.0)
Student	3 (27.3)	5 (17.9)	1 (25.0)	0 (0.0)	1 (33.3)	0 (0.0)	0 (0.0)	0 (0.0)
Employed	4 (36.4)	5 (17.9)	2 (50.0)	0 (0.0)	2 (66.7)	1 (33.3)	1 (50.0)	2 (33.3)
Business	0 (0.0)	2 (7.1)	0 (0.0)	0 (0.0)	0 (0.0)	0 (0.0)	0 (0.0)	0 (0.0)
Others	1 (9.1)	2 (7.1)	0 (0.0)	2 (40.0)	0 (0.0)	0 (0.0)	0 (0.0)	2 (33.3)
Housewife		9 (32.1)		2 (40.0)	-	2 (66.7)	-	2 (33.3)

Table 2 Continuation.

Variable	Others (Baker's cyst, PAD, Pyomyositis)		Lymphadenopathy		Normal	
	Male ( n=3) n/%	Female (n=3) n/%	Male (n=4) n/%	Female (n=5/%)	Male (n=9) n/%	Female(n=18) n/%
<b>Age in categories</b>						
<20 years	0 (0.0)	0 (0 .0)	1 (25.0)	1 (20.0)	0 (0.0)	3 (16.7)
21-35 years	0 (0.0)	1 (33.3)	0 (0.0)	0 (0.0)	2 (22.2)	5 (27.8)
36-45 years	1 (33.3)	0 (0.0)	2 (50.0)	1 (20.0)	2 (22.2)	6 (33.3)
46-55 years	0 (0.0)	1 (33.3)	0 (0.0)	1 (20.0)	3 (33.3)	1 (5.6)
>55 years	2 (66.7)	1 (33.3)	1 (25.0)	2 (40.0)	1 (11.1)	3 (16.7)
<b>Occupation</b>						
Farmer	0 (0.0)	1 (50.0)	0 (0.0)	1 (20.0)	2 (22.2)	1 (5.6)
Student	0 (0.0)	0 (0.0)	1 (25.0)	1 (20.0)	0 (0.0)	4 (22.2)
Employed	1 (33.3)	1 (50.0)	2 (50.0)	1 (20.0)	3 (33.3)	3 (16.7)
Business	0 (0.0)	0 (0.0)	0 (0.0)	0 (0.0)	1 (11.1)	1 (5.6)
Others	2 (66.7)	1 (0.0)	1 (25.0)	0 (0.0)	3 (33.3)	4 (22.2)
Housewife	-	0 (0.0)	-	2 (40.0)	-	5 (27.8)



Table 3 below shows in detail the sonographic findings in relation to symptoms and physical examination finding.

**Table 3: Summary of clinical presentation by Sonographic findings.**

<b>Clinical parameters</b>	<b>DVT n=39 (%)</b>	<b>Edema n=9 (%)</b>	<b>Cellulitis n=6 (%)</b>	<b>Varicose Veins n=8 (%)</b>	<b>Lymphade nopathy n=9 (%)</b>	<b>Others n=6 (%)</b>	<b>Normal n=27 (%)</b>
<b>HISTORY</b>							
<b>Swelling</b>							
<b>One limb</b>	34 (87.2)	5 (55.6)	5 (83.3)	6 (75.0)	5 (55.5)	6 (100.0)	19 (70.3)
<b>Two limbs</b>	5 (12.8)	4 (44.4)	1 (16.7)	2 (25.0)	3 (33.3)	0 (0.0)	9 (33.3)
<b>Pain</b>	34 (87.2)	1 (11.1)	4 (66.7)	4 (50.0)	4 (44.4)	1 (20.0)	5 (18.5)
<b>Pregnancy</b>	4 (10.3)	1 (11.1)	0 (0.0)	0 (0.0)	0 (0.0)	0 (0.0)	0 (0.0)
<b>Contraceptive</b>	8 (20.5)	1 (11.1)	1 (16.7)	4 (50.0)	0 (0.0)	1 (50.0)	5 (18.5)
<b>Hormonal contraceptive</b>	5 (12.8)	1 (11.1)	1 (16.7)	1 (12.5)	1 (11.1)	5 (100.0)	0 (0.0)
<b>Trauma</b>	8 (20.5)	1 (11.1)	2 (33.4)	1 (12.5)	0 (0.0)	1 (20.0)	5 (18.5)
<b>Immobility</b>	17 (43.6)	0 (0.0)	0 (0.0)	0 (0.0)	0 (0.0)	0 (0.0)	2 (7.4)
<b>PHYSICAL EXAM</b>							
<b>Bilateral Swelling</b>	5 (12.5)	4 (44.4)	1 (16.7)	2 (25.0)	3 (33.3)	0 (0.0)	9 (32.1)
<b>Unilateral swelling</b>	34 (87.2)	5 (55.6)	5 (83.3)	6 (75.0)	4 (44.4)	5 (100)	19 (67.9)
<b>Diffuse swelling</b>	23 (59.0)	5 (55.6)	3 (50)	1 (12.5)	3 (33.3)	0 (0.0)	5 (17.9)
<b>Localized</b>	16 (41.0)	4 (44.4)	3 (50)	6 (75.0)	5 (55.5)	6 (100)	23 (82.1)
<b>Redness</b>	17 (43.6)	1 (11.1)	4 (66.7)	1 (12.5)	4 (44.4)	1 (16.7)	2 (7.7)
<b>Tenderness</b>	26 (66.7)	1 (11.1)	4 (66.7)	1 (12.5)	4 (44.4)	1 (16.7)	3 (12.5)

#### 4.6 Associations of sonographic findings with clinical presentation

The chi-square test established that there was no association ( $p>0.05$ ) between the sonographic findings and demographic characteristics as depicted in table 4.

**Table 4: Cross tabulation of main Sonographic finding by key variable**

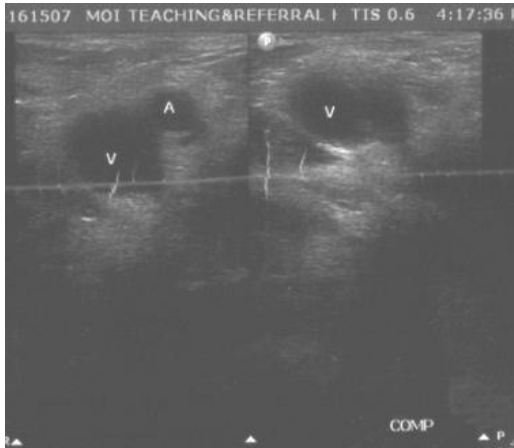
Variable	Diagnosis			p-value
	DVT n/%	Others (Cellulitis, PAD, Varicose veins, Bakers cyst, Oedema, Lymphadenopathy) n/%	Normal n/%	
<b>Gender</b>				
Female	28 (69.2)	22 (59.5)	18 (67.9)	0.636
Male	11 (30.8)	15 (40.5)	9 (32.1)	
<b>Age category</b>				
<20 years	9(23.1)	5(13.1)	3(11.5)	0.416
21-35 years	8 (20.5)	5 (13.1)	7 (26.9)	
36-45 years	10 (25.6)	9 (23.7)	8(30.8)	
46-55 years	6 (15.4)	6 (15.7)	4 (15.9)	
>55 years	6 (15.4)	13 (34.2)	4(15.9)	
<b>Occupation</b>				
Employed	8 (22.9)	11 (34.4)	2 (11.1)	0.304
Self employed	2 (5.7)	3 (9.4)	3 (16.7)	
Other	25 (71.4)	18 (56.3)	13 (72.2)	
<b>Contraceptive</b>				
No	16 (66.7)	13 (65)	14 (73.7)	0.825
Yes	8 (33.3)	7 (35)	5 (26.3)	

**Table 5. Clinical presentations of lower limbs patterns**

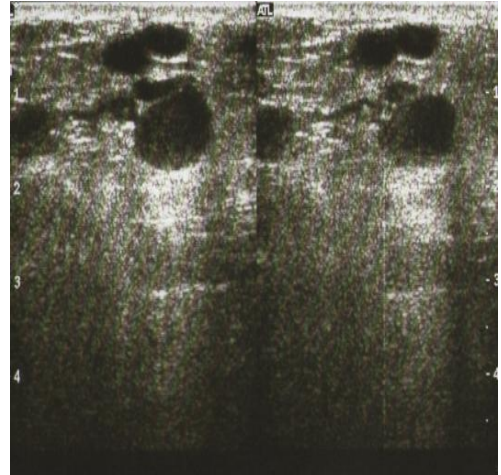
<b>Variable</b>	<b>DVT n/%</b>	<b>Others (Cellulitis, PAD, Varicose veins, Bakers cyst, Oedema, Lymphadenopathy)</b>	<b>Normal n/%</b>	<b>p-value</b>
<b>History of Trauma</b>	8 (22.9)	5 (13.9)	5 (19.2)	0.620
<b>History of Immobility</b>	17 (45.9)	0 (0)	2 (8)	0.000
<b>Swelling</b>				
Bilateral	5 (12.8)	11 (30.6)	9 (32.1)	0.105
Unilateral	34 (87.2)	25 (69.4)	19 (67.9)	
<b>Unilateral Swelling</b>	23 (59)	12 (33.3)	5 (17.9)	0.002
Diffuse	16 (41)	24 (66.7)	23 (82.1)	
Localized				
<b>Redness</b>	17 (50)	11 (30.6)	2 (7.7)	0.002
<b>Tenderness</b>	26 (81.3)	11 (30.63)	3 (12.5)	0.000

The data in table 5 showed that there was an association between DVT and immobility ( $p \leq 0.001$ ), diffuse unilateral swelling ( $p=0.002$ ), redness ( $p= 0.002$ ) and tenderness ( $p \leq 0.001$ ).

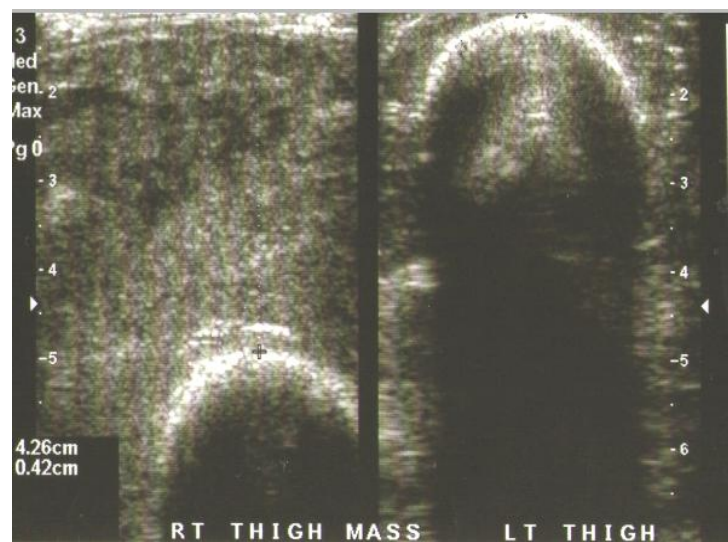
#### 4.7 Sample Sonographic images



**Figure 6.** DVT in 37 year old male.



**Figure 7.** Varicose veins, 58yr Old female



**Figure 8:** Pyomyositis, 26 year old male with intramuscular mass. Aspirated pus

## CHAPTER FIVE: DISCUSSION, CONCLUSIONS, AND RECOMMENDATIONS

### 5.1 Discussion

This study sampled 103 participants and females were the majority 67 (65%). Most of the female participants were housewives 22 (21.4%). This is similar to Bauersachs RM et al., study which found that majority of patients (62.8%) referred for a diagnostic work up were females<sup>20</sup>. The median age of presentation was 41 years.

The main sonographic findings found in this study were Deep Vein Thrombosis (DVT), Lymphadenopathy, non-inflammatory oedema, varicose veins, and cellulitis.

Deep venous thrombosis was the commonest diagnosis 39 (37.9%) in this study. This is consistent with KNH sonographic study which found that DVT was most prevalent (34.5%, n=55)<sup>3</sup>. In the Ugandan study, the prevalence of DVT was higher at 48% (n=92)<sup>35</sup>. Borgstede et al., found the prevalence of DVT in 25.8% (n=886)<sup>34</sup>. The higher prevalence in our study could be attributed to differences in nature of the population and its dynamics. The gender specific prevalence of DVT for women in our study was 41.8% (n=67) while that of males was 30.6% (n=36). This is in tandem with a study in Eritrea by Goitom et al., that also showed a higher prevalence in women compared to men<sup>22</sup>. However, in our study, most of the affected women were within the reproductive age as the prevalence was 28.4% (n=67) as compared to 19.4% (n=36) males for those below 45 years while it was 11.9% females' verses 11.1% males for those above 45 years. This could be explained by increased risk factors women are exposed to during the reproductive age such as

pregnancy, hormonal contraceptives and post partum. This prevalence changed for those participants above 45 years to more males versus females (36.5% versus 28.6%). This is consistent with Bauersachs et al., findings which found higher prevalence of DVT among males compared to women 37% (n=2998) vs. 24.3% (n=1778), further demonstrating that male gender was a predictor of presence of venous thrombosis independently of signs and risk factors for the same<sup>20</sup>. Andreou ER et al., found same results but lower prevalence, that men were more affected at 14.4% (n=1838) as compared to women at 9.4% (n=1838)<sup>21</sup>. This variation in findings could be due to different study methodologies as Andreou et al., study used only the clinical indicators for DVT, while this study used both clinical indicators and ultrasound.

Unilateral presentation of DVT was a majority 87.2% (34/39) comparing favorably with a retrospective study by Lemech M D et al., that found 69% (n=1029)<sup>1</sup> but differed in the bilateral presentation of the symptoms in 31% (n=1029) unlike in our study where we found only 12.8% (5/39). This could be as a result of the higher number recruited in their study, 1029 versus our 103 participants, and their study only looked at cases with DVT specifically. However a study by Garcia ND et al., looking at a contralateral asymptomatic limb duplex scan showed a lower figure of 5% (n=159)<sup>2</sup>, which is lower than our prevalence of 12.8% despite looking at the a highly selected population.

This study did not find any significant association between DVT and demographic characteristics (age, P-Value=0.416; gender, p-value=0.6; occupation, p-value=0.3; contraceptive 0.8). However, there was an association between DVT and immobility ( $p < 0.001$ ) diffuse unilateral swelling (p=0.002), redness (p= 0.002) and tenderness

( $p < 0.001$ ). These findings are similar to Mangeni et al. study, which found significant association between DVT and immobility ( $p=0.004$ ) and diffuse unilateral swelling ( $p < 0.001$ )<sup>35</sup>. However, our findings contrast Oudega R. et al., which found that there was no association between DVT and clinical and demographic characteristics<sup>34</sup>.

Lymphadenopathy and non-inflammatory oedema were the second most frequent diagnoses in this study each presented by a proportion of 8.7% (9/103). These two findings were non-specific as there are a number of pathologies that could cause these features. For instance non-inflammatory oedema could be as a result of lymphatic disorders (lymphoedema) that requires diagnosis by lymphoscintigraphy or due to a systemic condition like renal, liver and heart diseases that were beyond the scope of this study. This is consistent with a study by Kotaro et al., who correlated ultrasound finding in patients with lymphoedema diagnosed by lymphoscintigraphy<sup>9</sup>. They found that ultrasound was suboptimal in diagnosis and may require special transducer of between 50-100 MHz. A recommendation for further diagnostic studies was therefore recommended, and these included suggestions for lymph node biopsy and lymphoscintigraphy.

Varicose veins being typical manifestation of chronic venous insufficiency were identified in 7 (6.7%) cases similar to the San Valentino study in Italy, that found a prevalence of 7% ( $n=30,000$ )<sup>49</sup>. The prevalence was 9% (6/67) among women while it occurred in 5.6% (2/36) of the male participants in our study. That more women were affected also resonated with the San Valentino study as well as The Framingham study<sup>25,49</sup>. This value is however lower as compared to the Tempere Varicose Vein study in Finland where the prevalence was 7% among the male respondents against 25% in women<sup>48</sup>. In the Tempere Varicose

vein study, they used clinical presentation only unlike in our study where we used both clinical and ultrasound to confirm the presence of the same. Of value, our study found that most of those affected were above 45 years of age 87.5% (n=8) with none below the age of 35 years. This is in agreement with other studies showing that the prevalence of varicose veins seems to increase with increasing age and that it is more prevalent in women<sup>25,48,50</sup>.

However our results differ significantly with those found in a population based study done in France that found a prevalence of 50% (n=8 000) in women and presentation being more common in females. This literature too concurs with other studies that show that the prevalence of varicose veins ranges from <1% to 73% in females and 2% to 56% in males<sup>23</sup>. The differences could be attributed to variation in population characteristics, as the condition is less prevalent in developing countries. Accuracy in application of diagnostic criteria, and the quality and availability of medical diagnostic and treatment resources could be another contributor to the differences.

Few studies have documented the prevalence of cellulitis. A study done by McNamara and his colleagues found a lower incidence rate of 3.7%<sup>42</sup>. Our study found 6 (5.8%) cases and it affected males and females equally with no variation in presentation by age groups. The commonest presentation in our study was that of unilateral swelling 83.6% (n=6), pain, redness and tenderness in 66%. The McNamara study was a population-based study where they set out to find incidence of lower limb cellulitis unlike our hospital-based study. The highly selective population of participants in our study may have resulted in a higher prevalence.



The prevalence of peripheral artery disease in this study was 3 (2.9%). These were represented by 2 (1.9%) cases of atherosclerosis and one case (1%) of a popliteal artery aneurysm. These findings were mainly observed in males. These findings correlate well with other studies that have documented that worldwide prevalence is between 3-12%<sup>30-32</sup>.

The other lesions encountered were: Baker's cyst, soft tissue mass and pyomyositis that were represented by one case each. The prevalence of Baker's cyst in our study was <1%, which resonates well with the study done in Uganda, which also recorded 1 case of baker's cyst<sup>35</sup>. It is however lower than the quoted literature that shows 5-32% and was found in an adult<sup>27</sup>. This is probably low because there were no children below the peak age of 5 – 7 years for Baker cyst, were recruited in our study.

The association between Bakers cyst, PAD, varicose vein, cellulitis and lymphadenopathy and demographic and clinical characteristics was not ascertained due to the limitation of data.

## 5.2 Conclusions

Deep venous thrombosis is the commonest sonographic finding (37.9%) in lower limb swelling and it affects more women of reproductive age group.

There was an association between DVT and history of immobility ( $p<0.001$ ), diffuse unilateral swelling ( $p=0.002$ ), redness ( $p=0.002$ ) and tenderness ( $p<0.001$ ). There was no association between patterns of lower limb swelling and demographic characteristics.

## 5.3 Recommendations

1. Additional diagnostic techniques are needed in our setup like radio nuclear imaging (for lymphoscintigraphy) to complement Ultrasonography in cases where conclusive diagnosis is not arrived at using ultrasound.
2. Utilization of ultrasound as a broad spectrum imaging tool is recommended to for patients with lower limb swelling.
3. Further studies on patterns of limb swelling especially lymphoedema diagnosed by lymph node biopsy and lymphoscintigraphy, among other studies are called for.

## REFERENCES

1. Lemech MD, Sandroussi C, Makeham V et al., Is bilateral duplex scanning necessary in patients with symptoms of deep venous thrombosis? *ANZ J Surg.* 2004; 74 (10): 847-51.
2. Garcia N D, Morasch MD, Ebaugh JL, et al., Is bilateral ultrasound scanning of the legs necessary for patients with unilateral symptoms of deep vein thrombosis? *J Vasc Surg.* 2001; 34(5): 792-7.
3. Aywak AA and JV Masesa. Comparison of sonography with venography in the diagnosis of deep venous thrombosis. *East Afr Med J.* 2007; 84 (7): 304-11.
4. Ruckley CV. Socioeconomic impact of chronic venous insufficiency and leg ulcers. *Angiology.* 1997; 48:67-9.
5. Nicolaides AN. Investigation of chronic venous Insufficiency, A consensus statement. *Circulation.* 2000; 102: 126- 63.
6. Mustapha JA, Saab F, Diaz-Sandoval L et al., Comparison between angiographic and arterial duplex ultrasound assessment of tibial arteries in patients with peripheral arterial disease: On behalf of the joint endovascular and non-invasive assessment of limb perfusion. *JENALI group.* 2013; 25:11.
7. Dhaliwal G. and Mukherjee D., Peripheral arterial disease: epidemiology, natural history, diagnosis and treatment. *Int J Angiol.* 2007; 16 (2): 36-44.

8. Weissleder R. The lymphatic system: diagnostic imaging studies. *Radiology*. 1989;172:315-7.
9. Kotaro S. and Blaivas M., Significance of ultrasound examination of skin and subcutaneous tissue in secondary lower extremity lymphedema. *Ann Vasc Dis*. 2013; 6(2): 180-8.
10. Vivek S., Nael H., James N. et al, The effect of soft tissue ultrasound on the management of cellulitis in the Emergency department. *Academic Emergency Medicine* 2006; 13: 384- 8.
11. S. Adhikari and Blaivas M., Sonography First for subcutaneous abscess and cellulitis evaluation. *J Ultrasound Med*. 2012; 31 (10): 1509-12.
12. Chao HC, Lin SJ, Huang YC et al., Sonographic evaluation of cellulitis in children. *J Ultrasound Med*. 2000; 19 (11): 743-9.
13. Fritschy D, Fasel J, Imbert JC, et al., The popliteal cyst. *Knee Surg sportsTraumatol Arthrosc* 2006; 14: 623.
14. John R Handy. Popliteal cysts in adults: A review. *Semin Arthritis Rheum*. 2001; 31: 108.
15. Ward EE, Jacobson JA, Fessel DP, et al., Sonographic detection of baker's cyst: comparison with MRI imaging. *AJR*. 2001; 176: 373-80.

16. Wook J, Kim GY, Park SY et al., The spectrum of vascularized superficial soft-tissue Tumors on Sonography with a histopathologic correlation. *AJR*. 2010;195:439 – 45.
17. Lai Yc, Chiou HJ, Honder HT, et al., Ultrasonographic and MR findings of Alveolar soft part sarcoma. *J Chin Med association* 2009; 72: 336-9.
18. Ginsberg J S. Management of venous thromboembolism. *N Engl J Med*. 1996; 335:1816-28.
19. Oger E. Incidence of venous thromboembolism: a community based study in Western France. *Thromb Haemost*. 2000; 83 (5): 657-60.
20. Bauersachs RM, Riess H, Hach-Wunderle V et al., Impact of gender on clinical presentation and diagnosis of deep vein thrombosis. *Thromb Haemost*. 2010; 103(4).
21. Andreou ER, Koru-Sengul T, Linkin L et al., Differences in clinical presentation of deep vein thrombosis in men and women. *J Thromb Haemost*. 2008; 6(10):1713-9.
22. Goitom Hagos. Lower Extremity Deep Vein Thrombosis among Intensive Care Patients in Orotta National Referral Hospital. *Journal of Eritrea Medical Association*. 2009; 4 (1).
23. Jennifer L B-D, John RP, Jennifer SE et al., The epidemiology of chronic venous insufficiency and varicose veins. *Annals of Epidemiology*. 2005; 15(3): 175-84.

24. Patrick HC, Maricq HR, Biro C et al., Prevalence, risk factors and clinical patterns of chronic venous disorders of lower limb: A population based study in France. *Journal of Vascular surgery*. 2004; 40 (4): 650-9.
25. Brand FN Dannenberg AL, Abbott RD, et al., The epidemiology of varicose veins: the Framingham study. *Am J Prev Med*. 1988; 4: 96–1.
26. Evans CJ, Fowkes FG, Ruckley CV et al., Prevalence of varicose veins and chronic venous insufficiency in men and women in the general population: Edinburg Vein study. *J Epidemiol Community Health*. 1999; 53(3):149-53.
27. Gristina AG and Wilson PD. Popliteal cysts on adults and children. A Review of 90 cases. *Arch Surg*. 1964; 88: 357.
28. Sail R, Rupp S, Jochum P, et al., Prevalence of popliteal cysts in children. A sonographic study and review of the literature. *Arch Orthop Trauma surg*. 1999; 119: 73.
29. Szer IS, Denardo BA, McCauley RG et al., Ultrasonography in the study of prevalence and clinical evaluation of popliteal cysts in children with knee effusions. *J Rheumatol*. 1992; 19: 458.
30. Norgren L HW, Dormandy JA, Nehler MR et al., Intersociety consensus for the management of peripheral arterial disease (TASC II) *J Vasc Surg* 2007; 45(S): S5.
31. Olin JW and Sealove BA, Peripheral artery disease: current insights into the disease and its diagnosis and management. *Mayo clin proc* 2010; 85: 678.

32. Novo S. Classification, epidemiology, risk factors and natural history of peripheral arterial disease. *Diabetes Obes Metab.* 2002; 4 (Suppl 2): S1.
33. Fowkes FG, Rudan D, Aboyans V et al., Comparison of global estimates of prevalence and risk factors for peripheral artery disease in 2000 and 2010: a systematic review and analysis. *Lancet.* 2013; 382:1329.
34. Borgstede JP and Clagget GE, Types, frequency and significance of alternative diagnoses found during duplex Doppler venous examination of the lower extremities. *Ultrasound Med.* 1992; 11: 85-6.
35. Mangeni F, Kawooya MG, Ssali F et al., Sonography and risk factors for lower limb deep venous thrombosis at Mulago hospital, Uganda. *East Afr med J.* 2006; 83:443-9.
36. Oudega R MK and Hoes AW, Limited value of patient history and physical examination in diagnosing deep vein thrombosis in primary care. *Fam Pract.* 2005; 22::86-91.
37. Langsfield M, Matteson B, Johnson W et al., Bakers cyst mimicking the symptoms of deep vein thrombosis: Diagnosis with venous duplex scanning. *J Vasc Surg.* 1997; 25:275- 9.
38. Jamadar DA, Jacobson JA, Theisen SE et al., Sonography of the painful calf: differential considerations. *AJR Am J Roentgenol.* 2002;179:709–16.

39. Rockson SG and Rivera KK, Estimating the population burden of lymphedema. *Ann N Y Acad Sci.* 2008; 1131:147-54.
40. Smeltzer DM, Stickler GB and Schirger A., Primary lymphedema in children and adolescents: a follow upstudy and review. *Pediatrics.* 1985; 76:206-18.
41. William AF, Franks PJ and Moffat CJ, Lymphoedema: Estimating the size of the problem. *Paliat Med.* 2005; 19(4):300-13.
42. McNamara DR, Tleyjeh IM, Lahr BD et al., Incidence of lower extremity cellulitis; a population based study in Olmsted County, Minnesota. *Mayo clinic Proc.* 2007; 82(7):817-21.
43. Michael J Maze, Sean Skea, Alan Pithie et al., Prevalence of concurrent deep venous thrombosis in patients with lower limb cellulitis: a prospective cohort study. *BMC infectious Disease.* 2013; 13: 141.
44. Bersier D and Bounameaux H. Cellulitis and deep vein thrombosis: a controversial association. *J Thromb Haemost.* 2003; 1(4): 867-8.
45. Bendick PJ. Cellulitis and the prevalence of deep vein thrombosis. *J Diagn Med Sonog* 1996;12(4):170-4.
46. Allan PL. Role of ultrasound in the Assessment of Chronic Venous Insufficiency. *Ultrasound Quarterly.* 2001; 17: 3-10.



47. Sullivan PJO, Harris AC and Munk PL, Radiological features of synovial cell sarcoma. *British journal of Radiology* 2008; 81: 346-56.
48. Tiina Ahti. Risk factors of varicose veins. Tampere, Finland: Tempereen Yliopistopaino Oy – *Juvenes Print.*; 2010.
49. Cesarone MR, Belacaro G, Nicolaidis AN et al., `Real` Epidemiology of varicose veins and chronic venous disease: The San Valentino vascular screening project. *Angiology*.53: 119-30.
50. ACR AS. Practice Guideline for the Performance of Peripheral Venous Ultrasound Examinations. *J Ultrasound Med* 2011; 30(1): 143-50.

## APPENDIX I.

### Data collection sheet

#### 1. Socio-demographic data:

Study number..... Hospital no.....

Date of Birth.....

Gender                      Male/Female

Residence/ address.....

Usual Occupation.....

#### 2. History

Lower limb swelling                      one limb /two limbs

Duration of swelling.....

Pain                      YES / NO

Duration of pain.....

Parity .....

Pregnancy                      YES/ NO

Contraceptive use YES/ NO

If yes, is it hormonal? YES/ NO

Other related symptoms if present .....

History of trauma including surgery and labor YES /NO

History of immobility and long travel YES /NO

Duration of immobility.....

1. Physical examination finding

Swelling

Bilateral / unilateral

Diffuse /localized

Other related swellings.....

Location

Inguinal

Thigh

Knee/popliteal

Lower leg

Ankle and foot

Redness YES /NO

Tenderness YES/ NO

## Sonographic findings

### i. Vascular

Venous	compressibility	YES /NO
	Filling defect	YES /NO
	Augmentation response.....	
	Valsalva maneuver	
	backflow,	
	Reversal of flow,	
	No flow	
	Doppler flow	YES/ NO
Arterial	Aneurysm	YES /NO

### ii. Soft tissue lesions

Site .....

Size .....

Shape .....

Echogenicity .....

Vascularity.....

Cystic / solid.....

Comparison with normal tissue.....

### iii. Others

Diagnosis

Recommendations

## **APPENDIX II: CONSENT FORM (ENGLISH VERSION)**

I am Dr. Ochako Agnes Kwamboka, a postgraduate student in the Moi University School of Medicine. I am undertaking a Masters degree in the specialty of Radiology and imaging. Please read through this document and at the bottom append your signature in any of the three provided blank spaces as appropriate. I intend to undertake a study on the findings of the examination or evaluation of your lower limbs. The study has been scrutinized by the relevant institutional authorities.

The aim of this study is to identify the various patterns of abnormalities that cause the limbs to swell. Normally when patients with such a problem come to this hospital, they undergo this test aimed at unraveling the cause. The test entails the following: Applying a lubricating gel on your limb and the test modality does not emit radiation material but uses sound waves. The test has no harmful effect to your health.

The results from this test will help the team of doctors treating you to know the cause of your illness and through that, guide them in giving you the appropriate treatment. The information gathered will also be useful in treating other patients who would present with a similar ailment/s in the future.

You are requested to voluntarily allow me/give permission to include you in this study.

In the event that you consent to participate, every bit of personal information that you shall provide will be held confidential and no part of it would be printed or disseminated without your written consent.

In the event you do not agree to take part, you shall be evaluated along with other patients but your result/ information will not be included in the list of those who consent. Treatment will not be denied and hospital policy will prevail as stipulated.

Where a minor declines to take part even in the event the guardian/parent consents, he/ she will not be included in the study. The participant shall indicate by ticking in the provided boxes.

I allow the minor to participate

Name ..... Relationship- parent  guardian

I do not allow the minor to participate

Name..... Relationship- parent  guardian

I agree to take part (adults)

I do not agree to take part (adults)

Name (participant).....Signature..... Date.....

Name (researcher).....Signature..... Date.....

### **APPENDIX III : CHETI CHA RUHUSA:**

Jina langu ni Dkt. Ochako Agnes kwamboka. Ninasomea shahada ya uzamili katika chuo kikuu cha Moi Kitivo cha Afya. Nina nia ya kufanya utafiti kwa ajili ya kukusanya tarakimu kuhusu ugonjwa wa kuvimba kwa sehemu za miguuni. Matarajio ya utafiti huu ni kujaribu kubainisha chanzo na haswa kunakirisha vyanzo hivyo kwa minajili ya matibabu na utafiti katika siku sijazo. Utafiti utakao fanyiwa hauna madhara yoyote yale yanayodhuru afya ya binadamu. Kwa kawaida wagonjwa wanao hudumiwa kwenye hospitali hii, hufanyiwa utafiti huu kwa minajili ya matibabu.

Uchunguzi utakao fanyiwa utajumuisha kuwekewa kifaa maalum kwenye sehemu ya mwili ambayo itakuwa imepakwa mafuta maalum ambayo hayana madhara yoyote.

Matokeo ya uchunguzi huu yatasaidia kuwaelekeza madaktari na wauguzi wanao kuhudumia ili wakupe matibabu kikamilifu. Vile vile wale watakaofuata baada yako wakiwa na shida kama hii watafaidika kwa sababu ya mchango wako kwa utafiti huu.

Ombi langu kwako niruhusu kukujumuisha katika utafiti huu. Matokeo ya huu utafiti yatatolewa kwa timu ya madaktari na wauguzi wanao kuhudumia ndiposa kuchangia kwa matibabu yako. Hakuna habari zozote zitakazo tolewa kwa mtu yeyote mwingine ila tu kwa idhini yako mwenyewe iliyoandikwa na kutiwa sahihi.

Hakuna habari yoyote ambayo imefichwa kutoka kwako na iwapo hautakubali kujumuika kwenye zoezi hili, ugonjwa wako utachunguzwa kama vile wengine wote

wanavyochunguzwa kulingana na kanuni za hosipitali hii, lakini matokeo yako hayata jumuishwa katika daftari la mwisho kwa ajili ya zoezi hili.

Mgonjwa mwenye ni chini ya miaka kumi na minane, mzazi atamtilia sahihi. Iwapo huyo mtoto (mgonjwa) atakataa kujumuishwa, basi hatajumuishwa.

**Nakubali kujumuishwa**

Jina : .....

Sahihi.....Tarehe : .....

**Sikubali kujumuishwa**

Jina : .....

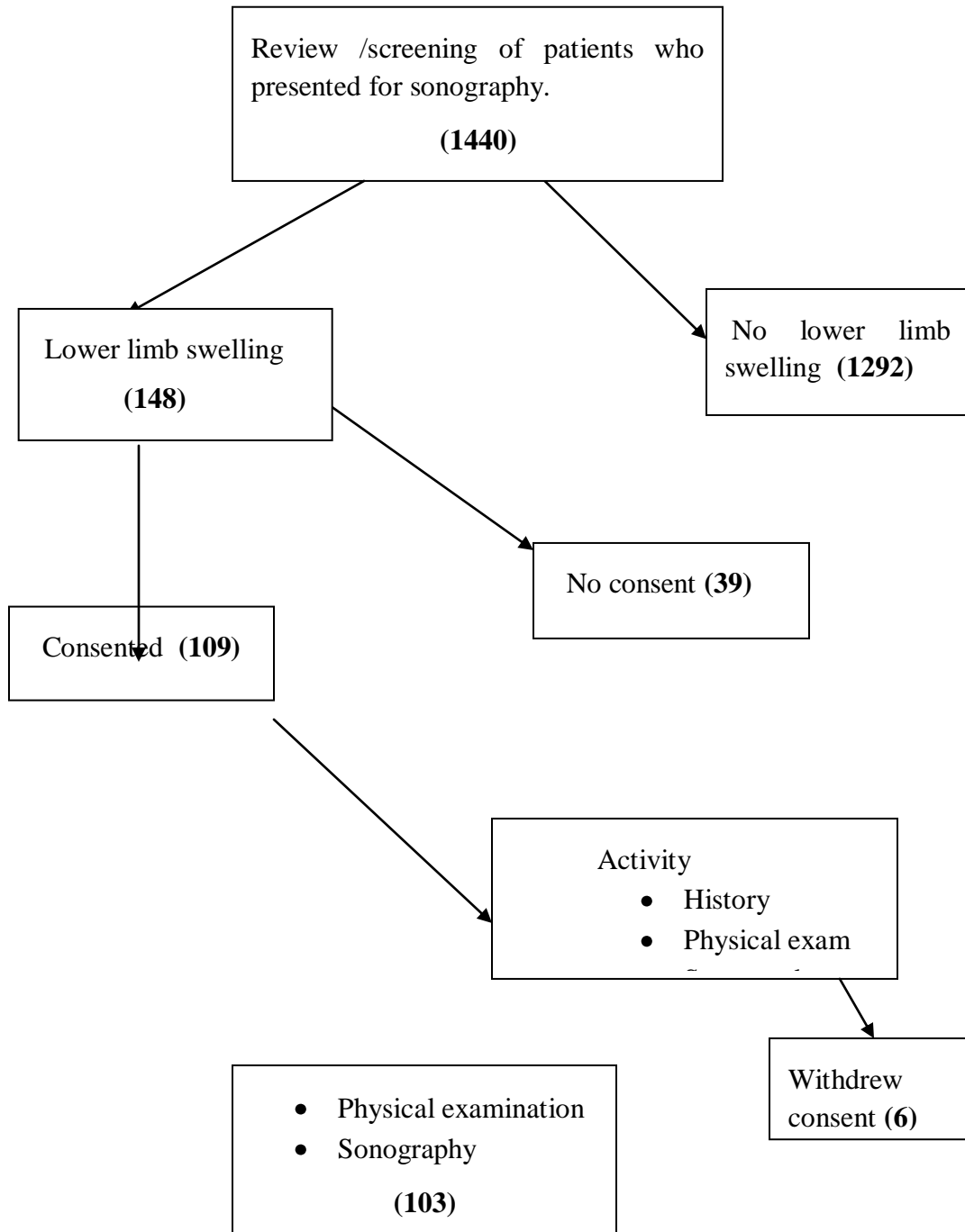
Sahihi..... Tarehe : .....

Jina la mtafiti : .....

Sahihi.....Tarehe .....



## APPENDIX IV : CHART SHOWING FLOW OF PATIENTS



## APPENDIX V: WORK PLAN

Activity	Duration	Time Frame
Overall period	24 Months	March 2012 – June 2014
Literature Review	1 Month	March 2012
Proposal Development	2 Months	April 2012 – June 2012
Submitting to IREC for Approval	1 Month	June 2012
Soliciting for funds	2 Months	October 2012 – December 2012
Data collection	8 Months	January 2013 – October 2013
Data Analysis	2 Months	November 2013 – December 2013
Thesis write up	2 Months	January 2013 – April 2014
Defense	2 Months	May 2014 – June 2014
Document cleaning	1 Month	May 2014
Final report	1 Month	June 2014

## APPENDIX VI: BUDGET

<u>ITEM</u>	<u>QUANTITY</u>	<u>COST @ Ksh.</u>	<u>TOTAL Ksh.</u>
Lower limb ultrasound	100	3000	300 000
Printing papers	6	500	3 000
Note books	10	150	1 500
Staplers	2	400	800
Staples	2 packs	300	600
Flash disks	2	2000	4 000
Foolscap	2	400	800
Pens	20	25	500
Pencils	15	20	300
Erasers	10	45	450
Printing costs	2000 pages	10	20 000
Photocopying costs	2000 pages	2	4 000
Binding spiral	10 copies	450	4 500
Binding hard cover	10 copies	1000	10 000
Communication			5 000
Consultancy (statistician)			30 000
Contingencies (10 %)			38 545
<b>Total</b>		<b>KShs.</b>	<b>423 995.00</b>

## APPENDIX VII: IREC APPROVAL LETTER



MOI TEACHING AND REFERRAL HOSPITAL  
P.O. BOX 3  
ELDORET  
Tel: 334711/2/3

Reference: IREC/2012/132  
Approval Number: 000892

Dr. Ochako Agnes Kwamboka,  
Moi University,  
School of Medicine,  
P.O. Box 4606-30100,  
ELDORET-KENYA.

Dear Dr. Ochako,

**RE: FORMAL APPROVAL**

The Institutional Research and Ethics Committee have reviewed your research proposal titled:

*"Sonographic Findings In Lower Limb Swelling in Patients Seen at Moi Teaching and Referral Hospital."*

Your proposal has been granted a Formal Approval Number: **FAN: IREC 000892** on 18<sup>th</sup> September, 2012. You are therefore permitted to begin your investigations.

Note that this approval is for 1 year; it will thus expire on 17<sup>th</sup> September, 2013. If it is necessary to continue with this research beyond the expiry date, a request for continuation should be made in writing to IREC Secretariat two months prior to the expiry date.

You are required to submit progress report(s) regularly as dictated by your proposal. Furthermore, you must notify the Committee of any proposal change (s) or amendment (s), serious or unexpected outcomes related to the conduct of the study, or study termination for any reason. The Committee expects to receive a final report at the end of the study.

Yours Sincerely,

**PROF. E. WERE**  
**CHAIRMAN**  
**INSTITUTIONAL RESEARCH AND ETHICS COMMITTEE**

cc: Director - MTRH  
Principal - CHS  
Dean - SOM  
Dean - SPH  
Dean - SON  
Dean - SOD



MOI UNIVERSITY  
SCHOOL OF MEDICINE  
P.O. BOX 4606  
ELDORET  
Tel: 334711/2/3

18<sup>th</sup> September, 2012



## APPENDIX VIII: MTRH APPROVAL LETTER



### MOI TEACHING AND REFERRAL HOSPITAL

Telephone: 2033471/2/3/4  
 Fax: 61749  
 Email: director@mtrh.or.ke  
 Ref: ELD/MTRH/R.6/VOL.II/2008

P. O. Box 3  
 ELDORET

18<sup>th</sup> September, 2012

Dr. Ochako Agnes Kwamboka,  
 Moi University,  
 School of Medicine,  
 P.O. Box 4606-30100,  
ELDORET-KENYA.

**RE: APPROVAL TO CONDUCT RESEARCH AT MTRH**

Upon obtaining approval from the Institutional Research and Ethics Committee (IREC) to conduct your research proposal titled:

*"Sonographic Findings in Lower Limb Swelling in Patients seen at Moi Teaching and Referral Hospital."*

You are hereby permitted to commence your investigation at Moi Teaching and Referral Hospital.

  
**DR. J. KIBOSIA**  
**DIRECTOR**  
**MOI TEACHING AND REFERRAL HOSPITAL**

CC - Deputy Director (CS)  
 - Chief Nurse  
 - HOD, HRISM