

**MORPHOLOGY OF THE BLACK KENYAN ADULT DISTAL FEMUR  
BASED ON NORMALIZED RATIOS - A CADAVERIC STUDY**

**DR. AHMED, SAIDINA ESMAIL**

**SM/PGORT/10/14**

**Thesis submitted in partial fulfilment of the requirements for the  
award of a Masters of Medicine Degree in Orthopaedic Surgery of  
Moi University**

**©2019**

## DECLARATION

### Declaration by the Candidate

I declare that this thesis is my original work and has not been presented to any other university/institution for consideration.

Dr. Ahmed, Saidina Esmail,

SM/PGORT/10/14

Signature..... Date.....

### Declaration by Supervisors

This thesis has been presented for examination with our approval as the Moi University supervisors;

Prof. El-Badawi, M. G. Y.

Professor of Human Anatomy

Department of Human Anatomy

Moi University

Signature..... Date.....

Dr. Ayumba, B. R.

Senior Lecturer and Consultant Orthopaedic Surgeon

Department of Orthopaedic and Rehabilitation

Moi University

Signature..... Date.....

Dr. Njoroge, A. N.

Consultant Orthopaedic Surgeon and Lecturer

Department of Human Anatomy

Moi University

Signature..... Date.....

**DEDICATION**

I dedicate this work to my loving daughter, Sameeha.

## TABLE OF CONTENTS

DECLARATION .....	ii
DEDICATION .....	iii
TABLE OF CONTENTS .....	iv
LIST OF TABLES .....	vi
LIST OF FIGURES .....	vii
ACKNOWLEDGEMENT .....	viii
ABBREVIATIONS .....	ix
DEFINITION OF KEY TERMS .....	x
ABSTRACT .....	xi
CHAPTER ONE: INTRODUCTION .....	1
1.1 Background .....	1
1.2 Problem Statement .....	4
1.3 Justification .....	4
1.4 Research question .....	5
1.5 Objectives .....	5
1.5.1. Broad objective .....	5
1.5.2. Specific objectives .....	5
CHAPTER TWO: LITERATURE REVIEW .....	6
2.1 The distal femur anatomy .....	6
2.2 Variations in the morphology of the distal femur .....	6
2.3 Total Knee Arthroplasty implant mismatch .....	8
CHAPTER THREE: METHODOLOGY .....	10
3.1 Study site .....	10
3.2 Study design .....	10
3.3 Study population .....	10
3.4 Eligibility criteria .....	10
3.4.1 Inclusion criteria .....	10
3.4.2 Exclusion criteria .....	10
3.5 Sampling and Sample size .....	10
3.6 Materials and methods .....	11
3.7 Data management .....	15
3.8 Data analysis .....	15
3.9 Ethical considerations .....	16
3.10 Study Limitations .....	16

CHAPTER FOUR: RESULTS.....	17
4.1 Demography.....	17
4.2 Distal Femora Anatomy.....	18
4.3 ML/AP Ratio.....	19
4.4 AML/PML Ratio.....	20
4.6 Differences between Male and Female Distal Femora.....	22
4.7 Differences between the black Kenyan distal femora to the distal femora of other ethnicities as per the literature.....	32
CHAPTER FIVE: DISCUSSION.....	35
5.1 ML/AP Ratio.....	35
5.2 AML/PML Ratio.....	37
5.3 MAP/LAP Ratio.....	38
5.4 Differences between Male and Female.....	39
CHAPTER SIX: CONCLUSIONS AND RECOMMENDATIONS.....	41
6.1 Conclusions.....	41
6.2 Recommendations.....	42
REFERENCES.....	43
APPENDICES.....	46
Appendix 1: Equipment and instruments.....	46
Appendix 2: Data collection form/sheet.....	47
Appendix 3: Budget.....	48
Appendix 4: Work Plan.....	49
Appendix 5: Figure of the distal femur.....	50
Appendix 6: IREC Approval.....	51
Appendix 7: Approval Letter from Human Anatomy Department, Moi University...52	
Appendix 8: Approval Letter from Human Anatomy Department, University of Nairobi.....	53

## LIST OF TABLES

Table 4.2.1: Descriptive summary of the various parts of the distal femora .....	18
Table 4.6.1: Comparison of the various parts of the distal femora by side of the limb .....	22
Table 4.6.2: Comparison of the different parts of the distal femora by gender .....	23
Table 4.6.3: Comparison of the left and the right parts of the female distal femora ...	26
Table 4.6.4: Comparison of the left and the right parts of the male distal femora .....	27
Table 4.6.5: Comparison of the left female parts of the distal femora to the left parts of the male distal femora.....	28
Table 4.6.6: Comparison of the dimensions of the right female distal femora to the right male distal femora ...	30
Table 4.7.1.1: Comparison of data of black Kenyan distal femora to the African .....	32
Table 4.7.1.2: Comparison of data of black Kenyan distal femora to the Caucasian ..	32
Table 4.7.1.3: Comparison of data of black Kenyan distal femora to the East Asian distal femora.....	33
Table 4.7.2: Comparison of data of black Kenyan distal femora to the Southeastern Chinese distal femora.....	33
Table 4.7.3: Comparison of data of black Kenyan distal femora to the Chinese distal femora .....	34
Table 4.7.4: Comparison of data of black Kenyan distal femora to the Indian distal femora .....	34

## LIST OF FIGURES

Figure 1.1: The types of distal femora based on normalized ratios.....	1
Figure 3.6.1: Measurement of Mediolaral Width .....	13
Figure 3.5.1: Measurement of Mediolaral Width .....	13
Figure 3.6.2: Measurement of Anterior Mediolaral Length.....	13
Figure 3.5.3: Measurement of Posterior Mediolaral Length.....	13
Figure 3.6.3: Measurement of Posterior Mediolaral Length.....	14
Figure 3.6.4: Measurement of Medial Anteroposterior Height .....	14
Figure 3.6.5: Measurement of Lateral Anteroposterior Height.....	15
Figure 4.3.1: Distribution of ML/AP ratios.....	19
Figure 4.3.1: Distribution of AML/PML ratios.....	20
Figure 4.3.1: Distribution of MAP/LAP ratios.....	21

## **ACKNOWLEDGEMENT**

I would like to thank my supervisors Professor El-Badawi M. G. Y., Dr. Ayumba B. R., and Dr. Njoroge, A. N. for their guidance, support and contribution towards this thesis, the late Professor Saidi, H. (from the University of Nairobi) for his guidance during the period of data collection, and Mr. Keter, A. for helping on the statistical aspect of the thesis, and finally my family for their never-ending support during the duration of this thesis.



**ABBREVIATIONS**

<b>AML</b>	Anterior mediolateral length
<b>AP</b>	Anteroposterior height
<b>LAP</b>	Lateral anteroposterior height
<b>MAP</b>	Medial anteroposterior height
<b>ML</b>	Mediolateral width
<b>PML</b>	Posterior mediolateral length
<b>TKA</b>	Total knee arthroplasty

## DEFINITION OF KEY TERMS

**Adult** - A human being of 18 years of age and above

**Anterior mediolateral length of the distal femur** - Distance between the two most anterior aspects of the medial and lateral condyles

**Anteroposterior height of the distal femur** - The distance between the anterior cortex point and the posterior plane of the condyles

**Distal femur** - The medial and lateral condyles

**Lateral anteroposterior height of the distal femur** - Distance between most anterior and posterior aspects of the lateral condyle

**Medial anteroposterior height of the distal femur** - Distance between most anterior and posterior aspects of the medial condyle

**Mediolateral width of the distal femur** - The largest distance between the medial and lateral epicondyles

**Morphology** - This is size, shape and structure of a given body structure

**Posterior mediolateral length of the distal femur** - Distance between the two most posterior aspects of the medial and lateral condyles

## ABSTRACT

**Background:** The morphology of the adult distal femur has been described in geometrical shapes using normalized ratios. The normalized ratios are derived from linear measurements and include the mediolateral/anteroposterior (ML/AP) ratio, the anteromedial/posteromedial (AML/PML) ratio, and the medial anteroposterior/lateral anteroposterior (MAP/LAP) ratio. These ratios define the distal femur as either a square or a rectangle in the ML/AP ratio, triangular or rectangular in the AML/PML ratio, or being parallel in the anterior and posterior condylar axes or not according to the MAP/LAP ratio. These ratios vary among ethnic groups as well as between the male and female gender. The distal femoral components of the total knee arthroplasty (TKA) available globally are based on the morphology of the distal femur of the Caucasian population. These implants have been found to have shortcomings in non-Caucasian populations due to the differences in the morphologies. Currently no data exists on the morphology of the distal femur of the black Kenyan adult population hence no comparison can be made to the commercially available implants of the distal femur in our locality.

**Objective:** To describe the morphology of the black Kenyan adult distal femur.

**Methods:** An anatomical cross-sectional descriptive study of the adult distal femora of prosected cadavers at the human anatomy laboratories of Moi University and University of Nairobi was carried out during the month of October 2015. A sample size of 90 femora was required for the study. Using a pair of digital sliding callipers, the ML width, AML length, PML length, MAP height, and LAP height were measured. The AP height was taken as MAP or LAP depending on which dimension was greater. The ML/AP, AML/PML, and MAP/LAP ratios were then calculated and tabulated. Statistical analysis was computed using the student's t-test and two sample Wilcoxon rank-sum test for parametric and non-parametric data respectively. Two-sample t test was used to compare normalized ratios from this study to those of other races as from literature.

**Results:** A total of 87 femora were studied: 77 were from male cadavers and 10 were from female cadavers. The mean values of the linear measurements were: ML 75.519mm (SD: 5.928mm), AP 69.305mm (SD: 4.686mm), AML 37.815mm (SD: 3.721mm), PML 51.934mm (SD: 5.006mm), MAP 66.301mm (SD: 4.786mm), and LAP 69.146mm (SD: 4.673mm). The mean ML/AP ratio was 1.091 (SD: 0.074), AML/PML ratio 0.733 (SD: 0.089), and MAP/LAP ratio 0.959 (SD: 0.038). The ML/AP ratio of male cadaveric distal femur was significantly greater than that of female cadavers ( $p < 0.001$ ). The male and female black Kenyan distal femora were smaller than the Caucasian distal femora in all the ratios ( $p < 0.05$ ).

**Conclusions:** The black Kenyan adult distal femur is more of a square in the ML/AP ratio; and more triangular than rectangular in AML/PML ratio. The condylar axes are not parallel in the MAP/LAP ratio, and the female distal femur is comparatively narrower than that of males. The black Kenyan distal femur is narrower and shorter than the distal femur of the Caucasian population.

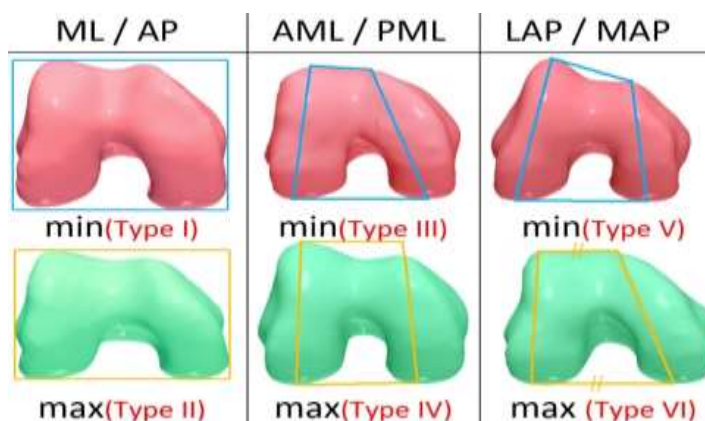
**Recommendation(s):** A study to be done to compare the distal femoral measurements and ratios from this study with the commercially available distal femoral components of TKA. A wide based study to be done to encompass the distal femoral measurements of various communities within Kenya.

## CHAPTER ONE: INTRODUCTION

### 1.1 Background

The distal femur comprises of the medial and lateral condyles which are continuous anteriorly but separated posteriorly by a condylar notch. They articulate anteriorly with the patella at the patellar surface, and inferiorly with the condyles of the tibia to form the knee joint (Standring, S., Borley, N. R., & Gray, H., 2008).

The distal femur has been described in shapes based on the normalized ratios and further subdivided into types. These ratios include the Mediolateral Width/Anteroposterior Height (ML/AP), the Anterior Mediolateral Length/Posterior Mediolateral Length (AML/PML), and the Medial Anteroposterior Height/Lateral Anteroposterior Height (MAP/LAP). The ML/AP ratio describes the femur as either leaning towards a square for those with a ratio nearing 1 (type I) or a rectangle in those with a greater ratio (type II), while the AML/PML ratio describes it as triangular (type III) or rectangular (type IV). The MAP/LAP ratio determines the angle created between the anterior and posterior condylar axes where a ratio of less than 1 means the anterior and posterior condylar axes are not parallel and has a lateral inclination (type V) while a ratio of 1 shows the axes are parallel to each other (type VI) (Mahfouz et al., 2012).



**Figure 1.1: The types of distal femora based on normalized ratios.**

Picture adopted from Mahfouz et al., (2012).

The morphology of the distal femur is essential in helping orthopaedic surgeons understand the causes of osteoarthritis, in sizing distal femur osteotomies and choosing the appropriate sizes of the femoral components during Total Knee Arthroplasty (TKA) procedures (Nagamine et al., 2000; Shepstone et al., 2001; Wada et al., 1999). The use of proper prostheses is crucial in rehabilitation and in the service lives of the prostheses (Longstaff et al., 2009). Also, the morphology of the distal femur is used by implant manufacturers as a basis for the designing and sizing of the distal femur components of TKA (Seedhom et al., 1972).

It is known that the distal femur morphology differs among various races (Chin et al., 2011; Fan et al., 2017; Mahfouz et al., 2012; Shah et al., 2014; Urabe et al., 2008; Yue et al., 2011). Furthermore, the female distal femora have been found to be smaller in the various dimensions and in the normalized ratios than the male distal femora (Cheng et al., 2009; Conley et al., 2007; Fan et al., 2017; Mahfouz et al., 2012; Terzidis et al., 2012; Yang et al., 2014; Yue et al., 2010). Since, the distal femur components of the TKA are based on the morphology of the Caucasian population and are not specific to gender, it has led to a mismatch in the non-Caucasian populations and in the female patients, resulting in implant failure (Bellemans et al., 2010; Cheng et al., 2009; Guy et al., 2012; Hitt et al., 2003; Mahoney and Kinsey, 2010; Shah et al., 2014; Urabe, Mahoney, Mabuchi, & Itoman 2008).

The procedure of replacing the distal femur during TKA entails obtaining appropriate sizing and accurate rotational alignment of the femur component. This is dependent on the referencing system used; anterior or posterior referencing system (Heekin & Fokin, 2013). Complications of implant size mismatch arise postoperatively depending on over- or undersizing of the implant in the anteroposterior (sagittal) and/or in the mediolateral (coronal) plane (Longstaff et al., 2009).

In the anteroposterior plane, oversizing of the femoral component can either cause an overstuffing of the flexion gap, reduced range of motion, and stiffness when using the anterior referencing system. Meanwhile, oversizing of the femoral component in the anteroposterior plane when using the posterior referencing system can lead to overstuffing of the patellofemoral joint, increased patellofemoral pressure, increased pain, and reduced range of motion (Heekin & Fokin, 2013). The reduced range of motion at the knee joint with a maximum flexion of 95° makes functional activities such as rising from a chair and ascending and descending stairs difficult (Ritter & Campbell, 1987; Ritter et al., 2005; Van der Linden, Rowe, Myles, & Nutton, 2006). Undersizing in the anteroposterior plane when using the anterior referencing system to make distal femora cuts leads to instability of the flexion gap and increased wear. Undersizing of the femoral component in the anteroposterior plane after using the posterior referencing system leads to notching of the anterior cortex which reduces the axial and rotational load to failure that can eventually lead to a periprosthetic fracture (Pellegrini et al., 1999). Culp et al., (1987) reported a periprosthetic fracture incidence of 44% after anterior notching during TKAs with 1% as the baseline.

In the coronal plane, the femoral component can overhang due to an oversize, or can underhang due to an undersize. Overhang causes soft tissue impingement which can result in reformation of osteophytes at the distal femur, extrusion of bone cement, formation of fibrous bands intraarticularly, and irritation of knee ligaments and tendons (Dennis et al., 2004). Underhang of the femoral component leads to component loosening, instability, possible medialisation of the trochlea, and increased postoperative haemorrhage (Olcott & Scott, 1999).

There is no local data on the morphology of the black Kenyan adult distal femur, hence, no comparison can be done to the available femoral components of TKAs. If

any complications arise postoperatively due to the difference in the morphologies, they cannot be attributed to implant mismatch without knowledge of the morphology of the black Kenyan adult distal femur.

## **1.2 Problem Statement**

TKA is a commonly performed major orthopaedic procedure in the country. It involves replacing the distal femur, the proximal tibia, and rarely, the articular surface of the patella. The procedure of replacing the distal femur entails fine details in terms of sizing of distal femora osteotomies, achieving rotational alignment and prostheses sizing. Complications following replacement of the distal femur have been documented globally (especially in the female patients). These complications have been attributed to the differences between the femoral component morphology and the morphology of the distal femora of various races. Locally patients have developed postoperative complications such as nonremitting pain and knee joint stiffness as well as implant failure following TKAs. Most of the commercially available TKA implants locally are based on Caucasian populations and are not specific for gender. To the best of our knowledge, there is no data available in Africa on the morphology of the adult distal femur. Knowledge on the morphology of the black Kenyan adult distal femur obtained from this study will help bridge this existing gap.

## **1.3 Justification**

Knowledge on the morphology of the distal femur helps to define it in geometrical shapes using measurements of the dimensions and their calculated normalized ratios. These dimensions and ratios are significant to orthopaedic surgeons in the procedure of replacing the distal femur during TKAs and to implant manufacturers when making the femoral components for TKAs. In the replacement of the distal femur, the AP in-

fluences knee motion and stability by determining the flexion-extension gap, the patellofemoral tracking and tightness in the quadriceps mechanism, while the ML affects the amount of bone coverage and soft tissue tension. The ML/AP ratio is the basis on which femoral components are sized by manufacturers and knowledge of this ratio will help in the manufacture of femoral components suitable for the black Kenyan population. Knowledge on the AML/PML, and MAP/LAP ratios will enrich the morphology of the distal femur further and will also help in comparing the femoral component in all its dimensions.

Moreover, comparison between the distal femur morphologies of the adult male and female from this study will help to show existence of any size differences between the genders in the black Kenyan adult population. This is important as the currently available femoral components are not gender specific and it may be because of this that femoral component overhang occurs frequently in the female population. Hence, knowledge obtained from this study may aid in consideration of gender specific distal femur components of TKA.

#### **1.4 Research question**

What is the morphology of the black Kenyan adult distal femur?

#### **1.5 Objectives**

##### **1.5.1. Broad objective**

To describe the morphology of the black Kenyan adult distal femur

##### **1.5.2. Specific objectives**

- a. To evaluate the ML/AP ratio.
- b. To evaluate the AML/PML ratio.
- c. To evaluate the MAP/LAP ratio.
- d. To describe the size differences between the male and female distal femora.



## **CHAPTER TWO: LITERATURE REVIEW**

### **2.1 The distal femur anatomy**

The distal femur consists of two large masses, the medial and lateral femoral condyles. Anteriorly the two condyles are continuous with each other, but posteriorly are separated by a large gap, the intercondylar notch. The condyles are covered with an inverted-V-shaped articular surface that articulates with the patella and the condyles of the tibia to form the knee joint. The part of the articular surface of the distal femur that articulates with the patella is called the patellar or trochlear surface. The rest of the articular surface forms two strips that extend into the inferior and posterior surfaces of the two condyles (Standring et al., 2008).

The lateral condyle is larger than the medial condyle and lies more so in line with the shaft of the femur. The medial condyle is medially deflected. A slope exists between the two condyles and the vertical plane. The slope is much greater in the medial condyle than in the lateral condyle (Standring et al., 2008).

### **2.2 Variations in the morphology of the distal femur**

The distal femur morphology varies among different races (Chin et al., 2011; Fan et al., 2017; Mahfouz et al., 2012; Shah et al., 2014; Urabe et al., 2008; and Yue et al., 2011). Mahfouz et al., (2012) when comparing the distal femur morphologies of the African Americans, the Caucasians, and the East Asians found the African Americans to have a narrower distal femur than the Caucasians and East Asians. This difference in the morphology of the distal femur was also confirmed in a study done to compare the Chinese and Caucasian distal femora by Yue et al., (2011) which concluded that the distal femora of the Chinese female were smaller and narrower as compared to the distal femora of the Caucasian female; the Chinese female had a smaller distal femur ML/AP ratio when compared to the white female. Also of note was the size difference

in the male distal femora which revealed a significantly smaller ML and AP in the Chinese as compared to the Caucasian. The study however did not find a statistically significant difference in the aspect ratios of the distal femora of the Chinese male when compared with the Caucasian male population. Chin et al., (2011) found the Asian distal femur had a lesser ML/AP ratio than that of the Caucasian distal femur. Shah et al., (2014) also demonstrate that the morphology of the distal femora varies among races, with the Indian population having smaller distal femora as compared to the Caucasian population. Urabe et al., (2008) in their study demonstrate that Japanese women generally have a smaller distal femur than the Caucasian women.

The morphology of the distal femur also varies between gender. Terzidis et al., (2012) showed the Greek distal femur was wider in the male than in the female. Mahfouz et al., (2012) confirmed that gender has an implication on the morphology of the distal femora. Their study showed that the male had significantly larger distal femora as compared to that of the female in the African American, the Caucasian, and East Asians. Studies on the Chinese population have demonstrated a difference in the morphology of the distal femora of the male and female; the male having a wider distal femur (for a particular AP) than that of the female (Cheng et al., 2009; Chin et al., 2011; Fan et al., 2017; Yang et al., 2014; Yue et al., 2010). In another study on the Chinese population, Dargel et al., (2011) also concluded that a significant difference exists between the morphology of the male distal femur and the female distal femur. In a study by Conley S. et al., (2007), it was found that the female population had significant anatomic variations in the distal femora. The variations include “a less prominent anterior condyle, an increased Q angle, and a reduced medial-lateral:anterior-posterior aspect ratio”. In a study to compare the distal femora of male and female, Lonner et al., (2008) found out that a variation occurred between the distal femora of

different sexes, with the females having a smaller mean ML/AP ratio as compared to that of the males. Shah et al., (2014) however found no difference in the ML/AP ratios of the distal femora of the male and female. This shows that the male and female distal femora were of similar width for a particular AP. This was also the case in a study by Gillespie et al., (2011) which did not show a significant difference in the morphology of the distal femora between males and females of the Caucasian population. This was also supported by a study carried out by Merchant et al., (2008) who found no significant difference in the sizes of the distal femora of males and females.

### **2.3 Total Knee Arthroplasty implant mismatch**

Most of the commercially available TKA implants are manufactured based on the morphology of the Caucasian population. And, since the morphologies of the distal femora vary among racial groups, mismatch of the prostheses can occur (Urabe et al., 2008).

Mahoney and Kinsey (2010) found the incidence of clinically relevant pain due to femoral component overhang at 27%, and it was seen that overhang occurs more frequently with a high frequency in the female population. They suggested that a femoral component overhang of more than 3mm approximately doubles the odds of clinically important knee pain two years after TKA. Cheng et al., (2009) found the Chinese population had a femoral prostheses overhang in the mediolateral aspect with all sizes of available prostheses and the femoral component overhang occurred more frequently in the female population. Ho et al., (2006) in their study showed the commercially available femoral components did not match the femora of their population. The implants that were seen to be suitable in the Caucasian population were seen to overhang in the ML of the resected femurs. A study carried out by Guy et al., (2012) showed

that “femoral component overhang can occur in the female population who are undergoing TKR” and they suggested that a sex-specific design for the prosthesis. Hitt et al., (2003) found out in their study on knee prostheses that the femoral component had a wide variation among six different prosthetic systems. Also among the female they found a significant association between the femoral component and the mediolateral overhang; the larger sizes having more overhang. A study by Bellemans et al., (2010) concluded that the knee prostheses should be designed specific to sex due to differences in the size and shape of the distal femur. Shah et al., (2014) in their study concluded that the available prostheses for TKA which are based on the Caucasian population are not suitable for the Indian population. They found that an overhang can occur with the prosthesis in the mediolateral aspect especially for larger anteroposterior dimensions, and also that for smaller anteroposterior dimensions an undersize occurs in the mediolateral aspect.

On the contrary, a study carried out by Merchant et al., (2008) demonstrated a better outcome of TKAs in the female population as compared to the male population. They also concluded that there is no much need for a sex specific implant. This also is supported by Dargel et al., (2011) who concluded that there is no use of coming up with female-specific designs for prostheses.

## **CHAPTER THREE: METHODOLOGY**

### **3.1 Study site**

The study was conducted at the Human Anatomy Laboratories of Moi University, School of Medicine which is based in Eldoret town, and of University of Nairobi which is based in Chiromo, Nairobi.

### **3.2 Study design**

This was an anatomical cross-sectional descriptive study involving the measurements of the various aspects of the distal femur in prosected adult cadaveric specimens at the Human Anatomy departments of both Moi University and University of Nairobi.

### **3.3 Study population**

This study was carried out on adult cadavers at the Human Anatomy laboratories of Moi University and University of Nairobi.

### **3.4 Eligibility criteria**

#### **3.4.1 Inclusion criteria**

All distal femora of the adult cadavers.

#### **3.4.2 Exclusion criteria**

Any distal femur with obvious deformities.

### **3.5 Sampling and Sample size**

The objective of the study was to describe the morphology of the black Kenyan adult distal femur. And to do that, the mediolateral width from a similar study by Mahfouz et al., (2012) was used to estimate the sample size. They found the mean mediolateral width of the distal femora of the African-American male population of 84.9mm (SD: 4.7mm) while that of the female population had a mean of 76.8mm (4.9mm). The researcher assumed the distal femora of the African-American population and the distal femora of the black Kenyan population to be similar with an expected margin of error

( $\delta$ ) of no more than 1.5mm. The margin of error was assumed to be similar among male and female distal femora. The standard deviation ( $\sigma$ ) was rounded off to 5.0. This gave us an estimated sample size of 45 distal femora from the following formula (Cochran, 1963):

$$n = \left( \frac{Z_{1-\frac{\alpha}{2}} \sigma}{\delta} \right)^2$$

$$n = \left( \frac{1.96 \times 5.0}{1.5} \right)^2$$

$$n \approx 45$$

To avoid any side bias, the researcher decided to use both left and right femora and therefore aimed at an aggregate sample of 90 femora; 45 for each side.

### 3.6 Materials and methods

Prosected lower limbs of adult cadavers of both sexes were used. The distal femora were accessed by detaching the cruciate ligaments and soft tissue at the knees by sharp dissection. Direct measurements of the various dimensions of the distal femora were then taken in the various aspects as per the objectives of the study. The reference points for the dimensions measured were adopted from a study by Mahfouz et al., (2012). A pair of digital sliding callipers was used to measure the various lengths of the distal femora as follows:

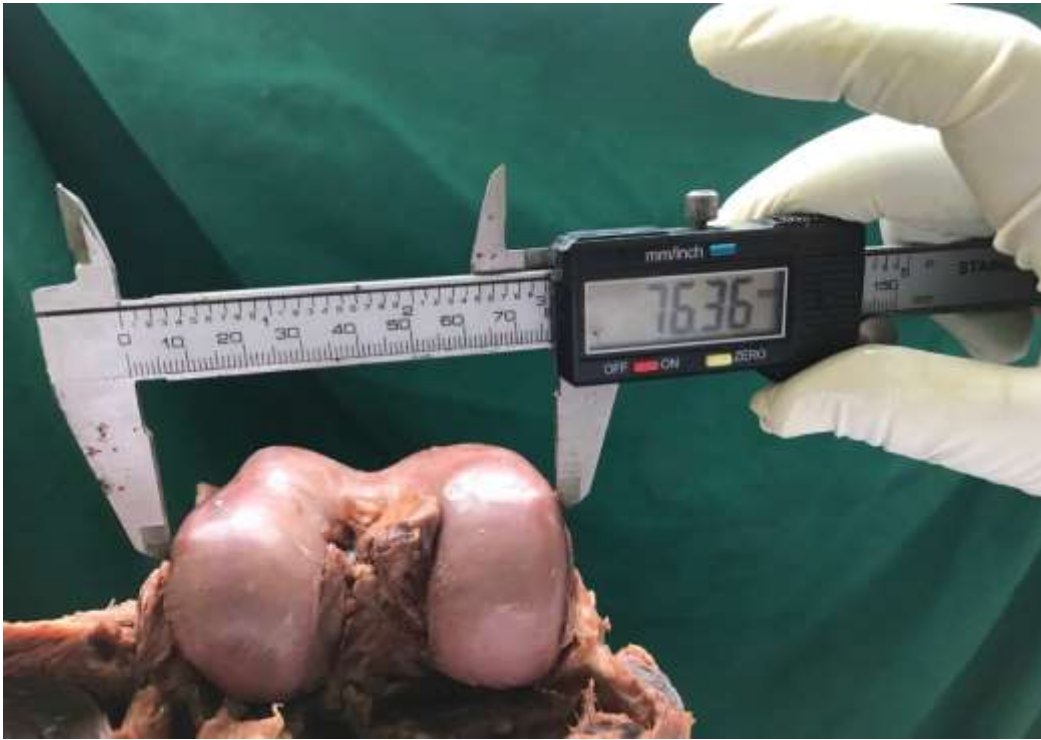1. ML, the largest distance between the medial and lateral epicondyles at the distal femur
2. AP, the distance between the anterior cortex points and the posterior plane, and therefore the MAP or the LAP was used depending which of the two was greater.
3. AML, the distance between the two most anterior aspects of the medial and lateral condyles

4. PML, the distance between the two most posterior aspects of the medial and lateral condyles
5. MAP, the distance between most anterior and posterior aspects of the medial condyle
6. LAP, the distance between most anterior and posterior aspects of the lateral condyle

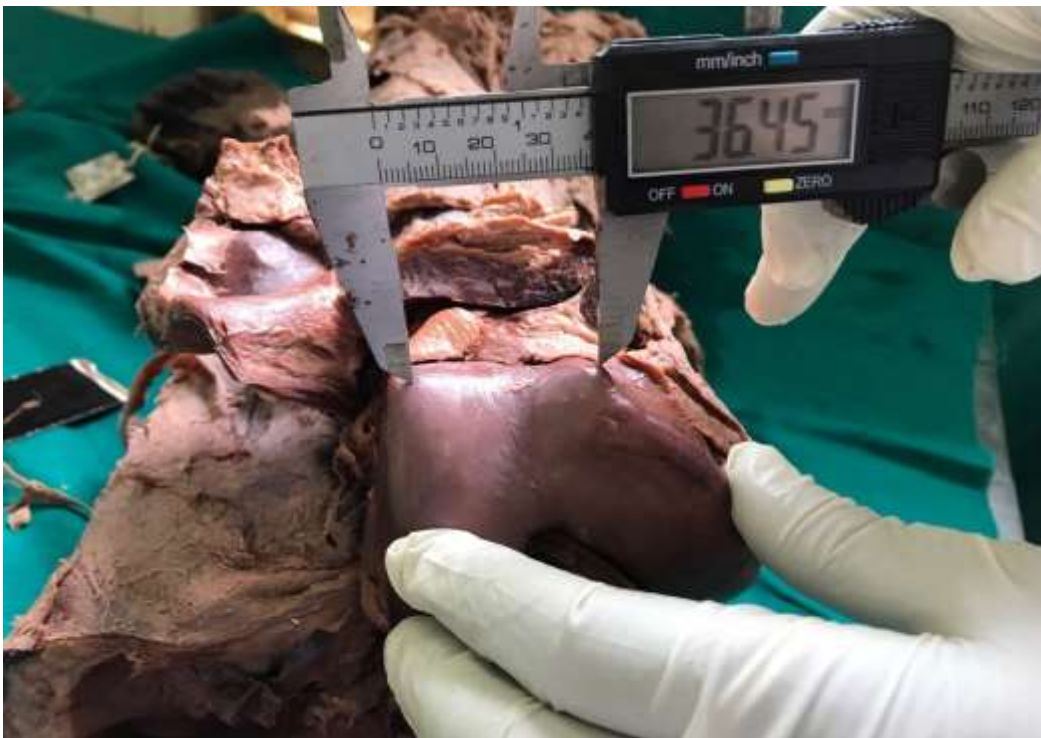These were recorded in a data collection sheet/form.

Ratios were then calculated and recorded as follows:

1. ML/AP
2. AML/PML
3. MAP/LAP

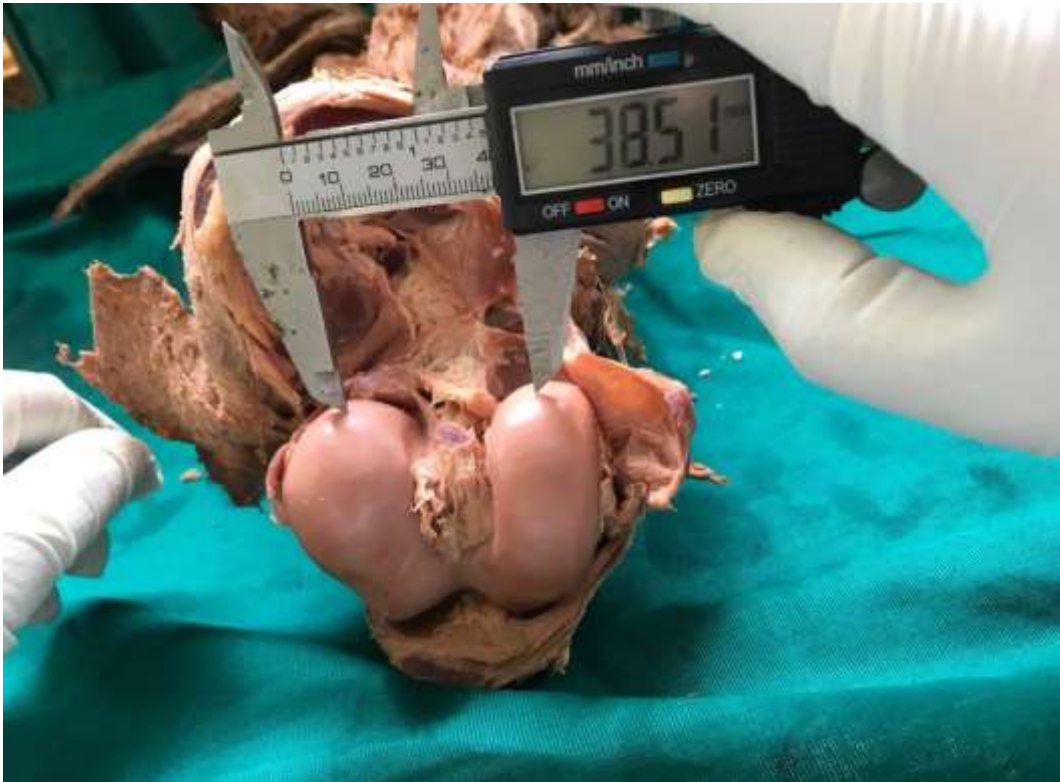

**Figure 3.6.1: Measurement of Mediocranial Width**

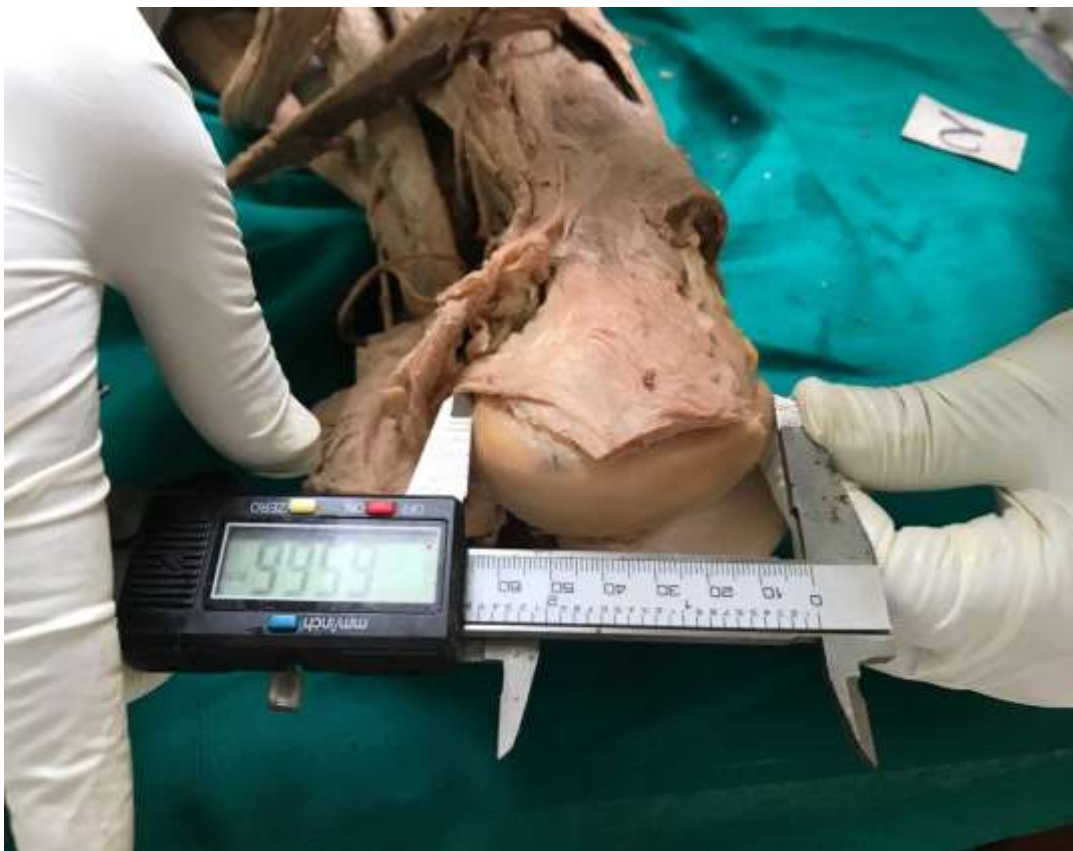

**Figure 3.6.2: Measurement of Anterior Mediocranial Length**

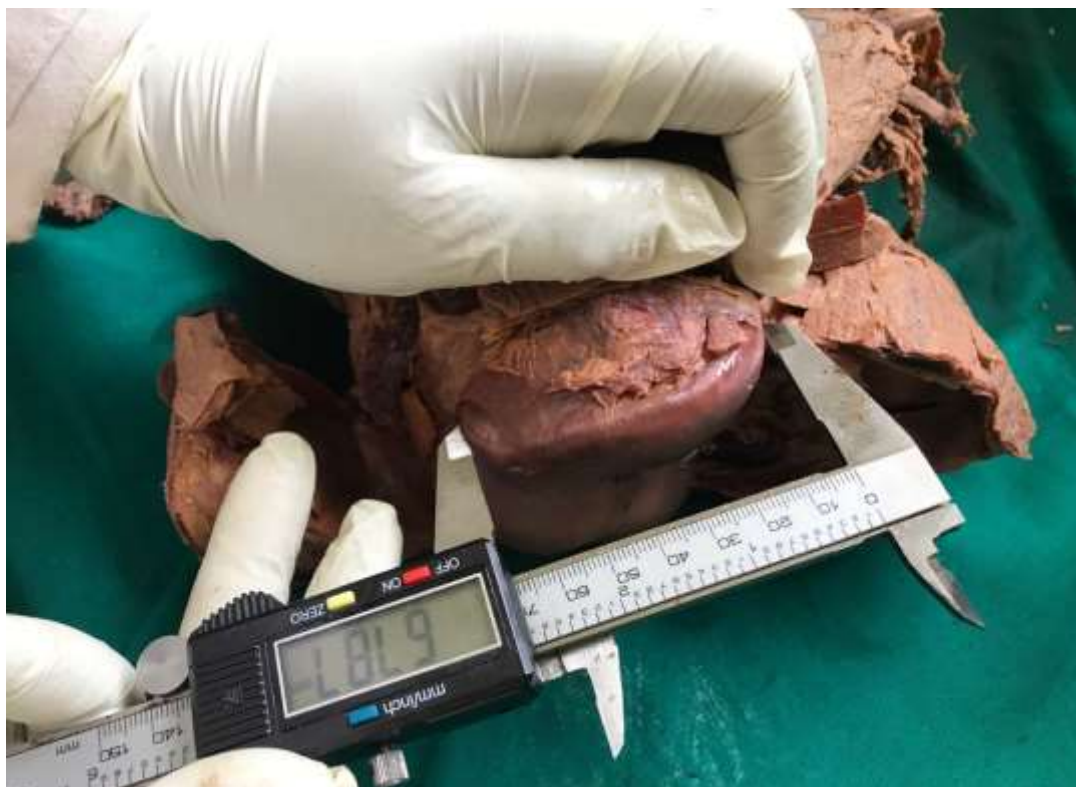



**Figure 3.6.3: Measurement of Posterior Mediolateral Length**



**Figure 3.6.4: Measurement of Medial Anteroposterior Height**



**Figure 3.6.5: Measurement of Lateral Anteroposterior Height**

### **3.7 Data management**

Data was captured using designed forms and subsequently entered into an electronic database. The database was encrypted with a password to ensure confidentiality. The password was accessible only to the Principal Investigator.

### **3.8 Data analysis**

Descriptive statistics for the measures of central tendency such as the mean and the median were used to summarise continuous variables such as the mediolateral width, anteroposterior length, and the ratio of mediolateral width and anteroposterior length among others. Gaussian assumptions for the continuous variables were assessed using box plots. Frequency distributions and the corresponding percentages were used to summarise categorical variables such as gender, and the side of the limb.

The mean differences of the continuous variables between the left distal femur and the right distal femur, and between the male distal femur and the female distal femur were

compared using independent samples t-test, and two sample Wilcoxon rank-sum test respectively. And, the two sample t-test was used to compare means from the black Kenyan adult population to those of other races from the literature.

Data analysis was done using R: A language and environment for statistical computing (R Core Team, 2017).

### **3.9 Ethical considerations**

Ethical approval was sought from the Institution Research and Ethics Committee (IREC) prior to commencement of the study. Formal approval number: IREC 1494 (Appendix 6).

Permission from the Departments of Human Anatomy of both Moi University and University of Nairobi was granted (Appendices 7 and 8).

The study was conducted in accordance to **The Anatomy Act Chapter 249-3 of the Laws of Kenya** which entitles a person registered as a student of any approved school of anatomy to examine cadavers anatomically.

The study results obtained were disseminated through oral defense of the thesis and thereafter presentations at conferences, seminars and publications both locally and internationally.

### **3.10 Study Limitations**

The study had fewer females than males. This therefore limited us to nonparametric statistical testing when comparing the female distal femora to the male distal femora.

## CHAPTER FOUR: RESULTS

### 4.1 Demography

A total of 87 femora, 77 (88.5%) male and 10 (11.5%) female, were studied; 45 (51.7%) were of the left side with 42 (48.3%) being of the right side.

**Table 4.1.1: Distribution of the distal femora by gender and side**

Side	Gender		Total
	Female	Male	
Left	5 (50.0%)	40 (51.9%)	45
Right	5 (50.0%)	37 (48.1%)	42
Total	10	77	87

Of the ten female distal femora, half were from the left side and the other half from the right side. On the other hand, of the 77 male distal femora, 40 (51.9%) were from the left side, and the 37 (48.1%) were from the right side.

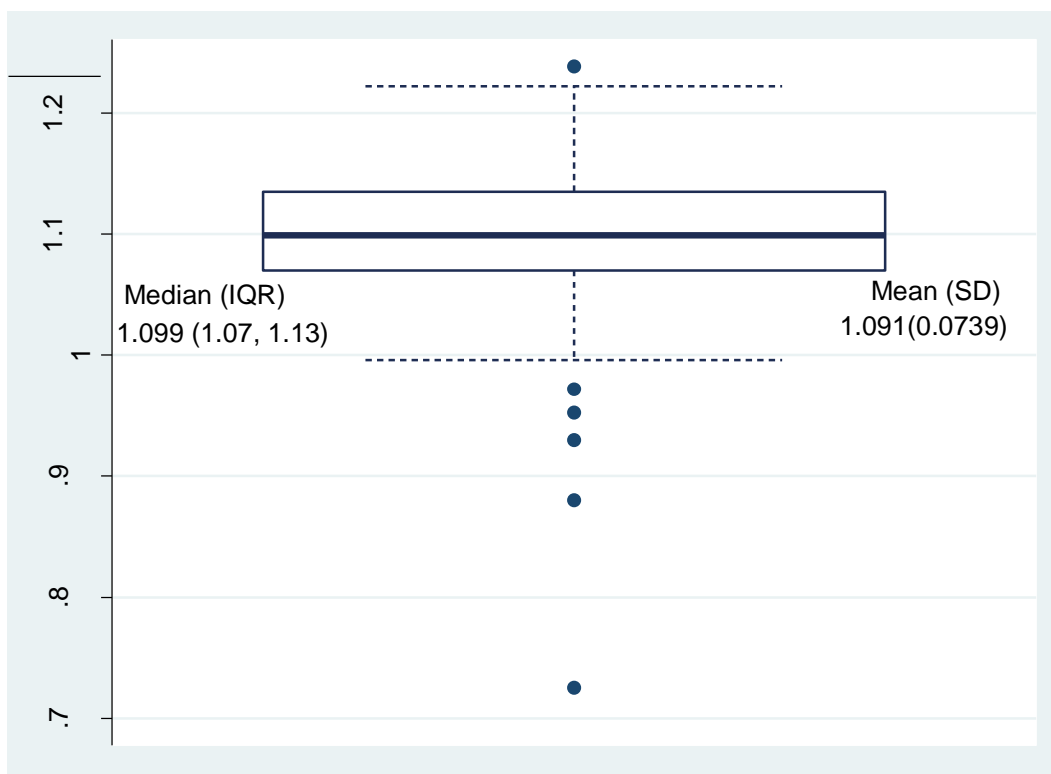
## 4.2 Distal Femora Anatomy

**Table 4.2.1: Descriptive summary of the various dimensions of the distal femora**

<b>Variable</b>	<b>Mean (SD)</b>	<b>Range (Min. – Max.)</b>
Mediolateral width (ML), (mm)	75.519 (5.928)	55.900 – 87.720
Anteroposterior height (AP) , (mm)	69.305 (4.686)	57.030 – 78.370
Anterior mediolateral length (AML) , (mm)	37.815 (3.721)	30.020 – 47.130
Posterior mediolateral length (PML) , (mm)	51.934 (5.006)	40.330 – 64.990
Medial anteroposterior height (MAP) , (mm)	66.301 (4.786)	50.680 – 77.320
Lateral anteroposterior height (LAP) , (mm)	69.146 (4.673)	56.650 – 78.370

The mean values of the various dimensions of the distal femora were as shown in Table 4.2.1.

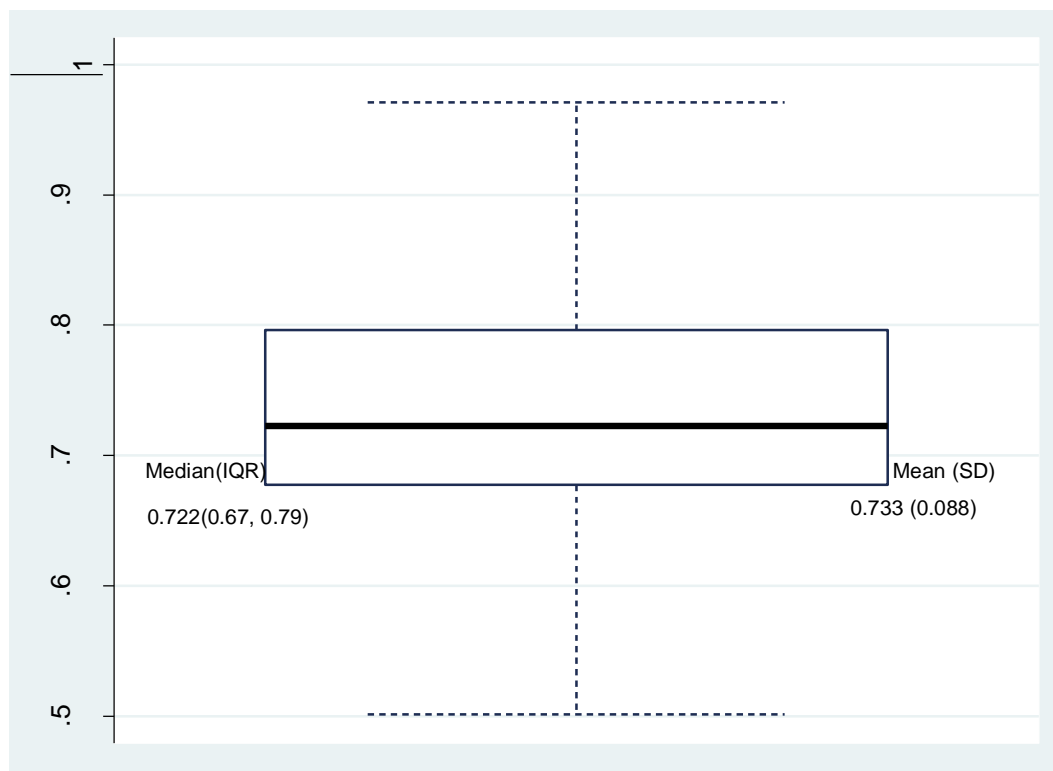### 4.3 ML/AP Ratio



**Figure 4.3.1: Distribution of ML/AP ratios**

The median ratio of ML/AP was 1.099 (IQR: 1.07, 1.13) with a minimum and a maximum of 0.816 and 1.410 respectively. After excluding outliers, the mean ratio of the ML/AP came to 1.091 (SD: 0.0739).

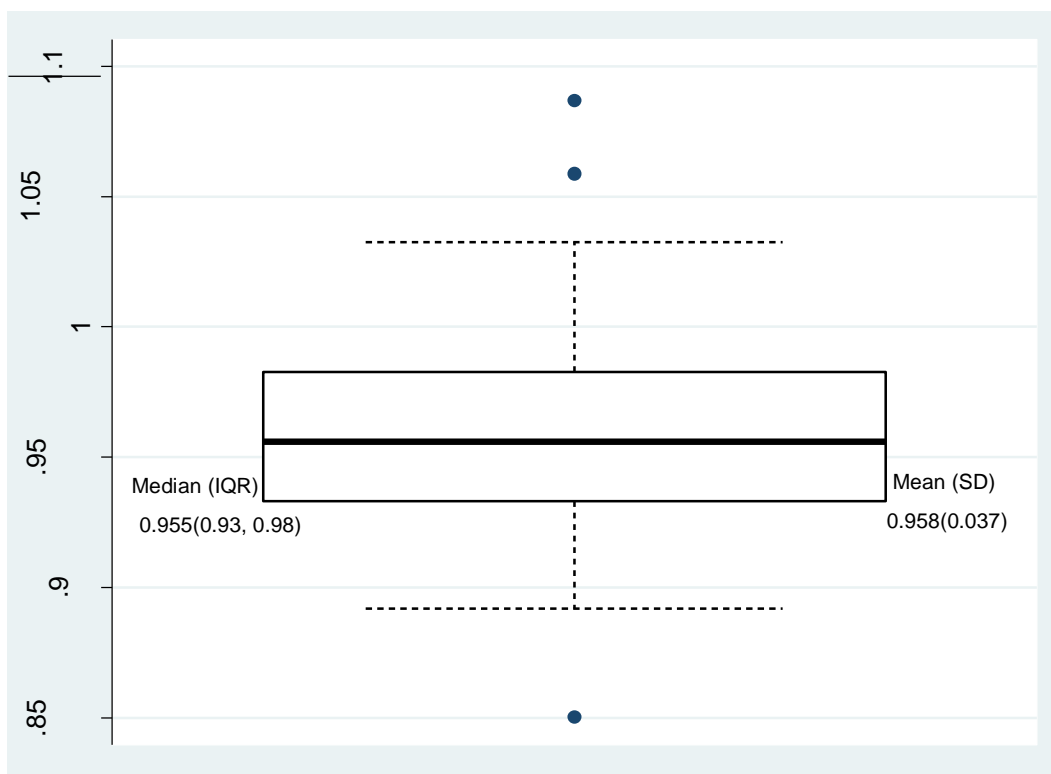
#### 4.4 AML/PML Ratio



**Figure 4.4.1: Distribution of AML/PML ratios**

The mean ratio of AML/PML was 0.733 (SD: 0.089) with a minimum and a maximum of 0.501 and 0.971 respectively. The median ratio was 0.722 (IQR: 0.67, 0.79).

#### 4.5 MAP/LAP Ratio



**Figure 4.5.1: Distribution of MAP/LAP ratios**

The mean ratio of MAP/LAP was 0.958 (SD: 0.037) with a minimum and a maximum of 0.850 and 1.087 respectively. The median ratio was 0.955 (IQR: 0.93, 0.98).



#### 4.6 Differences between Male and Female Distal Femora

**Table 4.6.1: Comparison of the various dimensions and normalized ratios of the distal femora by side of the limb**

	Side		T-test
	Left	Right	P-value
	N = 45	N = 42	
ML, (mm)	74.842 (6.479)	76.245 (5.254)	0.269
Range (Min. – Max.)	55.900 – 86.500	61.510 – 87.720	
AP, (mm)	69.055 (4.819)	69.574 (4.581)	0.608
Range (Min. – Max.)	57.0300 – 78.370	58.890 – 77.750	
ML/AP	1.086 (0.086)	1.097 (0.057)	0.486
Range (Min. – Max.)	0.724– 1.222	0.952 – 1.238	
AML, (mm)	37.604 (3.811)	38.040 (3.654)	0.587
Range (Min. – Max.)	30.020 – 47.130	30.310 – 46.800	
PML, (mm)	52.756 (4.362)	51.054 (5.533)	0.117
Range (Min. – Max.)	42.800 – 62.700	40.330 – 64.990	
AML/PML	0.717 (0.086)	0.751 (0.089)	0.072
Range (Min. – Max.)	0.501 – 0.937	0.615 – 0.971	
MAP, (mm)	66.302 (5.138)	66.301 (4.441)	0.999
Range (Min. – Max.)	50.680 – 77.320	57.000 – 76.490	
LAP, (mm)	68.882 (4.725)	69.430 (4.658)	0.587
Range (Min. – Max.)	56.650 – 78.370	58.890 – 77.750	
MAP/LAP	0.963 (0.039)	0.956 (0.036)	0.381
Range (Min. – Max.)	0.850 – 1.059	0.892 – 1.087	

There was no evidence of a significant statistical difference in the average measurements of the different dimensions of the distal femora by the side of the limb ( $p > 0.05$ ).

**Table 4.6.2: Comparison of the different dimensions and normalized ratios of the distal femora by gender**

	Gender		Wilcoxon rank-sum test
	Female	Male	P-value
	N = 10	N = 77	
ML, (mm)	63.950 (62.478, 69.698)	77.220 (74.440, 79.190)	<0.001
Range (Min. – Max.)	60.400 – 70.950	55.900 – 87.720	
AP, (mm)	66.82 (59.080, 67.830)	69.630 (67.590, 72.980)	<0.002
Range (Min. – Max.)	57.030 – 70.180	61.110 – 78.370	
ML/AP	1.020 (0.996, 1.044)	1.102 (1.074, 1.140)	<0.001
Range (Min. – Max.)	0.929 – 1.107	0.724 – 1.238	
AML, (mm)	34.785 (31.578, 36.598)	38.510 (35.790, 40.060)	0.002
Range (Min. – Max.)	30.020 – 38.520	30.310 – 47.130	
PML, (mm)	47.940 (45.950, 50.465)	52.670 (49.970, 55.150)	0.010
Range (Min. – Max.)	42.180 – 59.900	40.330 – 64.990	
AML/PML	0.708 (0.673, 0.751)	0.730 (0.681, 0.796)	0.651
Range (Min. – Max.)	0.501 – 0.850	0.527 – 0.971	
MAP, (mm)	61.660 (57.048, 63.240)	66.830 (63.940, 69.470)	0.001
Range (Min. – Max.)	50.680 – 70.000	59.610 – 77.320	
LAP, (mm)	65.615 (59.215, 66.920)	69.630 (67.300, 72.960)	<0.001
Range (Min. – Max.)	56.650 – 70.180	61.110 – 78.370	
MAP/LAP	0.942 (0.928, 0.968)	0.956 (0.939, 0.983)	0.369
Range (Min. – Max.)	0.850 – 1.087	0.892 – 1.059	

The data demonstrate a significant statistical difference in the median ML between the male (Median (IQR): 77.220 (IQR: 74.440, 79.190)) and the female (Median

(IQR): 63.950 (IQR: 62.478, 69.698)) distal femora, p-value <0.001. There was sufficient evidence to attribute the difference to gender rather than due to chance.

The male distal femora had a significantly greater AP compared to the female distal femora, Median (IQR): 69.630 (IQR: 67.590, 72.980) versus 66.820 (IQR: 59.080, 67.830), p-value < 0.002.

Comparison of the median ratio of ML/AP showed that the median ratio was high among the male distal femora compared to the female, 1.102 (IQR: 1.074, 1.140) versus 1.020 (IQR: 0.996, 1.044), p=0.002.

The male distal femora had a significantly greater AML, 38.510 (IQR: 35.790, 40.060), compared to the female distal femora, 34.785 (IQR: 31.578, 36.598), p-value = 0.002.

Similarly, the male distal femora had a significantly greater PML median (IQR) 52.670 (IQR: 49.970, 55.150) compared to the female distal femora, median (IQR): 47.940 (IQR: 45.950, 50.465), p-value = 0.010.

Comparison of the median ratio of AML/PML showed no evidence of a significant statistical difference between the male and the female distal femora, p = 0.651.

The median MAP of the male distal femora was significantly greater than that of the female distal femora, 66.830 (IQR: 63.940, 69.470) versus 61.660 (IQR: 57.048, 63.240), p-value = 0.001. Similarly, the median LAP for the male distal femora was significantly greater than that observed for the female distal femora, 69.630 (IQR: 67.300, 72.960) versus 65.615 (IQR: 59.215, 66.920), p-value < 0.001.

Findings show that the differences in the median ratio of MAP/LAP between the male and the female distal femora were not statistically significant, 0.956 (IQR: 0.939, 0.983) versus 0.942 (IQR: 0.928, 0.968),  $p = 0.369$ .

**Table 4.6.3: Comparison of dimensions and normalized ratios of the left and right female distal femora**

	Female		Wilcoxon rank-sum test
	Left (N = 5)	Right (N = 5)	P-value
ML, (mm)	63.160 (62.250, 69.770)	64.270 (63.630, 69.600)	>0.999
Range (Min. – Max.)	60.400 – 70.950	61.510 – 69.730	
AP, (mm)	66.950 (59.620, 67.830)	66.810 (59.080, 66.830)	0.601
Range (Min. – Max.)	57.030 – 70.180	58.890 – 7.000	
ML/AP	1.013 (1.010, 1.028)	1.041 (0.996, 1.044)	0.754
Range (Min. – Max.)	0.929 – 1.107	0.952 – 1.087	
AML, (mm)	33.720 (30.440, 36.080)	35.850 (33.310, 36.770)	0.531
Range (Min. – Max.)	30.020 – 36.870	31.000 – 38.520	
PML, (mm)	49.280 (47.770, 51.920)	46.580 (43.240, 48.110)	0.210
Range (Min. – Max.)	45.740 – 59.900	42.180 – 50.860	
AML/PML	0.706 (0.666, 0.710)	0.757 (0.692, 0.850)	0.248
Range (Min. – Max.)	0.501 – 0.732	0.666 – 0.850	
MAP, (mm)	62.060 (57.030, 63.600)	61.260 (57.100, 62.160)	>0.999
Range (Min. – Max.)	50.680 – 66.360	57.000 – 70.000	
LAP, (mm)	66.950 (59.620, 67.830)	64.420 (59.080, 66.810)	0.403
Range (Min. – Max.)	56.650 – 70.180	58.890 – 66.830	
MAP/LAP	0.938 (0.927, 0.946)	0.966 (0.930, 0.968)	0.531
Range (Min. – Max.)	0.850 – 1.007	0.917 – 1.087	

There was no evidence of a significant statistical difference between the dimensions and normalized ratios of the left and right female distal femora (p-value > 0.05).

**Table 4.6.4: Comparison of dimensions and normalized ratios of the left and right male distal femora**

	Male		T-test
	Left (N = 40)	Right (N = 37)	P-value
ML, (mm)	76.034 (5.652)	77.664 (3.539)	0.131
Range (Min. – Max.)	55.900 – 86.500	72.150 – 87.720	
AP, (mm)	69.646 (4.435)	70.283 (4.090)	0.515
Range (Min. – Max.)	61.110 – 78.370	62.260 – 77.750	
ML/AP	1.094 (0.085)	1.107 (0.051)	0.449
Range (Min. – Max.)	0.724 – 1.222	0.971 – 1.238	
AML, (mm)	38.127 (3.585)	38.439 (3.587)	0.703
Range (Min. – Max.)	31.460 – 47.130	30.310 – 46.800	
PML, (mm)	52.985 (4.228)	51.710 (5.453)	0.258
Range (Min. – Max.)	42.800 – 62.700	40.330 – 64.990	
AML/PML	0.724 (0.084)	0.749 (0.090)	0.198
Range (Min. – Max.)	0.527 – 0.937	0.615 – 0.971	
MAP, (mm)	67.097 (4.475)	66.949 (3.964)	0.879
Range (Min. – Max.)	60.330 – 77.320	59.610 – 76.490	
LAP, (mm)	69.461 (4.317)	70.271 (4.104)	0.401
Range (Min. – Max.)	61.110 – 78.370	62.260 – 77.750	
MAP/LAP	0.966 (0.036)	0.953 (0.031)	0.086
Range (Min. – Max.)	0.899 – 1.059	0.892 – 1.004	

The findings show no evidence of a significant statistical difference between the various dimensions and normalized ratios between the left and right male distal femora (p-value >0.05).

**Table 4.6.5: Comparison of dimensions and normalized ratios of the left female and left male distal femora**

	Left		Wilcoxon rank-sum test
	Female (N = 5)	Male (N = 40)	P-value
ML, (mm)	63.160 (62.250, 69.770)	76.960 (73.490, 78.928)	0.001
Range (Min. – Max.)	60.400 – 70.950	55.900 – 86.500	
AP, (mm)	66.950 (59.620, 67.830)	69.520 (66.040, 72.615)	0.055
Range (Min. – Max.)	57.030 – 70.180	61.110 – 78.370	
ML/AP	1.013 (1.010, 1.028)	1.103 (1.071, 1.137)	0.025
Range (Min. – Max.)	0.929 – 1.107	0.724 – 1.222	
AML, (mm)	33.720 (30.440, 36.080)	38.515 (34.963, 40.028)	0.016
Range (Min. – Max.)	30.020 – 36.870	31.460 – 47.130	
PML, (mm)	49.280 (47.770, 51.920)	52.535 (50.668, 56.163)	0.200
Range (Min. – Max.)	45.740 – 59.900	42.800 – 62.700	
AML/PML	0.706 (0.666, 0.710)	0.734 (0.668, 0.764)	0.176
Range (Min. – Max.)	0.501 – 0.732	0.527 – 0.937	
MAP, (mm)	62.060 (57.030, 63.600)	66.605 (63.538, 70.060)	0.020
Range (Min. – Max.)	50.680 – 66.360	60.330 – 77.320	
LAP, (mm)	66.950 (59.620, 67.830)	69.475 (66.295, 72.413)	0.063
Range (Min. – Max.)	56.650 – 70.180	61.110 – 78.370	
MAP/LAP	0.938 (0.927, 0.946)	0.960 (0.947, 0.984)	0.120
Range (Min. – Max.)	0.850 – 1.007	0.899 – 1.059	

The median ML for the left male distal femora was significantly greater than that of the left female distal femora, 76.960 (IQR: 73.490, 78.928) versus 63.160 (IQR: 62.250, 69.770), p-value = 0.001. However, the median AP for the left male distal

femora was not significantly greater than that of the left female distal femora, 69.520 (66.040, 72.615) versus 66.950 (59.620, 67.830) respectively, p-value = 0.055.

The median ratio of the ML/AP ratio of the male left distal femora was significantly greater than that of the female distal femora, 1.261 (IQR: 1.198, 1.287) versus 1.162 (1.150, 1.187), p-value = 0.025.

The median AML of the left male distal femora was significantly greater than that of the left female distal femora, 38.515 (IQR: 34.963, 40.028) versus 33.720 (IQR: 30.440, 36.080), p-value = 0.016.

There was no evidence of a significant statistical difference in the median PML between the left male distal femora and the left female distal femora, 52.535 (IQR: 50.668, 56.163) versus 49.280 (IQR: 47.770, 51.920), p-value = 0.200. Furthermore, there was no evidence of a significant statistical difference in the median ratio of AML/PML between the left male distal femora and the left female distal femora, 0.734 (IQR: 0.668, 0.764) versus 0.706 (IQR: 0.666, 0.710) respectively, p-value = 0.176.

The median MAP of the left male distal femora was significantly greater than that of the left female distal femora, 66.605 (IQR: 63.538, 70.060) versus 62.060 (IQR: 57.030, 63.600) respectively, p-value = 0.020.

On the other hand, the median LAP of the left male distal femora was not significantly greater than that of the left female distal femora, 69.475 (IQR: 66.295, 72.413) versus 66.950 (IQR: 59.620, 67.830), p-value = 0.063.

There was no evidence of a significant statistical difference in the median ratio of MAP/LAP between the left male distal femora and the left female distal femora, 0.960 (IQR: 0.947, 0.984) versus 0.938 (IQR: 0.927, 0.946), p-value = 0.120.



**Table 4.6.6: Comparison of the dimensions and normalized ratios of the right female and right male distal femora**

	Right		Wilcoxon rank-sum test
	Female (N = 5)	Male (N = 37)	P-value
ML, (mm)	64.270 (63.630, 69.600)	77.620 (75.420, 79.650)	<0.001
Range (Min. – Max.)	61.510 – 69.730	72.150 – 87.720	
AP, (mm)	66.810 (59.080, 66.830)	69.960 (68.120, 72.980)	0.016
Range (Min. – Max.)	58.890 – 7.000	62.260 – 77.750	
ML/AP	1.041 (0.996, 1.044)	1.100 (1.079, 1.145)	0.003
Range (Min. – Max.)	0.952 – 1.087	0.971 – 1.238	
AML, (mm)	35.850 (33.310, 36.770)	38.050 (36.660, 40.060)	0.052
Range (Min. – Max.)	31.000 – 38.520	30.310 – 46.800	
PML, (mm)	46.580 (43.240, 48.110)	52.700 (48.840, 54.470)	0.020
Range (Min. – Max.)	42.180 – 50.860	40.330 – 64.990	
AML/PML	0.757 (0.692, 0.850)	0.719 (0.688, 0.817)	0.641
Range (Min. – Max.)	0.666 – 0.850	0.615 – 0.971	
MAP, (mm)	61.260 (57.100, 62.160)	67.000 (64.380, 69.200)	0.048
Range (Min. – Max.)	57.000 – 70.000	59.610 – 76.490	
LAP, (mm)	64.420 (59.080, 66.810)	69.960 (68.120, 72.980)	0.004
Range (Min. – Max.)	58.890 – 66.830	62.260 – 77.750	
MAP/LAP	0.966 (0.930, 0.968)	0.953 (0.931, 0.979)	0.892
Range (Min. – Max.)	0.917 – 1.087	0.892 – 1.004	

There was sufficient evidence from the data to show that the right male distal femora had a greater ML when compared to the right female distal femora, 77.620mm (IQR: 75.420, 79.650) versus 64.270mm (IQR: 63.630, 69.600), p-value <0.001.

The median AP of the right male distal femora was significantly greater than that of the right female distal femora, 69.960mm (IQR: 68.120, 72.980) versus 66.810mm (IQR: 59.080, 66.830), p-value = 0.016.

Similarly, the median ratio of ML/AP was significantly greater for the right male distal femora compared to the right female distal femora, 1.100 (IQR: 1.079, 1.145) versus 1.041 (IQR: 0.996, 1.044), p-value = 0.003.

There was no evidence of a significant statistical difference in the median AML between the right male distal femora and the right female distal femora, 38.050 (IQR: 36.660, 40.060) versus 35.850 (IQR: 33.310, 36.770), p-value = 0.052. However, there was evidence from the data showing that the median PML of the right male distal femora was significantly greater than that of the right female distal femora, 52.700 (IQR: 48.840, 54.470) versus 46.580 (IQR: 43.240, 48.110), p-value = 0.020. The median ratio of AML/PML of the right male distal femora was similar to that of the right female distal femora, 0.719 (IQR: 0.688, 0.817) versus 0.757 (IQR: 0.692, 0.850), p-value = 0.641.

The median MAP of the right male distal femora (67.000 (IQR: 64.380, 69.200)) was significantly greater than that of the right female distal femora (61.260 (IQR: 57.100, 62.160)), p-value = 0.048.

Similarly, the median LAP of the right male distal femora (69.960 (IQR: 68.120, 72.980)) was significantly greater than that of the right female distal femora (64.420 (IQR: 59.080, 66.810)), p-value = 0.004.

However, the median ratio of MAP/LAP of the right male distal femora (0.953 (IQR: 0.931, 0.979)) was not significantly different statistically from that of the right female distal femora (0.966 (IQR: 0.930, 0.968)), p-value = 0.892.

#### 4.7 Differences between the black Kenyan distal femora to the distal femora of other ethnicities as per the literature

**Table 4.7.1.1: Comparison of data of black Kenyan distal femora to the African American distal femora**

	Mahfouz et al (2012) African American 80 femora		Current study 87 femora		Two-sample T test p-value	
	Male (n=40)	Female (n=40)	Male (n=77)	Female (n=10)	Male	Female
<b>ML (mm)</b>	84.9 (4.7)	76.8(4.9)	76.8(4.7)	65.5(4.0)	<0.001	<0.001
<b>AP (mm)</b>	61.2 (4.9)	57.4(8.3)	69.9(4.2)	64.3(5.0)	<0.001	0.015
<b>ML/AP</b>	1.39(0.07)	1.38(0.34)	1.10(0.07)	1.02(0.05)	<0.001	0.001
<b>AML(mm)</b>	38.1(3.6)	31.3(3.6)	38.3(3.5)	34.3(3.0)	0.772	0.019
<b>PML (mm)</b>	52.1(5.1)	46.7(4)	52.4(4.8)	48.6(5.0)	0.754	0.207
<b>AML/PML</b>	0.74(0.08)	0.67(0.14)	0.74(0.08)	0.71(0.10)	>0.999	0.400
<b>MAP(mm)</b>	66.9(3.5)	63.9 (6.5)	67.0(4.2)	60.7(5.4)	0.897	0.157
<b>LAP (mm)</b>	71.1(3.5)	64.1 (4.9)	69.9(4.2)	63.7(4.7)	0.124	0.817
<b>MAP/LAP</b>	0.94(0.04)	1 (0.07)	0.96(0.03)	0.95(0.06)	0.002	0.043

The data demonstrates the African American distal femora have a significantly larger ML/AP and MAP/LAP ratios than those of the distal femora of the black Kenyan adult.

**Table 4.7.1.2: Comparison of data of black Kenyan distal femora to the Caucasian distal femora**

	Mahfouz et al (2012) Caucasian 840 femora		Current study 87 femora		Two-sample T test p-value	
	Male (n=500)	Female (n=340)	Male (n=77)	Female (n=10)	Male	Female
<b>ML (mm)</b>	85.9 (4.7)	75.8 (3.3)	76.8(4.7)	65.5(4.0)	<0.001	<0.001
<b>AP (mm)</b>	61.2 (3.6)	55.9 (3.3)	69.9(4.2)	64.3(5.0)	<0.001	<0.001
<b>ML/AP</b>	1.41(0.06)	1.36(0.06)	1.10(0.07)	1.02(0.05)	<0.001	<0.001
<b>AML(mm)</b>	34.4 (3.5)	29.9 (2.9)	38.3(3.5)	34.3(3.0)	<0.001	<0.001
<b>PML (mm)</b>	53.5 (4.2)	46.9 (2.9)	52.4(4.8)	48.6(5.0)	0.036	0.075
<b>AML/PML</b>	0.64(0.07)	0.64(0.06)	0.74(0.08)	0.71(0.10)	<0.001	<0.001
<b>MAP(mm)</b>	65.7(3.7)	59.4(3.3)	67.0(4.2)	60.7(5.4)	0.005	0.230
<b>LAP (mm)</b>	67.8 (4.1)	61.4 (3.2)	69.9(4.2)	63.7(4.7)	<0.001	0.027
<b>MAP/LAP</b>	0.97(0.04)	0.97(0.03)	0.96(0.03)	0.95(0.06)	0.035	0.046

The data shows the Caucasian distal femora have greater normalized ratios than those of the black Kenyan adult distal femora.

**Table 4.7.1.3: Comparison of data of black Kenyan distal femora to the East Asian distal femora**

	Mahfouz et al (2012) East Asian 80 femora		Current study 87 femora		Two-sample T test p-value	
	Male (n=40)	Female (n=40)	Male (n=77)	Female (n=10)	Male	Female
<b>ML (mm)</b>	85.4(4.3)	74.8 (3.3)	76.8(4.7)	65.5(4.0)	<0.001	<0.001
<b>AP (mm)</b>	54.9 (3.3)	50 (4)	69.9(4.2)	64.3(5.0)	<0.001	<0.001
<b>ML/AP</b>	1.56(0.06)	1.5 (0.1)	1.10(0.07)	1.02(0.05)	<0.001	<0.001
<b>AML(mm)</b>	37 (2.9)	31.8 (2.3)	38.3(3.5)	34.3(3.0)	0.046	0.005
<b>PML (mm)</b>	50.9 (5)	44.8 (3.3)	52.4(4.8)	48.6(5.0)	0.116	0.005
<b>AML/PML</b>	0.73(0.07)	0.71(0.05)	0.74(0.08)	0.71(0.10)	0.505	>0.999
<b>MAP(mm)</b>	62.6 (3.8)	56.4 (3)	67.0(4.2)	60.7(5.4)	<0.001	0.001
<b>LAP (mm)</b>	64.8 (4.4)	57.8 (3.2)	69.9(4.2)	63.7(4.7)	<0.001	<0.001
<b>MAP/LAP</b>	0.97(0.03)	0.98(0.03)	0.96(0.03)	0.95(0.06)	0.089	0.028

The data demonstrates the East Asian distal femora have a greater ML/AP ratio than those of the black Kenyan adult distal femora. Also, the female East Asian distal femur has a greater MAP/LAP ratio when compared to the MAP/LAP ratio of the female black Kenyan adult distal femur.

**Table 4.7.2: Comparison of data of black Kenyan distal femora to the Southeastern Chinese distal femora**

	Fan et al., (2017) Southeastern Chinese 245 femora		Current study 87 femora		Two-sample T test p-value	
	Male (n=114)	Female (n=131)	Male (n=77)	Female (n=10)	Male	Female
<b>ML (mm)</b>	80.6(3.2)	71.2 (3.4)	76.8(4.7)	65.5(4.0)	<0.001	<0.001
<b>AP (mm)</b>	63.6 (3.7)	57.8 (3.9)	69.9(4.2)	64.3(5.0)	<0.001	<0.001
<b>ML/AP</b>	1.27(0.07)	1.23(0.07)	1.10(0.07)	1.02(0.05)	<0.001	<0.001
<b>AML (mm)</b>	38.6 (2.6)	33.8 (2.3)	38.3(3.5)	34.3(3.0)	0.497	0.518
<b>PML (mm)</b>	51.8 (3.5)	46.3 (3.0)	52.4(4.8)	48.6(5.0)	0.319	0.028
<b>AML/PML</b>			0.74(0.08)	0.71(0.10)		
<b>MAP (mm)</b>	64.9 (3.5)	59.6 (3.6)	67.0(4.2)	60.7(5.4)	<0.001	0.371
<b>LAP (mm)</b>	64.0 (3.8)	58.3 (3.9)	69.9(4.2)	63.7(4.7)	<0.001	<0.001
<b>MAP/LAP</b>	1.02(0.03)	1.03 (0.04)	0.96(0.03)	0.95(0.06)	<0.001	<0.001

The data demonstrates the Southeastern Chinese distal femora have significantly greater ML/AP and MAP/LAP ratios than the distal femora of the black Kenyan adult.

**Table 4.7.3: Comparison of data of black Kenyan distal femora to the Chinese distal femora**

	Cheng et al., (2009) Chinese 172 femora		Current study 87 femora		Two-sample T test p-value	
	Male (n=94)	Female (n=78)	Male (n=77)	Female (n=10)	Male	Female
<b>ML (mm)</b>	74.4(2.9)	66.8(3.1)	76.8(4.7)	65.5(4.0)	<0.001	0.230
<b>AP (mm)</b>	66.6(2.4)	61.0(2.7)	69.9(4.2)	64.3(5.0)	<0.001	0.001
<b>ML/AP</b>	1.12(0.03)	1.09(0.04)	1.10(0.07)	1.02(0.05)	0.013	<0.001

The data shows the distal femora of the Chinese population have a significantly greater ML/AP than the ML/AP of the black Kenyan adult distal femora.

**Table 4.7.4: Comparison of data of black Kenyan distal femora to the Indian distal femora**

	Shah et al., (2014) Indian 66 femora		Current study 87 femora		Two-sample T test p-value	
	Male (n=14)	Female (n=52)	Male (n=77)	Female (n=10)	Male	Female
<b>ML(mm)</b>	71.5(2.5)	65.1 (3.1)	76.8(4.7)	65.5(4.0)	<0.001	0.722
<b>AP(mm)</b>	65.6(3.8)	59.8 (4.3)	69.9(4.2)	64.3(5.0)	<0.001	0.004
<b>ML/AP</b>	1.09(0.04)	1.09 (0.05)	1.10(0.07)	1.02(0.05)	0.605	<0.001

The data demonstrates the Indian distal femora have a similar ML/AP to that of the male black Kenyan distal femur. The distal femur of the female black Kenyan distal femur has a significantly smaller ML/AP than the ML/AP of the Indian distal femora.

## CHAPTER FIVE: DISCUSSION

### 5.1 ML/AP Ratio

The black Kenyan adult population from this study had a mean ML/AP ratio of 1.091 (SD: 0.0739) showing their distal femur is more of a square in this aspect. The mean ML was 75.519mm and the mean AP was 69.305mm. The male population had a mean ML/AP ratio of 1.10 with the mean ML and AP of 76.80mm and 69.90mm respectively. On the other hand, the female population had a mean ML/AP ratio of 1.02; their mean ML was 65.50mm and their mean AP was 64.30mm.

Shah et al., (2014) studied the Indian knees and found the Indian distal femur to have an ML/AP ratio of 1.09. This ratio was in agreement with what was found in this study. However, their mean ML and AP were much smaller than what was found in the black Kenyan population in this study showing the Indian distal femur to be generally smaller to the distal femur of the black Kenyan. The Indian male distal femur was of similar size in the ML/AP ratio to the male black Kenyan distal femur from this study, while the female Indian distal femur was significantly greater than the distal femur of the female black Kenyan in the same ML/AP ratio. As opposed to the normal distal femora used in this study, they studied arthritic knees of patients undergoing TKAs, and used CT scan images to get their measurements.

In another similar study, Fan et al., (2017) found the Chinese distal femur to have a greater ML/AP ratio (1.249) than that of the black Kenyan in this study. This shows the Chinese population to have a significantly wider distal femur for a particular AP height. Their male population had a mean ML/AP ratio of 1.27, with the mean ML and AP of 80.60mm and 63.60mm respectively. This ratio is significantly greater than that of the distal femur of the male black Kenyan population from this study. Also, the Chinese female distal femur is significantly wider than the distal femur of the female

black Kenyan with ML/AP ratios of 1.23 and 1.03 respectively. Another study on the Chinese population by Cheng et al., (2009) found the Chinese distal femur to have a ML/AP ratio of 1.11. This is much smaller than what was found by Fan et al., (2017) in their study; this may be attributed to the measurements taken by Cheng et al., (2009) on resected distal femora as opposed to the normal knees studied by Fan et al., (2017). The ratios obtained by Cheng et al., (2009) are still significantly greater than the distal femur of the black Kenyan in both the male and female populations from this study.

Mahfouz et al., (2012) compared morphologies of the distal femora among the African American, Caucasian and East Asian populations. They found that the African American population had a mean ML/AP ratio of 1.385; the male distal femur had a mean ratio of 1.39, while the female distal femur had a mean ratio of 1.38. These ratios are significantly greater than those of the male and female black Kenyan distal femora, showing the African American population to have a wider distal femur than the distal femur of the black Kenyan population from this study. The Caucasian and the East Asian population had a mean ML/AP ratio of 1.39 and 1.53 respectively. Again, both these populations have significantly greater ratios, hence, wider distal femora than the distal femur of the black Kenyan population from this study. The study by Mahfouz et al., (2012) focused on nonpathologic knees of cadavers similar to this study, however, they used CT and MRI as tools to collect their data.

In their study of distal femora of the Greek Caucasian population, Terzidis et al., (2012) found the ML of 83.9mm on average. This measurement was larger, hence, not in agreement with what was found in this study. Their study made use of similar reference points to what was used in this study. However, they used dried bones as compared to the wet bones used in this study.

## 5.2 AML/PML Ratio

In this study, the black Kenyan population had a mean AML/PML ratio of 0.733 (SD: 0.089); the mean AML was 37.815mm and the mean PML was 51.934mm. The males had a mean AML/PML ratio of 0.74, while the females had a mean ratio of 0.71. This shows that the black Kenyan distal femur is more triangular than rectangular in this aspect in both the male and female populations in this study.

Mahfouz et al., (2012), found the mean AML/PML ratios of the African American male and female as 0.74 and 0.67 respectively, as well as those of the East Asian male and female population as 0.73 and 0.71 respectively. These ratios are in agreement with what was found in the black Kenyan population. However, from the same study, the AML/PML ratios of the male and female Caucasian population (with means of 0.64 and 0.64) are significantly smaller than those of the male and female black Kenyan population. This shows that the male and female Caucasian distal femora in the AML/PML aspect are more triangular than those of the black Kenyan population from this study.

Fan et al., (2017) found the mean AML/PML ratios of 0.745 and 0.73 in the male and female Southeastern Chinese population respectively. These ratios concur with what was found in this study. Also, their mean lengths were similar except for the mean PML in the female population which is significantly smaller than the mean PML of the female black Kenyan population.



### 5.3 MAP/LAP Ratio

From this study the mean MAP/LAP ratio of the black Kenyan distal femur was 0.958 (SD: 0.037); the mean MAP was 66.301mm while the mean LAP was 69.146mm. The mean MAP/LAP of the male and female distal femora from this study were 0.96 and 0.95 respectively. This shows the anterior and posterior condylar axes of the black Kenyan adult distal femur are not parallel and that the distal femur has a lateral inclination.

Mahfouz et al., (2012) found the distal femora of the African American male and female population to have mean MAP/LAP ratios of 0.94 and 1.00 respectively. The male African American MAP/LAP ratio is significantly smaller than that of the black Kenyan male showing that the male African American distal femur has a greater laterally inclined condylar angle. As for the female population, the MAP/LAP ratio of the African American is significantly greater than that of the female of the black Kenyan population from this study. This shows the female African American distal femur has parallel condylar axes whereas the female black Kenyan distal femur has a laterally inclined condylar angle. In the same study, Mahfouz et al., (2012) found significantly greater mean MAP/LAP ratios among distal femora of the females of Caucasian and East Asian populations (0.97 and 0.98 respectively) as compared to that of the female black Kenyan distal femur from this study. Unlike their female counterparts, the male distal femora of the Caucasian and East Asian populations have comparable MAP/LAP mean ratios to the male black Kenyan distal femur at 0.97 for both. This shows that the female distal femora of the Caucasian and East Asian populations have a lesser condylar axes angle though inclined laterally when compared to the distal femur of the female black Kenyan from this study.

Fan et al., (2017) found the mean MAP/LAP ratios of 1.02 and 1.03 in the male and

female Southeastern Chinese population respectively. These ratios are significantly greater than those of the males and females of the black Kenyan population which means that the condylar angle of the distal femur of the Southeastern Chinese population is medially inclined unlike that of the black Kenyan femora from this study.

In a similar study, Terzidis et al., (2012) found the mean MAP/LAP ratio as 1.003 in the Greek Caucasian population. This contrasts to what was found in the black Kenyan population from this study.

#### **5.4 Differences between Male and Female**

In this study it was found that the black Kenyan male distal femora were statistically larger than the female distal femora in all dimensions measured. The male distal femora were found to have a significantly larger ML/AP ratio with a median of 1.202 than those of the female whose median ML/AP ratio was 1.020. Therefore, the black Kenyan male distal femora are wider than the female distal femora of the same AP height. Otherwise, no significant difference was found in the AML/PML and MAP/LAP ratios between the male and female distal femora.

Mahfouz et al., (2012) in their study found that the male distal femora were wider than the female distal femora in the ML/AP aspect in the African American, Caucasian, and Eastern Asian populations. This is in agreement to what was found in this study. This was also true for the Greek Caucasian distal femur where Terzidis et al., (2012) found the male distal femora to be wider than those of the female.

Shah et al., (2014) found that the Indian population had bigger male distal femora than the female distal femora in linear dimensions, but found no difference in the ML/AP ratio between the male and female distal femora. This was contrary to what was found in this study.

Gillespie et al., (2011) on their study of dried femora found no significant difference between the male and female distal femora of the African and Caucasian populations. Merchant et al., (2008) after reviewing articles of TKAs done using implants nonspecific to gender found no difference in outcomes in males and females, therefore, concluded that there is no difference in the morphology of the distal femur of the male and female.

## CHAPTER SIX: CONCLUSIONS AND RECOMMENDATIONS

### 6.1 Conclusions

The ML/AP ratio of the black Kenyan adult distal femur was 1.091. This shows that it was more of a square in that aspect.

The AML/PML ratio of the black Kenyan adult distal femur was 0.733. This confirms that the distal femur of the black Kenyan adult population was triangular with the base being the posterior condylar plane and the apex beyond the anterior condylar plane.

The MAP/LAP ratio of the black Kenyan adult distal femur was 0.959 which shows that the condylar axes are not parallel, and had a laterally inclined condylar angle.

The male black Kenyan adult distal femur was greater in all dimensions and was wider than the female black Kenyan distal femur for a particular AP.

## **6.2 Recommendations**

A study to be conducted to compare the morphology of the black Kenyan distal femur from this study to the commercially available femoral components of TKA.

A wide based study to be conducted on the morphology of the distal femora of other communities within Kenya.

## REFERENCES

- Belleman, J., Carpentier, K., Vandenuecker, H., Vanlauwe, J., & Victor, J. (2010). The John Insall Award: both morphotype and gender influence the shape of the knee in patients undergoing TKA. *Clinical Orthopaedics and Related Research*, 468(1), 29.
- Cheng, F. B., Ji, X. F., Lai, Y., Feng, J. C., Zheng, W. X., Sun, Y. F., ... & Li, Y. Q. (2009). Three dimensional morphometry of the knee to design the total knee arthroplasty for Chinese population. *The Knee*, 16(5), 341-347.
- Chin, P. L., Tey, T. T., Ibrahim, M. Y. B., Chia, S. L., Yeo, S. J., & Lo, N. N. (2011). Intraoperative morphometric study of gender differences in Asian femurs. *The Journal of arthroplasty*, 26(7), 984-988.
- Cochran, W. G. (2007). *Sampling techniques* (2<sup>nd</sup> ed.) New York : John Wiley & Sons.
- Conley, S., Rosenberg, A., & Crowninshield, R. (2007). The female knee: anatomic variations. *JAAOS-Journal of the American Academy of Orthopaedic Surgeons*, 15, S31-S36.
- Culp, R. W., Schmidt, R. G., Hanks, G., Mak, A., Esterhai, J. J., & Heppenstall, R. B. (1987). Supracondylar fracture of the femur following prosthetic knee arthroplasty. *Clinical orthopaedics and related research*, (222), 212-222.
- Dargel, J., Michael, J. W., Feiser, J., Ivo, R., & Koebeke, J. (2011). Human knee joint anatomy revisited: morphometry in the light of sex-specific total knee arthroplasty. *The Journal of arthroplasty*, 26(3), 346-353.
- Dennis, D. A. (2004). Evaluation of painful total knee arthroplasty. *The Journal of arthroplasty*, 19(4), 35-40.
- Fan, L., Xu, T., Li, X., Zan, P., & Li, G. (2017). Morphologic features of the distal femur and tibia plateau in Southeastern Chinese population: A cross-sectional study. *Medicine*, 96(46).
- Fokin, A. A., & Heekin, R. D. (2014). Anterior referencing versus posterior referencing in total knee arthroplasty. *The journal of knee surgery*, 27(04), 303-308.
- Gillespie, R. J., Levine, A., Fitzgerald, S. J., Kolaczko, J., DeMaio, M., Marcus, R. E., & Cooperman, D. R. (2011). Gender differences in the anatomy of the distal femur. *The Journal of bone and joint surgery. British volume*, 93(3), 357-363.
- Gray, H., & Standring, S. (2008). *Gray's anatomy: the anatomical basis of clinical practice*: Philadelphia, St. Louis and New York. Churchill Livingstone.
- Guy, S. P., Farndon, M. A., Sidhom, S., Al-Lami, M., Bennett, C., & London, N. J. (2012). Gender differences in distal femoral morphology and the role of gender specific implants in total knee replacement: a prospective clinical study. *The Knee*, 19(1), 28-31.

- Hitt, K., Shurman, J. R., Greene, K., McCarthy, J., Moskal, J., Hoeman, T., & Mont, M. A. (2003). Anthropometric Measurements Of The Human Knee. *The Journal of Bone and Joint Surgery-American Volume*, 85, 115-122.
- Ho, W. P., Cheng, C. K., & Liao, J. J. (2006). Morphometrical measurements of resected surface of femurs in Chinese knees: correlation to the sizing of current femoral implants. *The Knee*, 13(1), 12-14.
- Longstaff, L. M., Sloan, K., Stamp, N., Scaddan, M., & Beaver, R. (2009). Good Alignment After Total Knee Arthroplasty Leads to Faster Rehabilitation and Better Function. *The Journal of Arthroplasty*, 24(4), 570-578.
- Lonner, J. H., Jasko, J. G., & Thomas, B. S. (2008). Anthropomorphic differences between the distal femora of men and women. *Clinical Orthopaedics and Related Research*, 466(11), 2724-2729.
- Mahfouz, M., Abdel Fatah, E. E., Bowers, L. S., & Scuderi, G. (2012). Three-dimensional morphology of the knee reveals ethnic differences. *Clinical Orthopaedics and Related Research*, 470(1), 172-185.
- Mahoney, O. M., & Kinsey, T. (2010). Overhang of the Femoral Component in Total Knee Arthroplasty: Risk factors and Clinical Consequences. *The Journal of Bone and Joint Surgery-American Volume*, 92(5), 1115-1121.
- Merchant, A. C., Arendt, E. A., Dye, S. F., Fredericson, M., Grelsamer, R. P., Leadbetter, W. B., . . . Teitge, R. A. (2008). The Female Knee: Anatomic Variations and the Female-specific Total Knee Design. *Clinical Orthopaedics and Related Research*, 466(12), 3059-3065.
- Nagamine, R., Miura, H., Bravo, C. V., Urabe, K., Matsuda, S., Miyanshi, K., . . . Iwamoto, Y. (2000). Anatomic variations should be considered in total knee arthroplasty. *Journal of Orthopaedic Science*, 5(3), 232-237.
- Olcott, C. W., & Scott, R. D. (1999). Femoral Component Rotation During Total Knee Arthroplasty. *Clinical Orthopaedics and Related Research*, 367.
- Pellegrini, V. D., Schneider, D. J., Deol, G. S., Jacobs, C., & Lesh, M. L. (1999). Paper #40 The consequences of anterior femoral notching in total knee arthroplasty – a biomechanical study. *The Journal of Arthroplasty*, 14(2), 256-257
- R Core Team (2017). R: A language and environment for statistical computing. R Vienna, Austria: Foundation for Statistical Computing. URL <https://www.R-project.org/>.
- Ritter, M. A., & Campbell, E. D. (1987). Effect of range of motion on the success of a total knee arthroplasty. *The Journal of Arthroplasty*, 2(2), 95-97.
- Ritter, M. A., Thong, A. E., Keating, E. M., Faris, P. M., Meding, J. B., Berend, M. E., . . . Davis, K. E. (2005). The effect of femoral notching during total knee arthroplasty on the prevalence of postoperative femoral fractures and on clinical outcome. *The Journal of Bone and Joint Surgery-American Volume*, 87(11), 2411-2414.

- Seedhom, B. B., Longton, E. B., Wright, V., & Dowson, D. (1972). Dimensions of the knee. Radiographic and autopsy study of sizes required by a knee prosthesis. *Annals of the Rheumatic Diseases*, 31(1), 4-58.
- Shah, D. S., Ghyar, R., Ravi, B., Hegde, C., & Shetty, V. (2014). Morphological Measurements of Knee Joints in Indian Population: Comparison to Current Knee Prostheses. *Open Journal of Rheumatology and Autoimmune Diseases*, 04(02), 75-85.
- Shepstone, L. (2001). Shape of the intercondylar notch of the human femur: a comparison of osteoarthritic and non-osteoarthritic bones from a skeletal sample. *Annals of the Rheumatic Diseases*, 60(10), 968-973.
- Standring, S., & Anatomy, G. H. G. S. (2008). The anatomical basis of clinical practice. London, England: *Churchill Livingstone*.
- Terzidis, I., Totlis, T., Papathanasiou, E., Sideridis, A., Vlasis, K., & Natsis, K. (2012). Gender and Side-to-Side Differences of Femoral Condyles Morphology: Osteometric Data from 360 Caucasian Dried Femori. *Anatomy Research International*, 2012, 1-6.
- Urabe, K., Mahoney, O. M., Mabuchi, K., & Itoman, M. (2008). Morphologic differences of the distal femur between Caucasian and Japanese women. *Journal of Orthopaedic Surgery*, 16(3), 312-315.
- Wada, M., Tatsuo, H., Baba, H., Asamoto, K., & Nojyo, Y. (1999). Femoral intercondylar notch measurements in osteoarthritic knees. *Rheumatology*, 38(6), 554-558.
- Yang, B., Yu, J. K., Zheng, Z. Z., Lu, Z. H., & Zhang, J. Y. (2014). Comparative study of sex differences in distal femur morphology in osteoarthritic knees in a Chinese population. *PLoS One*, 9(2), e89394.
- Yue, B., Varadarajan, K. M., Ai, S., Tang, T., Rubash, H. E., & Li, G. (2010). Gender differences in the knees of Chinese population. *Knee Surgery, Sports Traumatology, Arthroscopy*, 19(1), 80-88.
- Yue, B., Varadarajan, K. M., Ai, S., Tang, T., Rubash, H. E., & Li, G. (2011). Differences of knee anthropometry between Chinese and white men and women. *The Journal of Arthroplasty*, 26(1), 124-130.



## **APPENDICES**

### **Appendix 1: Equipment and instruments**

1. Measuring instruments: Digital sliding Vernier calipers.
2. Digital camera
3. Stationery
4. Gloves
5. Printer
6. Laptop
7. Flashdisks

**Appendix 2: Data collection form/sheet**

Date	
Identification code	
Sex	Male <input type="checkbox"/> Female <input type="checkbox"/>
Side	Right <input type="checkbox"/> Left <input type="checkbox"/>
ML (mm )	
AP (mm )	
AML (mm )	
PML (mm )	
MAP (mm )	
LAP (mm )	

**Appendix 3: Budget**

<b>ITEM</b>	<b>AMOUNT (KSH )</b>
Digital camera	15,000.00
Digital sliding Vernier calipers	2,000.00
Transport	20,000.00
Printing and binding services	10,000.00
Flash disks	5,000.00
Stationery	5,000.00
Data handling	40,000.00
Airtime	5,000.00
Allowance for research assistants	10,000.00
Contingencies ( 10% of total cost )	11,200.00
<b>Total</b>	<b>123,200.00</b>

**Appendix 4: Work Plan**

<b>ACTIVITY</b>	<b>START</b>	<b>END</b>
Proposal Writing	January 2015	April 2015
Presentation of proposal to the Orthopaedics department	May 2015	June 2015
IREC Review	July 2015	August 2015
Collection of data	September 2015	October 2015
Data analysis	January 2016	March 2016
Thesis writing and presentation to Orthopaedic department	April 2016	July 2017
Presentation of Thesis School of Medicine for Examination purposes and Defense	September 2019	October 2019
Submission of Bound Thesis	October 2019	

**Appendix 5: Figure of the distal femur**

The picture shows the various lengths of the distal femur of an adult that were measured during the study.

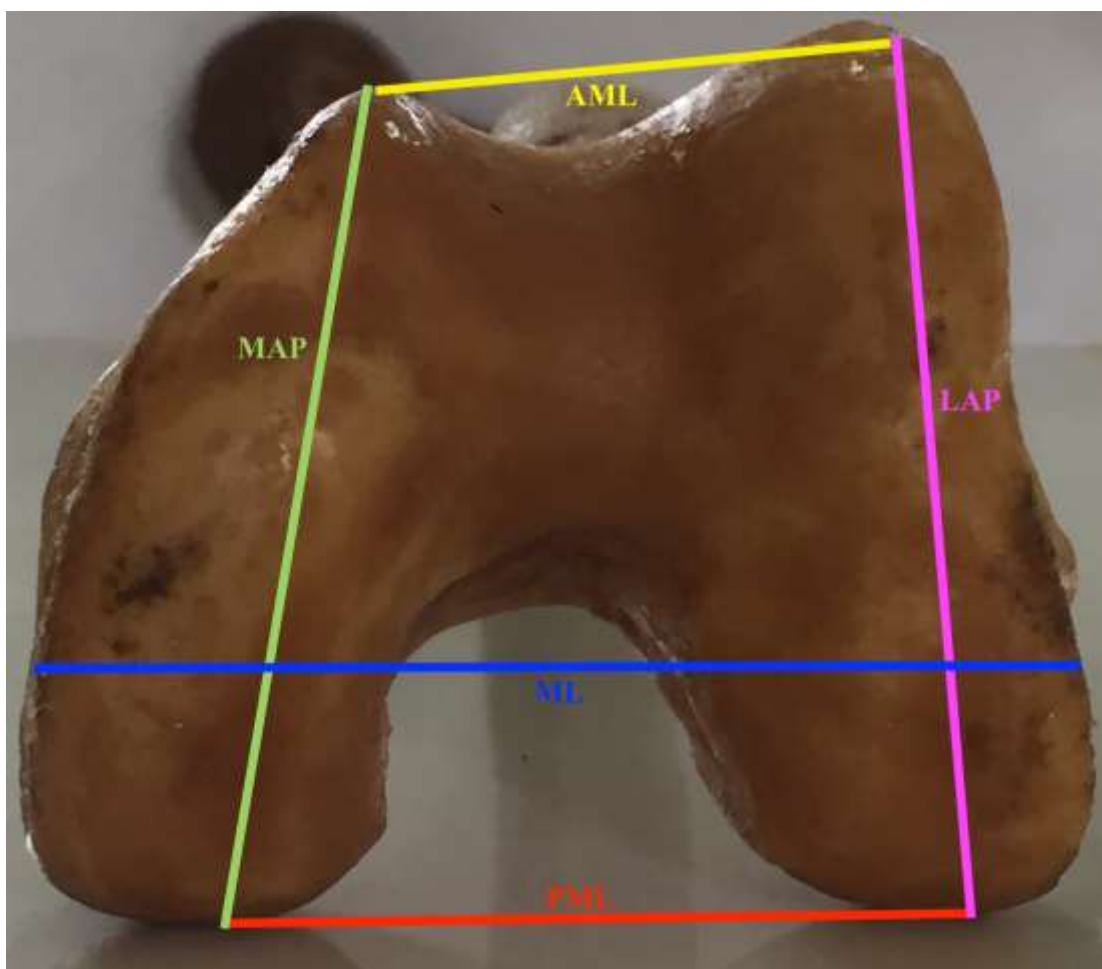




Photo taken by Saidina Esmail Ahmed (2015).

## Appendix 6: IREC Approval



**MOI TEACHING AND REFERRAL HOSPITAL**  
P.O. BOX 3  
ELDORET  
Tel: 334711/2/3



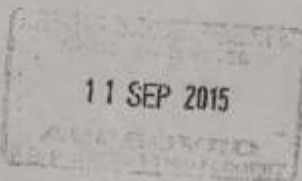
**MOI UNIVERSITY  
SCHOOL OF MEDICINE**  
P.O. BOX 4806  
ELDORET

**INSTITUTIONAL RESEARCH AND ETHICS COMMITTEE (IREC)**

Reference: IREC/2015/153  
**Approval Number: 0001494**

11<sup>th</sup> September, 2015

Dr. Ahmed Saidina Esmail,  
Moi University,  
School of Medicine,  
P.O. Box 4606-30100,  
ELDORET-KENYA.



Dear Dr. Ahmed,

**RE: FORMAL APPROVAL**

The Institutional Research and Ethics Committee has reviewed your research proposal titled:-


***"Distal Femur Morphology in Cadavers of Black Africans at the Moi and Nairobi Universities Anatomy Laboratories."***

Your proposal has been granted a Formal Approval Number: **FAN: IREC 1494** on 11<sup>th</sup> September, 2015. You are therefore permitted to begin your investigations.

Note that this approval is for 1 year; it will thus expire on 10<sup>th</sup> September, 2016. If it is necessary to continue with this research beyond the expiry date, a request for continuation should be made in writing to IREC Secretariat two months prior to the expiry date.

You are required to submit progress report(s) regularly as dictated by your proposal. Furthermore, you must notify the Committee of any proposal change (s) or amendment (s), serious or unexpected outcomes related to the conduct of the study, or study termination for any reason. The Committee expects to receive a final report at the end of the study.

Sincerely,



**PROF. E. WERE**  
CHAIRMAN


**INSTITUTIONAL RESEARCH AND ETHICS COMMITTEE**

cc	Director - MTRH	Dean - SOP	Dean - SOM
	Principal - CHS	Dean - SON	Dean - SOD

## Appendix 7: Approval Letter from Human Anatomy Department, Moi University

Dr. Ahmed Saidina Esmail,  
SM/PGORT/10/14  
Dept of Orthopaedics & Traumatology  
Moi University  
P.O. Box 4606-30100  
ELDORET

The H.O.D  
Dept. of Human Anatomy  
Moi University  
P.O. Box 4606-30100  
ELDORET

 HOD Anatomy  
Approved.  
20/8/15

20<sup>th</sup> August, 20115

Thro'  
The HOD,  
Dept. of Orthopaedics and Traumatology  
Moi University  
P.O. Box 4606-30100  
ELDORET

Dear Sir,

**RE: PERMISSION TO CARRY OUT MY THESIS RESEARCH AT THE HUMAN ANATOMY LABORATORY**

I am a first year masters student pursuing a career in Orthopaedics at Moi University. For my thesis I have opted to carry out a research on the morphology of the distal femora of Black Africans.

It will involve taking various measurements of the distal femora of the prosected cadavers using a pair of calibrated sliding callipers.

I request you to allow me in carrying out my research at the Human Anatomy Laboratory, Moi University subject to approval by Institutional Research and Ethics Committee.

Thanking you in advance,

Yours faithfully,

  
**DR. Ahmed Saidina Esmail**  
SM/PGORT/10/14

**Appendix 8: Approval Letter from Human Anatomy Department, University of Nairobi**



**UNIVERSITY OF NAIROBI  
COLLEGE OF HEALTH SCIENCES  
DEPARTMENT OF HUMAN ANATOMY**

P. O. BOX 30197-00100,  
NAIROBI, KENYA  
Email: dept-humananat@uonbi.ac.ke

Telephone: 020-4442368/4440705  
Cellphone: 0734-510541/0710622310  
Fax: 020-4450011

August 26, 2015

Dr. Ahmed Saidina Esmail  
SM/PGORT/10/14  
Moi University  
Edoret

Dear Dr. Esmail

**PROPOSAL ON MORPHOLOGY OF DISTAL FEMUR**

I have perused your study proposal on “ **MORPHOLOGY OF THE BLACK AFRICAN DISTAL FEMUR AT THE HUMAN ANATOMY LABORATORIES OF MOI UNIVERSITY AND UNIVERSITY OF NAIROBI, A CADAVERIC STUDY**” and confirm that the Department of Human Anatomy, University of Nairobi would be willing to support your endeavor.

Kindly get back to the department with the approval from IRB for further engagement on the specifics of the conduct of the study. The department will also be happy to provide an additional supervisor for the project from this end.

Thank you.

Sincerely,

**Prof. Saidi Hassan**  
Chairman

cc. Dr. B.R. Ayumba,  
Head, Dept. of Orthop. & Rehab.