

SPECIAL ARTICLE

Obstetrics

FIGO good practice recommendations to standardize the assessment of outcomes following vesicovaginal fistula surgery

Andrew Browning^{1,2} | Lilli Trautvetter³ | Gillian Slinger³ | Sayeba Akhter^{4,5} |
Fekade Ayenachew⁶ | James Chapa⁷ | Yeshineh Demrew⁸ | Hillary Mabeya⁹ |
Peter Majinge⁷ | Vindhya Pathirana¹⁰ | Thomas Raassen¹¹

¹Maternity Africa, Arusha, Tanzania

²Barbara May Foundation, Bowral, Australia

³FIGO, London, UK

⁴MAMM's Institute of Fistula and Women's Health, Dhaka, Bangladesh

⁵President of International Society of Obstetric Fistula Surgeons, Dhaka, Bangladesh

⁶International Fistula Alliance, Addis Ababa, Ethiopia

⁷Comprehensive Community Based Rehabilitation Tanzania (CCBRT), Dar es Salaam, Tanzania

⁸Addis Ababa Fistula Hospital, Addis Ababa, Ethiopia

⁹Gynocare Women's and Fistula Hospital, Eldoret, Kenya

¹⁰Cradle Specialty Health Centre, Dar es Salaam, Tanzania

¹¹AMREF (retired), International Fistula Surgeon, Weesp, The Netherlands

Correspondence

Andrew Browning, Maternity Africa, Arusha 16464, Tanzania.

Email: andrew_browning@hotmail.com

Funding information

Anonymous Foundation; Texas Children's Hospital

Abstract

Obstetric fistula is a debilitating childbirth injury causing immense suffering for women and girls with the condition. The majority of fistulas can be successfully treated with a surgical repair, performed by a competent surgeon who has undergone specialist training and who works with a holistic fistula care team. As well as surgical repair, a critical component of fistula treatment is meticulous postoperative assessment to accurately determine surgical outcomes so that further treatment and support can be provided as required, and the risk substantially reduced of any patient being discharged with associated ongoing problems, such as urinary retention or residual/ongoing incontinence. Based on the opinions of experts in the field, these good practice recommendations provide a practical and standardized protocol for the correct assessment of surgical outcomes following vesicovaginal fistula surgery and appropriate subsequent management.

KEYWORDS

dye test, fistula surgeon, obstetric fistula, ongoing incontinence, pad test, postvoid residual volume, surgical outcome assessment, vesicovaginal fistula surgery

1 | BACKGROUND

Obstetric fistula—although prevalent in more than 60 countries with approximately two million women affected worldwide—remains a neglected public health and human rights issue.^{1,2} This leads to an array of medical repercussions, including: a high patient burden with

a relatively small number of trained competent surgeons; inconsistent approaches to surgical treatment as well as pre- and postoperative management; and few resources to innovate and standardize practice.

Assessing outcomes following vesicovaginal fistula surgery is part of a fistula surgeon's routine work and determining these

This is an open access article under the terms of the [Creative Commons Attribution-NonCommercial](https://creativecommons.org/licenses/by-nc/4.0/) License, which permits use, distribution and reproduction in any medium, provided the original work is properly cited and is not used for commercial purposes.

© 2024 The Author(s). *International Journal of Gynecology & Obstetrics* published by John Wiley & Sons Ltd on behalf of International Federation of Gynecology and Obstetrics.

BOX 1 Step-by-step protocol on how to assess the surgical outcomes following vesicovaginal fistula surgery.

1. Carry out dye test: This should be done 10–14 days postoperatively, before removing the Foley catheter. Place the patient in the lithotomy position, introduce a Sims speculum and put dye in the catheter, then ask the patient to cough. Document the results.

- If the dye test is positive, check if the Foley catheter is protruding through the fistula; if it is, the catheter should be removed. If not, leave the Foley catheter in place for a further 7 days. During this time, observe if the patient is leaking any urine while walking, sitting, and/or lying in bed. Consider nursing the patient in a prone position when in bed.

- If, after longer catheterization, the wetness becomes absent, leave the Foley catheter in place until the patient has been dry for 7 days.
- If wetness is decreasing, consider leaving the Foley catheter in place for up to 4 weeks until the patient is dry, then keep it in situ for 7 additional days. After the patient has been dry for 7 days with the Foley catheter in place, repeat the dye test.

- If wetness is increasing or staying the same and the amount of urine in the drainage bag/bucket is increasing or staying the same, then the fistula is unlikely to close with further bladder catheterization. Remove the Foley catheter.

- ❖ Outcome: Conclude that the fistula is not closed/repair broken and the patient is incontinent of urine. As the repair has not been successful, a repeat operation should be scheduled, usually in 3 months' time. An unsuccessful repair can be very disappointing for the patient. Patients should therefore be carefully counseled, with appropriate hygiene and ongoing emotional support.

- If the dye test is negative, remove the Foley catheter, measure the voided volume and measure the postvoid residual volume of urine.

2. Measure postvoid residual volume by asking the patient to drink sufficient fluids to ensure that her urine is clear. Throughout the next 24–48 h, measure and record the patient's voided volume and postvoid residual volume of urine 3 times (even if the patient is wet). Measure postvoid residual urine volume with either an in-out catheter or, if available, a bladder scanner or ultrasound that can measure bladder volume.

If the residual volume is borderline and does not fit into the categories below, the patient should continue measuring residual volume a few more times.

- If postvoid residual volume is greater than 100 mL or >50% of voided amount:

- ❖ Outcome: Conclude that the fistula is closed but that the patient has urinary retention. Teach clean intermittent self-catheterization 3–4 times a day until the patient is emptying her bladder completely or the residual volume is less than 100 mL and less than 50% of the voided amount. At this point, carry out a pad test.

- If postvoid residual volume is less than 100 mL and less than 50% of the voided amount:

- The day after the Foley catheter is removed, carry out a pad test.

3. Carry out pad test. This is a useful standardized technique to obtain an objective assessment and measurement of urinary leakage. Ask the patient to drink 500 mL of water, and then to wear a pad while walking and doing a set series of activities for 60 minutes. If a simple kitchen scale is available, weigh the pad before and after, subtracting the initial dry weight from the wet weight. The weight will give you a quantification of the severity of the leakage. If a scale is not available, check if the pad is wet. Ensure that all findings are recorded.

- If the pad is wet:

- ❖ Outcome: Conclude that the fistula is closed but the patient has ongoing urinary incontinence. Investigate and plan appropriate management.

- If the pad is dry:

- ❖ Outcome: Conclude that the fistula is closed and the patient is continent of urine (cured). A few days after removal of the Foley catheter, arrange for discharge and usual follow-up, as long as there are no medical contraindications.

Following the above steps, a successful fistula repair closure (i.e. fistula closed and patient continent) can be determined by applying the following criteria:

- The dye test is negative prior to removal of the Foley catheter (normally, between 10 and 14 days postoperatively).

- After the Foley catheter has been removed, the postvoid residual volume of urine is less than 100 mL and less than 50% of the voided amount.

- The pad is dry the day after the Foley catheter has been removed.

accurately is critical, as the assessment will inform the surgeon's decisions regarding subsequent treatment, possibly necessitating further surgery and conservative management, including physiotherapy.

In general, postoperative clinical outcomes of vesicovaginal fistula repair surgery can be categorized as follows:

- Fistula closed and patient continent of urine (cured).
- Fistula closed but patient has ongoing urinary incontinence.

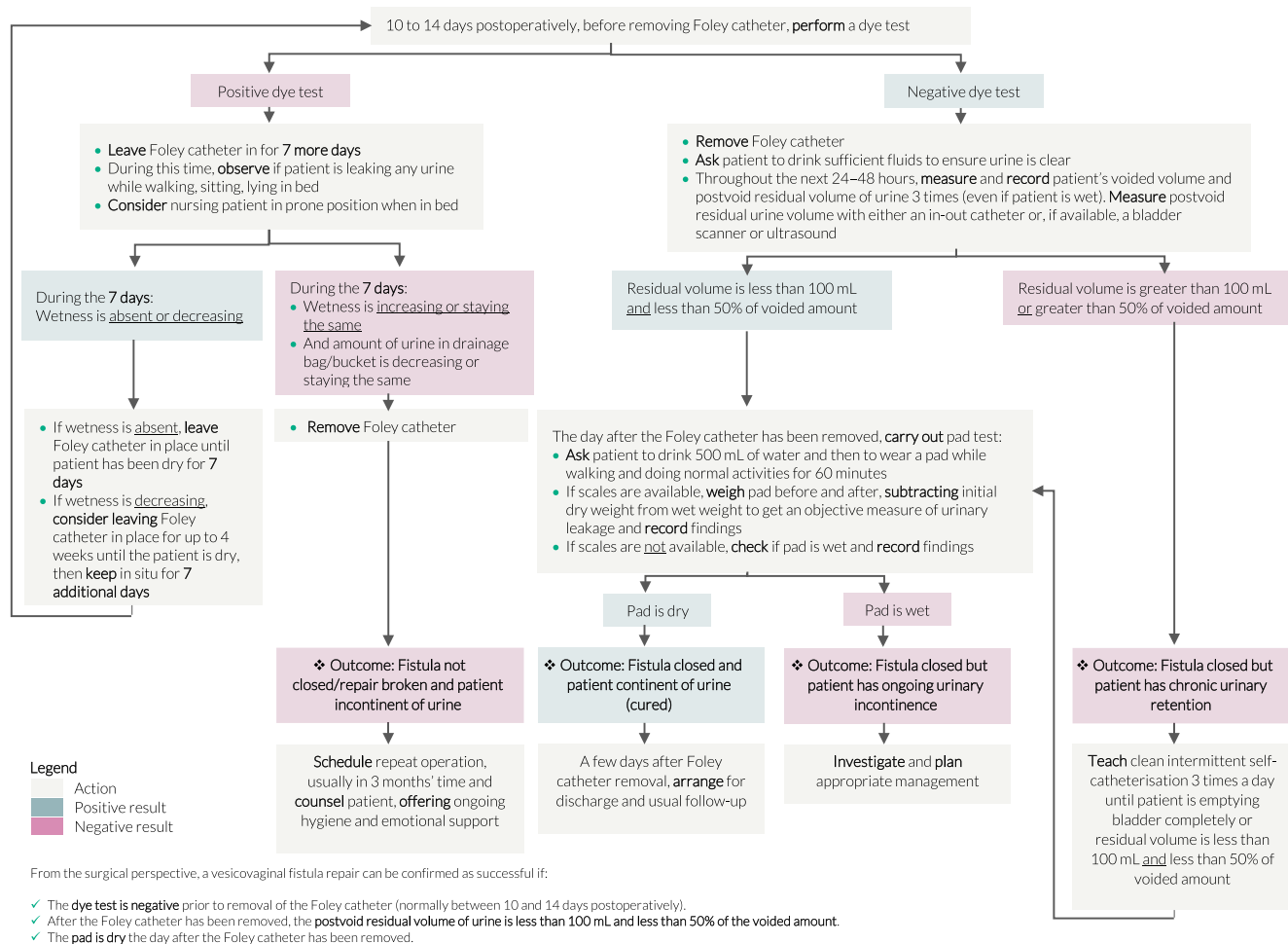


FIGURE 1 Assessing outcomes following vesicovaginal fistula repair (updated flowchart originally published in FIGO Fistula Surgery Training Manual 2022).

- Fistula closed but patient has chronic urinary retention.³
- Fistula not closed/repair broken down and patient incontinent of urine.

Existing evidence suggests that ongoing urinary incontinence after fistula closure is not uncommon, with studies reporting a wide-ranging incident rate of between 4.3% and 67%,^{4–9} which encompasses stress incontinence, overactive bladder/urge incontinence, mixed incontinence, and chronic urinary retention.

Additionally, relying on patients to accurately report postoperative clinical outcomes has proven unreliable, as patients may feel obliged to give positive feedback to please the surgeon even though they may be experiencing little or no improvement after surgery.

Therefore, if postoperative clinical surgical outcomes are not correctly assessed, surgeons inevitably run the risk of discharging their patients with ongoing urinary incontinence or other associated problems and with no management plan in place. This will most likely have a devastating impact on the patients¹⁰ who, as a result, will continue to experience poor quality of life, which can lead to renewed and persistent marginalization from their communities, increasing

poverty, depression, and a sense of hopelessness as there is no prospect of a cure or further support.

2 | UTILIZING ESTABLISHED PROTOCOLS TO OBJECTIVELY ASSESS SURGICAL OUTCOMES

Assessment protocols on how to objectively measure the level of urinary incontinence have been developed and published,^{11,12} including freely accessible publications by prominent fistula surgeons^{13,14} as well as limited research reinforcing the effectiveness of such tools and their validity.¹⁵ However, the level of awareness about these resources and their use by the fistula community is unknown.

As approaches regarding how to determine surgical outcomes continue to be inconsistent, the aim of these good practice recommendations is to provide a detailed protocol with the objective of standardizing:

- (1) Assessment of surgical outcomes following vesicovaginal fistula repair;

- (2) Interpretation of results; and.
- (3) Ongoing management of patients.

3 | KEY RECOMMENDATIONS

The recommendations listed in [Box 1](#), based on the expert opinions of practicing fistula surgeons, including the Fistula Surgery Training Initiative's Expert Advisory Group,¹⁶ show a step-by-step protocol on how to assess the surgical outcomes following vesicovaginal fistula surgery.

The key recommendations are shown in flowchart format in [Figure 1](#).

4 | IMPLEMENTATION AND COST-EFFECTIVENESS

Although a variety of materials are required to carry out a complete postoperative assessment following vesicovaginal fistula repair, most of these resources are relatively low cost and should be widely available, including Foley catheters, dye, Sims vaginal specula, different types of pads, and locally available scales to weigh the pad. Procuring any missing materials can also be explored in the treatment facility or with supporting partners.

Utilizing these good practice recommendations will give clear direction to any fistula surgeon and care teams assessing patients after vesicovaginal fistula repair. As the protocol explains the different steps in terms of actions, time periods, and materials needed, the costs per patient/assessment can easily be calculated and budgeted accordingly. Free print versions of the flowchart in A4 and A3 format in English, French, and Portuguese are also available on the FIGO Fistula Resource Hub.¹⁷

It is hoped that use of this expert-recommended tool will enhance cost-effectiveness and treatment outcomes as it will reduce the risk of the surgeon inadvertently missing something critical during the assessment, which could lead to premature discharge of the patient and subsequent return visits in future—if this is even possible—to undergo further investigations.

5 | CONCLUSION

These good practice recommendations detail the steps required for an accurate assessment of surgical outcomes following vesicovaginal fistula repair and outline the options available for correct management of a variety of different outcomes. Based on expert opinion, it is anticipated that this protocol will lead to greater uptake and standardization for fistula surgeons and their care teams, as well as contributing to the further development of a common language to facilitate discussion of fistula patients and their treatment outcomes by the fistula community. Finally, and most importantly, it is hoped that these recommendations will result in more women being discharged following

an accurate postoperative clinical assessment and with a correct and appropriate treatment plan in place.

6 | EVOLVING EFFORTS TO ADDRESS ONGOING URINARY INCONTINENCE FOLLOWING VESICOVAGINAL FISTULA REPAIR SURGERY

Ongoing urinary incontinence as one of the potential surgical outcomes following vesicovaginal fistula repair poses a great challenge for fistula surgeons and patients alike. To bring this pressing issue to the forefront, FIGO, together with Hamlin Fistula Ethiopia, convened expert fistula surgeons from around the world in the Addis Ababa Fistula Hospital in early 2024 to share the latest surgical and conservative techniques for treatment and start the development of a set of good practice recommendations to specifically address the management of ongoing urinary incontinence in postrepair fistula patients. The presentations made at the workshop are available for download¹⁸ and a freely accessible position paper and detailed flowchart are currently being developed by the workshop participants for future publication.

AUTHOR CONTRIBUTIONS

Development of this article was conducted by L.T., using the FIGO Fistula Surgery Training Manual as the basis for the key recommendations. Guidance, contributions, and amendments were made by A.B. and G.S. All co-authors were invited to provide feedback. An overall review of the final draft was carried out in the presence of most co-authors.

ACKNOWLEDGMENTS

We extend our sincere thanks and appreciation to all FIGO fellows, trainers, and partners for their support of the Fistula Surgery Training Initiative.

FUNDING INFORMATION

Open Access funding for this article was financially supported by the Texas Children's Hospital and an anonymous foundation.

CONFLICT OF INTEREST STATEMENT

The authors declare no conflicts of interest.

DATA AVAILABILITY STATEMENT

Data sharing is not applicable to this article as no new data were created or analyzed in this study.

REFERENCES

1. Adler AJ, Ronsmans C, Calvert C, Filippi V. Estimating the prevalence of obstetric fistula: a systematic review and MetaAnalysis. *BMC Pregnancy*. 2013;13:246.
2. Waaldijk K, Armiya'u YD. The obstetric fistula: a major public health problem still unsolved. *Int Urogynecol J*. 1993;4:126-128.

3. International Incontinence Society. ICS Glossary. Chronic (urinary) retention. Accessed May 23, 2024. <https://www.ics.org/glossary/diagnosis/chronicurinaryretention>
4. Nembunzu D, Mayemba N, Sidibé S, et al. Factors associated with persistent urinary incontinence among women undergoing female genital fistula surgery in the Democratic Republic of Congo from 2017 to 2019. *Front Glob Womens Health*. 2022;3:896991.
5. Bengtson AM, Kopp D, Tang JH, Chipungu E, Moyo M, Wilkinson J. Identifying patients with vesicovaginal fistula at high risk of urinary incontinence after surgery. *Obstet Gynecol*. 2016;128:945-953.
6. Tadesse S, Mekete D, Negese S, Belachew DZ, Namara GT. Urinary incontinence following successful closure of obstetric vesicovaginal fistula repair in Southern Ethiopia. *BMC Womens Health*. 2024;24:164.
7. Goh JT, Krause H. Urinary incontinence following obstetric fistula repair. *World J Obstet Gynecol*. 2016;5:182-186.
8. Nardos R, Jacobson L, Garg B, Wall LL, Emasu A, Ruder B. Characterizing persistent urinary incontinence after successful fistula closure: the Uganda experience. *Am J Obstet Gynecol*. 2022;227(70):e1-e9.
9. Browning A, Menber B. Women with obstetric fistula in Ethiopia: a 6-month follow up after surgical treatment. *BJOG*. 2008;115:1564-1569.
10. Nardos R, Phoutrides EK, Jacobson L, et al. Characteristics of persistent urinary incontinence after successful fistula closure in Ethiopian women. *Int Urogynecol J*. 2020;31:2277-2283.
11. Krhut J, Zachoval R, Smith PP, et al. Pad weight testing in the evaluation of urinary incontinence. *Neurourol Urodyn*. 2014;33:507-510.
12. Borazjani A, Tadesse H, Kember A, Ayenachew F, et al. Application of the 1-hour pad-test and a novel pictorial questionnaire in the assessment of urinary incontinence following successful closure of obstetric vesicovaginal fistula. Conference abstract. ICS 2014, October 20-24, Rio de Janeiro, Brazil, Urinary incontinence following successful closure of obstetric vesicovaginal fistula repair in Southern Ethiopia, 24. 2014.
13. Breen M. *Manual of obstetric fistula surgery*. The Foundation for the Global Library of Women's Medicine; 2019.
14. Browning A, Hancock B. *Practical Obstetric Fistula Surgery*. Second ed. Halstead Press; 2022.
15. Kopp D, Bengtson A, Tang J, Chipungu E, Moyo M, Wilkinson J. Use of a postoperative pad test to identify continence status in women after obstetric vesicovaginal fistula repair: a prospective cohort study. *BJOG*. 2017;124:966-972.
16. FIGO, Fistula expert advisory group. FIGO Fistula Surgery Training Manual. Accessed May 23, 2024. <https://www.figo.org/figo-resources/obstetric-fistula/training/manual>
17. FIGO. Fistula Resource Hub. Accessed May 23, 2024. <https://www.figo.org/figo-resources/obstetric-fistula>.
18. FIGO. FIGO-HFE Expert Surgical Workshop in Addis Ababa. Accessed May 23, 2024. <https://www.figo.org/fistula-resources/figo-hfe-expert-surgical-workshop-addis-ababa>.

How to cite this article: Browning A, Trautvetter L, Slinger G, et al. FIGO good practice recommendations to standardize the assessment of outcomes following vesicovaginal fistula surgery. *Int J Gynecol Obstet*. 2025;168:497-501. doi:[10.1002/ijgo.16017](https://doi.org/10.1002/ijgo.16017)