



Research Article

ISSN 2320-4818

JSIR 2022; 11(1): 17-20

© 2022, All rights reserved

Received: 05-02-2022

Accepted: 13-03-2022

Ayiro Allan

Resident, Moi University, School of Medicine,
Department of Radiology and Imaging

Abuya Joseph

Senior Lecturer, Department of Radiology and
Imaging, School of Medicine

Omeng Orange'o

Senior Lecturer, Department of Reproductive
Health, School of Medicine, Moi University

Correspondence:

Abuya Joseph

Senior Lecturer, Department of
Radiology and Imaging, School of
Medicine

Email: abuyajm@yahoo.com

Pelvic ultrasound and histopathological findings in post-menopausal patients with uterine bleeding in Western Kenya

Ayiro Allan, Abuya Joseph, Omeng Orange'o

Abstract

Background: Post-menopausal bleeding is a common gynecologic problem accounting for a significant number of yearly visits to our outpatient gynecologic clinic. Ultrasound in comparison with histopathology aids in the early diagnosis of possible causes. **Objective:** To ascertain the diagnostic accuracy of pelvic ultrasonography in patients with postmenopausal bleeding in our hospital. **Methods:** This was a descriptive cross-sectional study done between July 2017 and June 2018 at Moi Teaching and Referral Hospital. Consecutive sampling on consenting patients presenting with a clinical diagnosis of post-menopausal bleeding was done. A total of 67 participants were included. A structured questionnaire was administered to the participants. Categorical data was summarized as well as continuous variables. Data analysis and statistical computing was done. **Results:** The mean age was at 54.6 years. The years post menopause ranged from 1-15 years with a mean age of 4.6 years. There were 31 (46.2%) participants with endometrial thickness greater than 5mm. Uterine fibroids in 2 participants while endometrial fluid was seen in 2 participants. On histopathological diagnosis, atrophic endometritis accounted for 48% of the cases. Endometrial hyperplasia was at 22%, endometrial carcinoma at 13%, chronic endometritis 8%, endometrial polyp 6% and unremarkable (normal) diagnosis at 3%. A level of agreement for malignancy calculated was found to be 57%. **Conclusion:** Increase in endometrial thickness is associated with an increased risk in malignancy. The level of agreement between ultrasound and histopathology is low at 53%.

Keywords: Post-Menopausal, Uterine Bleeding, Pelvic Ultrasound, Histopathological.

INTRODUCTION

Abnormal uterine bleeding is a common finding in patients in post-menopausal age presenting in our gynaecological ultrasound clinics. Some of the causes of this abnormal uterine bleeding have been associated with a high morbidity and mortality if not diagnosed early.

A study conducted by Van den Bosch, *et al.*, (2015) showed that out of 1220 post-menopausal women who underwent some form of imaging, all of those that were subsequently confirmed as having confirmed malignancy after suspicion on imaging were 7% of the study population [1].

Transvaginal Ultrasound in our setting remains the modality of choice in these patients.

Gynaecological malignancies account for 1 in 4 new cases diagnosed in developing countries [2]. Abnormal uterine bleeding is a common presentation in the gynaecological unit, the most common presentation is usually in pre-menopausal women, however it has been noted that there is an increase in patients presenting with postmenopausal bleeding [3].

A large number of patients present with abnormal uterine bleeding in our set up especially in the gynaecology clinics. Different pathology as alluded to, may present with abnormal uterine bleeding-(AUB) posing a diagnostic challenge to the clinician. This can result in mis-management of the patient. Clear understanding of possible findings is therefore important as it leads to adoption of improved and standardized management options for this condition.

Ultra sound currently in our set up has been the imaging modality of choice in the evaluation and diagnosis of abnormal uterine bleeding. However, there is paucity of information existing in our setting to clearly

describe the findings demonstrated by ultrasonography and its histopathology comparison. Ultrasound imaging findings with this comparison plays a significant role in aiding treatment.

Sonographic evaluation of the uterus is mainly done through two main ways. The transabdominal approach and the transvaginal approach. A pelvic ultrasound is a non-invasive diagnostic examination that is used to assess structures and organs within the female pelvis.

Lesions lesser than 5 mm in the widest diameter are not accurately reported by transabdominal sonography. Transvaginal sonography is the modality of choice to use as it provides improved resolution albeit with a limited field of view [4].

Sonographic size of the endometrium therefore reflects the presence or absence of significant functional or an intraluminal tumour or lesion. This thus presents the need for sonography to help evaluate and either recommend or remove the need for biopsy of a senile and symmetrical uterus. Information of the image is thus best done in correlation with past medical history and treatment informed by this functional understanding of the uterus.

The expected uterus image of a normal untreated post-menopausal uterus, viewed in mid sagittal section at an angle of insertion of the uterine axis of between 60 degrees and 90 degrees includes two very thin basalis condensed with the specular reflection of the luminal interface into a regular stripe with a thickness of 4mm or less. This measurement should also be correlated with uterine symmetry as asymmetry in this layer is the hallmark of abnormally [5].

Many investigations have concluded that there is a sonographic threshold of 4mm for a normal endometrial thickness in bleeding post-menopausal woman below which neither atypical hyperplasia or cancer is likely to be found [6]. However, it is also appreciated that malignancy can be found in patients with an endometrial thickness of less than 3 mm and hence emphasizing the need of holistic clinical management.

Endometrial assessment by means of biopsy or sampling of endometrial cells is a minimally invasive alternative to dilatation and curettage as a means of uterine evaluation in a study on the accuracy of outpatient endometrial biopsy in diagnosing endometrial cancer, it showed that outpatient biopsy has a high overall accuracy if an adequate sample is collected [7]. Biopsy taking involves a mini surgical procedure that allows one to take a small tissue sample either under general anaesthesia or as a side room procedure that is then processed by the pathology department

Table 1: Pelvic Ultra sound findings

Findings	Frequency	Percent
Endometrial thickness <5mm	32	47.8
Endometrial thickness ≥5mm	31	46.2
Uterine fibroid present	2	3.0
Endometrial fluid present	2	3.0

At ultrasound two patients had uterine fibroid and another two had endometrial fluid. These patients were thus not subjected to further histologic evaluation.

The other patients were further done biopsy and specimen sent for histopathology analysis. The figure below shows a summary of the histopathological findings.

Women in this study tend to have same age at the start of menopause, the youngest at the start of menopause was 47 years and oldest 55 years.

and a microscopic or chemical analysis done. It is the gold standard for any pathological disease process as it studies the cell morphology and chemical characteristics allowing us to distinguish between the normal and abnormal changes.

MATERIALS AND METHODS

This was a cross sectional study where all patients parenting with post-menopausal bleeding who were referred for ultrasound were evaluated. Ultrasound was carried out at the Radiology and Imaging department, of Moi Teaching and Referral Hospital Eldoret, Kenya from July 2017 to June 2018. The study population was all post-menopausal women presenting with abnormal post-menopausal uterine bleeding at this hospital who were referred for ultra sound evaluation. Patients presenting with post-menopausal bleeding who are referred to the radiology department and consented to this study were recruited. Any patient who was on management for a known abdominopelvic malignancy and any patient on any hormone replacement therapy was excluded. A total 67 patients were recruited into this study.

A transvaginal ultrasound examination aimed at localizing the pathologic lesions and uterine texture and consistency, characterizing the lesions in terms of echo-texture, definition of outline, determination of the size and extent of the lesion was carried out.

Data analysis was conducted using STATA version 13 SE. Categorical. Continuous variables such as age were summarized as mean and the corresponding standard deviation if they assumed the Gaussian distribution.

Approval to carry out the study was sought from the Institutional Research and Ethics Committee (IREC). Informed consent was sought from patients/guardians.

RESULTS

The age distribution of the patients ranged from 48 to 68 years and an average of 54.7 (SD 4.1) years. The median age was 54 years IQR 52, 57).

The years' post-menopause ranged from 1 to 15 years with mean of 4.6 (SD 3.1) and a median of 4 (IQR 2, 6).

The pelvic ultrasound findings are as shown below.

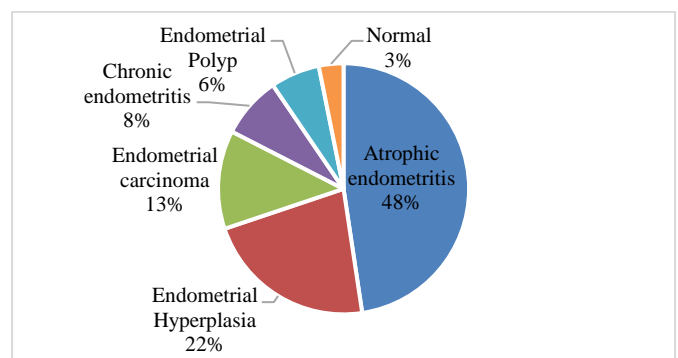


Figure 1: Histopathological diagnosis the table below shows a comparison between ultrasound findings and histopathological diagnosis

Table 2: Endometrial thickness summary per diagnosis

Histopathology diagnosis	N	Ultrasound findings (endometrial thickness in mm)			
		Mean (SD)	Median (IQR)	Minimum	Maximum
Atrophic endometritis	30	3.25(0.47)	3.1(3, 3.5)	2.5	4.2
Chronic endometritis	5	5.78(0.72)	5.6(5.4, 6)	5	6.9
Endometrial hyperplasia	14	5.94(0.43)	6(5.5, 6.4)	5.2	6.5
Endometrial polyp	4	6.65(0.3)	6.6(6.4, 6.9)	6.4	7
Endometrial carcinoma	8	6.1(1.63)	6.5(5.1, 7.1)	3.4	8
Normal	6	5.8(0.28)	5.8(5.6, 6)	5.6	6

Table 3: Age summary per diagnosis

Histopathological diagnosis	N	Age in Years			
		Mean (SD)	Median (IQR)	Minimum	Maximum
Atrophic endometritis	30	52.33(2.35)	52.5(50, 54)	48	57
Chronic endometritis	5	55.20(1.09)	55.0(55, 55)	54	57
Endometrial hyperplasia	14	56.79(3.53)	56.0(54, 60)	52	64
Endometrial polyp	4	51.75(1.71)	51.5(50.5, 53)	50	54
Endometrial carcinoma	8	61.37(3.46)	60.0(59, 63.5)	58	68
Normal	6	53.5(0.71)	53.5(53, 54)	53	54

Table 4: Years past menopause summary per diagnosis

Histopathological diagnosis	N	Years past menopause			
		Mean (SD)	Median (IQR)	Minimum	Maximum
Atrophic endometritis	30	2.77(1.07)	3(2, 3)	1	5
Chronic endometritis	5	5.7(0.67)	6(5,6)	5	6.5
Endometrial hyperplasia	14	6.36(2.90)	5(4, 7)	4	12
Endometrial polyp	4	2(0.82)	2(1.5, 2.5)	1	3
Endometrial carcinoma	8	9.75(2.60)	9(8, 11)	7	15
Normal	6	3(1.4)	3(2, 4)	2	4

Table 5: Histopathology findings

US findings	Histopathology findings		
	Malignant	Non malignant	Total
Suspicious (≥ 5 mm)	6	25	31
Benin (< 5 mm)	2	34	36
Total	8	55	67

The total row level of agreement was 36/67=53%

DISCUSSION

Ultrasound provides an important adjunct to clinical examination in the evaluation of gynaecologic maladies. According to Munir *et al.*, (2010), ultrasonography is key to confirmation of the presence of a mass, its origin, size and consistency. These characteristics aid greatly in determining the likelihood of the benign or malignant nature of a lesion.

In this study the most common sonographic finding was uterine atrophy which accounted for 48.7% of our study population^[8]. This is in agreement with a study that found uterine atrophy to be the most common presentation in patients presenting with post-menopausal bleeding^[6].

In a study by Ferrazi *et al.* (1996), they showed that one can safely with a measurement of below 4mm of endometrial thickness predict endometrial atrophy and hence justify expectant management of these patients^[9].

On average patients in our study who had an endometrial thickness greater than 5mm in whom a diagnosis of endometrial hyperplasia was made had a mean thickness of 6.2mm on ultrasound.

A number of studies have indeed validated sonography in the evaluation of gynaecologic masses. In Ong's study Ong, *et al.*, (1996) showed that sonography had a high positive predictive value for the anatomic characteristics of masses^[10]. However, another study done in Sweden, contrasts with our findings and this could be attributed to the fact that there is widespread use of hormone replacement therapy (HRT) in their setting contrasting with our set up. Moreover, the advent of late menopause in their setup due to HRT use also contributes to this factor^[11]. In our study, we found 2 patients (3%) with uterine fibroids. In general, uterine fibroids are the most common gynaecologic masses found in the general population. However, the relative risk is greatly reduced in post-menopausal women as most fibroids shrink after menopause.

Most studies on gynaecological malignancy showed that cervical cancer was the most common cause of gynaecological malignancy. A study in Nigeria showed that it accounted for 78% of abnormal uterine bleeding^[12]. In Ghana, a study was done and showed similar findings^[13]. Going by this and widespread research,

cervical cancer remains the biggest cause of abnormal uterine bleeding in both the pre- and post-menopausal age groups but the incidence is low in our study because these patients are not routinely sent for sonography for initial diagnosis. Clinical diagnosis remains the mainstay with colposcopy and tissue biopsy.

Endometrial fluid collection in an otherwise non thickened endometrium was found in 2 patients. It is worthwhile to note that normal atrophic post-menopausal endometrium in association with cervical stenosis can also produce endometrial fluid collections ^[6].

Atrophic endometritis accounted for 48% of our study population, (n=30) with a mean of 3.25mm on ultrasound in terms of thickness. With the onset of menopause there is associated decline of oestrogen and progesterone. These hormones are key in maintaining the endometrial integrity during the pre-menopausal era. A study done by Nasri *et al.* (2012), compared well with our findings. In their findings they found that up to 51% of patients who presented with post-menopausal bleeding had upon histopathological diagnosis been proved to have endometrial atrophy ^[11]. In a study done on Afro-Caribbean women in Jamaica, it was found out that 70% of women with endometrial thickness less than 5mm had benign pathology with endometrial atrophy the predominant finding ^[14].

Endometrial hyperplasia is defined as proliferation of glands of irregular size and shape with a noted increase in the gland's stromal ratio. Endometrial hyperplasia is a known precursor to endometrial carcinoma. In our study it accounted for 22% of the cases in histopathology. This accounted for 14 of the total 67 participants. On ultrasound these patients had a mean thickness of 6.36mm with SD (2.90). A study done in Jamaica showed similarity to our study as endometrial hyperplasia on histopathology accounted for 22.3% of their patients ^[15].

Endometrial hyperplasia though commonly diagnosed in post-menopausal women can occur in any woman with an unopposed oestrogen exposure ^[16]. In a study by B. Long *et al.*, (2013), they found out that at every stage of presentation blacks usually have worse clinical presentation than their white counterparts ^[17]. This is true in our set up as advanced disease was the most common presentation likely due to both socio-economic status and health seeking behaviour amongst our population.

In our study we found that chronic endometritis accounted for 8 % of the study population. Chronic endometritis is defined as persistent inflammation of the endometrial lining. Most other studies have shown that it's a very rare occurrence and our study differs greatly. It is postulated that maybe the cause might be Tuberculum endometritis in lieu of the prevalence of Tuberculosis and the immune status of some of our patients. In another study done in Istanbul, this accounted for approximately 1% of the cases occurring of post-menopausal bleeding ^[18]. In a study done in Nigeria, they found out the incidence to be only 3 patients out of a possible 661 women and of significance they were pre-menopausal women who had presented as cases of secondary infertility ^[19].

CONCLUSION

The mean age of onset of menopause from our participants was 54.6 years. The mean age of onset of bleeding post menopause was 4.6 years with a range of 1-15 years. Increase in endometrial thickness is associated with an increased risk for malignancy. However, it does not definitively rule it in or out. Chronic endometritis was a significant finding in our set up. Endometrioid adenocarcinoma is the most common histopathologic subtype amongst patients with malignant changes in our study.

Recommendation

There is a significant number of patients with chronic endometritis and further studies to elucidate the cause should be undertaken. An atrophic or normal endometrium in the setting of clinical symptoms does not rule out malignancy and a high index of suspicion when scanning elderly patients should be employed.

Acknowledgement

We would like to thank the Moi Teaching and Referral Hospital and School of Medicine, Moi University for their support in carrying out this study as well as the study participants.

Conflict of Interest

None declared.

Financial Support

None declared.

REFERENCES

1. Van den Bosch T, Ameye L, Van Schoubroeck D, Bourme T, Timmerman D. Intra-cavitary uterine pathology in women with abnormal uterine bleeding: a prospective study of 1220 women. *Facts, views & vision in ObGyn*. 2015;7(1):17.
2. Iyoke CA, Ugwu GO. Burden of gynaecological cancers in developing countries. *World Journal of Obstetrics and Gynecology*. 2013;2(1):1-7.
3. Jones K, Bourne T. The feasibility of a 'one stop' ultrasound-based clinic for the diagnosis and management of abnormal uterine bleeding. *Ultrasound in Obstetrics and Gynecology: The Official Journal of the International Society of Ultrasound in Obstetrics and Gynecology*. 2001;17(6):517-21.
4. Weissman AM, Barloon TJ. Transvaginal ultrasonography in nonpregnant and postmenopausal women. *American family physician*. 1996;53(6):2065-72.
5. Cecchini S, Ciatto S, Bonardi R, Grazzini G, Mazzotta A. Endometrial ultrasonography-An alternative to invasive assessment in women with postmenopausal vaginal bleeding. *Tumori Journal*. 1996;82(1):38-9.
6. Goldstein SR, Nachtigall M, Snyder JR, Nachtigall L. Endometrial assessment by vaginal ultrasonography before endometrial sampling in patients with postmenopausal bleeding. *American journal of obstetrics and gynecology*. 1990;163(1):119-23.
7. Clark TJ, Voit D, Gupta JK, Hyde C, Song F, Khan KS, *et al.* Accuracy of hysteroscopy in the diagnosis of endometrial cancer and hyperplasia: a systematic quantitative review. *Jama*. 2002;288(13):1610-21.
8. Munir S, Amin D, Sultana M, Saeed T. Ovulation induction using laparoscopic ovarian drilling in women with polycystic ovarian syndrome: predictors of success. *Biomedica*. 2010;26(2):130-4.
9. Ferrazzi E, Torri V, Trio D, Zannoni E, Filiberto S, Dordoni D, *et al.* Sonographic endometrial thickness: a useful test to predict atrophy in patients with postmenopausal bleeding. *An Italian multicenter study. Ultrasound in Obstetrics and Gynecology: The Official Journal of the International Society of Ultrasound in Obstetrics and Gynecology*. 1996;7(5):315-21.
10. Ong S, Duffy T, Murphy J. Transabdominal ultrasound and its correlation with clinical findings in gynaecology. *Irish journal of medical science*. 1996;165(4):268-70.
11. Nasri MN, Coast GJ. Correlation of ultrasound findings and endometrial histopathology in postmenopausal women. *BJOG: An International Journal of Obstetrics & Gynaecology*. 1989;96(11):1333-8.
12. Ugwu EO, Iferikigwe SE, Okeke TC, Ugwu AO, Okezie OA, Agu PU, *et al.* Patter of Gynaecological Cancers in University of Nigeria Teaching Hospital, Enugu, South Eastern Nigeria. *Nigerian Journal of Medicine*. 2011;20(2):266-9.
13. Nkyekyer K. Pattern of gynaecological cancers in Ghana. *East African medical journal*. 2000;77(10).
14. Phillip H, Dacosta V, Fletcher H, Kulkarni S, Reid M. Correlation between transvaginal ultrasound measured endometrial thickness and histopathological findings in Afro-Caribbean Jamaican women with postmenopausal bleeding. *Journal of Obstetrics and Gynaecology*. 2004;24(5):568-72.
15. Escoffery CT, Blake GO, Sargeant LA. Histopathological findings in women with postmenopausal bleeding in Jamaica. *The West Indian Medical Journal*. 2002;51(4):232-5.
16. Montgomery BE, Daum GS, Dunton CJ. Endometrial hyperplasia: a review. *Obstetrical & gynecological survey*. 2004;59(5):368-78.
17. Long B, Liu FW, Bristow RE. Disparities in uterine cancer epidemiology, treatment, and survival among African Americans in the United States. *Gynecologic oncology*. 2013;130(3):652-9.
18. Long B, Liu FW, Bristow RE. Disparities in uterine cancer epidemiology, treatment, and survival among African Americans in the United States. *Gynecologic oncology*. 2013;130(3):652-9.
19. Ojo BA, Aboyeji PA, Buhari MO, Abdulraman MB. Endometrial pathology in a teaching hospital in North Central Nigeria: a histopathological survey. *Nigerian Journal of Health and Biomedical Sciences*. 2005;4(2):107-11.