

See discussions, stats, and author profiles for this publication at: <https://www.researchgate.net/publication/353455605>

Apert syndrome, a rare case description and complicated syndactyly surgical decision making in a resource limited setting

Article · July 2021

DOI: 10.22271/27078345.2021.v3.i1b.58

CITATIONS

0

READS

32

4 authors, including:



Alex Momanyi

Moi Teaching and Referral Hospital

1 PUBLICATION 0 CITATIONS

SEE PROFILE



Paul Mwangi

4 PUBLICATIONS 11 CITATIONS

SEE PROFILE

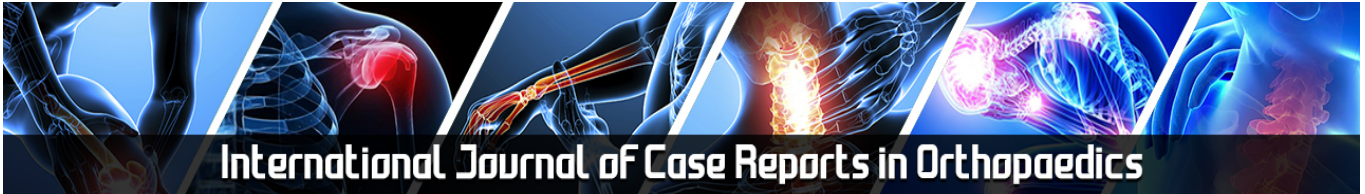

Barry Ayumba

Moi University

10 PUBLICATIONS 56 CITATIONS

SEE PROFILE



E-ISSN: 2707-8353
P-ISSN: 2707-8345
IJCRO 2021; 3(2): 01-06
Received: 02-04-2021
Accepted: 05-06-2021

Dr. Momanyi Oyagi Alex
Department of Orthopaedic
Surgery, Institute/ University
/Hospital Moi University/Moi
Teaching and Referral
Hospital, Eldoret, Kenya

Dr. Paul Mwangi
Consultant Orthopedic and
Trauma Surgeon, Hand
Specialist, Moi Teaching and
Referral Hospital, Eldoret,
Kenya

Dr. Barry Ayumba
Head of Department of
Orthopaedic and trauma
Surgery, Moi University,
Eldoret, Kenya

Dr. Ronald Lwegado
Plastics and Reconstructive
Surgeon Moi Teaching and
Referral Hospital. Eldoret,
Kenya

Corresponding Author:
Dr. Momanyi Oyagi Alex
Department of Orthopaedic
Surgery, Institute/ University
/Hospital Moi University/Moi
Teaching and Referral
Hospital, Eldoret, Kenya

Apert syndrome, a rare case description and complicated syndactyly surgical decision making in a resource limited setting

Dr. Momanyi Oyagi Alex, Dr. Paul Mwangi, Dr. Barry Ayumba and Dr. Ronald Lwegado

DOI: <https://doi.org/10.22271/27078345.2021.v3.i1b.58>

Abstract

Apert syndrome is a rare genetic type I acrocephalosyndactyly disease characterized by craniofacial dysmorphism and syndactyly of the hands and feet. It assumes as an autosomal dominant inheritance with mutations in the fibroblast growth factor receptor gene. We report an observation in an 11-month-old female infant who is on follow-up at the orthopaedic and plastic surgical clinics at Moi Teaching and Referral Hospital (Kenya). The paraclinical examination demonstrated complicated bilateral hand syndactyly, bilateral foot simple syndactyly on dedicated hand and foot radiographs, bicoronal synostosis with exophthalmos on cranial CT scan and atrial septal defect on echocardiogram. First stage border digit (thumb) syndactyly release was done at 9 months using the modified Flatt technique with complimentary full thickness skin grafts. Initial post-operative clinic review demonstrated surgical site healing with no signs of early creep. She is currently on scheduled multidisciplinary clinic follow-ups with the second stage surgery targeting six months postoperatively.

Keywords: Acrocephalosyndactyly, apert syndrome; complicated syndactyly

Introduction

Apert syndrome (also referred to as acrocephalosyndactyly, Online Mendelian Inheritance in Man number 101200) is a rare congenital anomaly belonging to the craniosynostosis syndromes (Type I) associated with its polyostotic skeletal anomalies [1, 2]. It was first described by Apert, a French physician, in 1906. Unlike other craniosynostosis syndromes (Pfeiffer, Chotzen, Crouzon), it presents with important characteristic orthopaedic polyostotic presentations [3, 4]. Reported prevalence at birth is 1:65,000 with equal male and female predilection [5].

It is a genotypically autosomal dominant locus mutation of the fibroblast growth factor receptor 2 (FGFR2) gene on chromosome 10q (10q25–26), commonly in exon 7 (Ser252Trp or Pro253Arg) [1, 4]. Though rare, cases in Africa have been documented [2]. Due to the financial and technical restraints in our set up, paraclinical karyotyping diagnostic confirmation is challenging. We present a case report to document findings and interventions instituted for an observed patient followed up at Moi Teaching and Referral Hospital, Eldoret, Kenya, through which we illustrate diagnostic limitations in the management of this condition in our context.

Case report

An otherwise jovial and healthy 2-month-old female infant was first referred to our orthopaedic hand surgery and plastics and reconstructive surgery clinics with dysmorphic features. She was the second born to her 28-year-old phenotypically healthy mother, and 31-year-old father. There was no associated 1st or 2nd degree family history of similar features or reported congenital malformations with an older 7-year-old sibling described as being phenotypically normal in stature and psychomotor function. She had initially been reviewed postnatally on 9/6/2020 at a regional county hospital having been delivered via an unremarkable vaginal delivery at term with a 4kg birth weight and an Apgar score of 9₁,10₅ and referred to our national referral facility due to noted congenital anomalies (craniofacial dysmorphism and syndactyly). Her neonatal and early infancy medical history was unremarkable Her initial review at 2 months at our surgical specialist clinics demonstrated the above features, good general state; with axillary temperature of 36.7°C,

weight of 5.9 kg (Weight for Age percentile = 95% (+1.64 SD); height at 63 cm (Length for Age percentile = 97.6%), Weight For Length percentile = 5.82%), the head circumference at 41 cm (Head Circumference for Age percentile = 94%).

Clinical examination demonstrated craniofacial dysmorphism with midface hypoplasia, craniosynostosis,

acrocephaly, exophthalmos, hypertelorism with telecanthus, high arched palate. She had bilateral hand complicated syndactyly, symphalangism with single furrowed fused nail giving the appearance of the hand in “muffle/cup” with associated complete feet syndactyly corresponding to the type IVb Haas Type [6] extension of the Temtamy and McKusick classification [7].

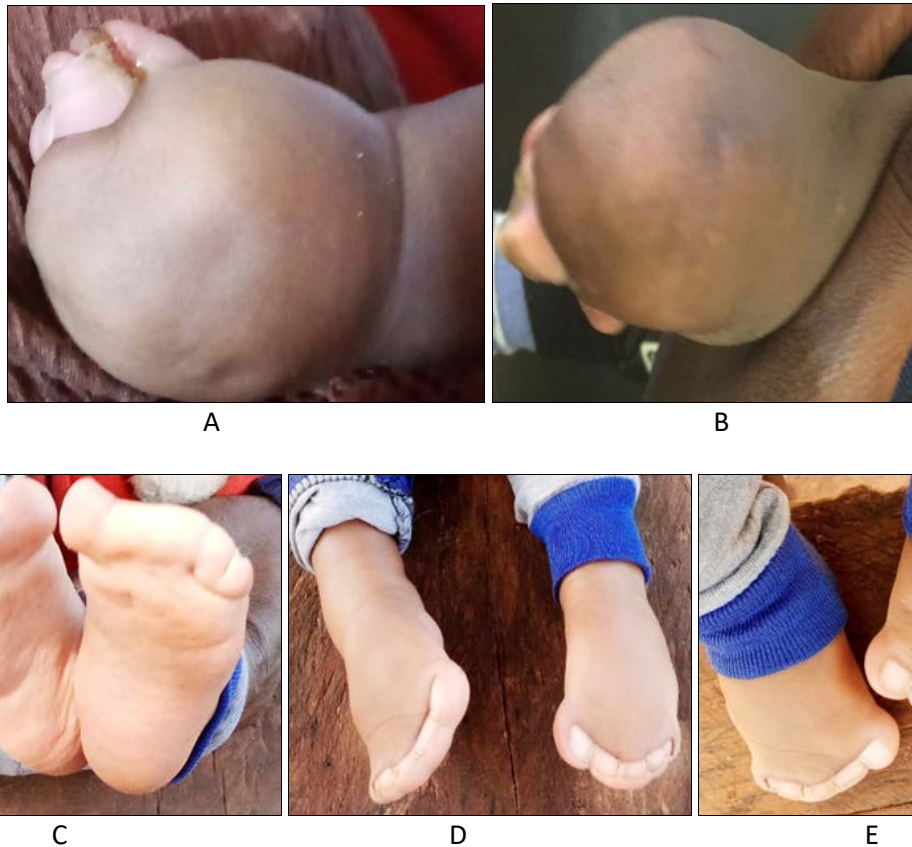


Fig 1: Clinical Features: A and B: complicated hand syndactyly with cup/muffle-like hand with single fused but furrowed nail. C, D and E: complete bilateral feet syndactyly with fused but furrowed nail.

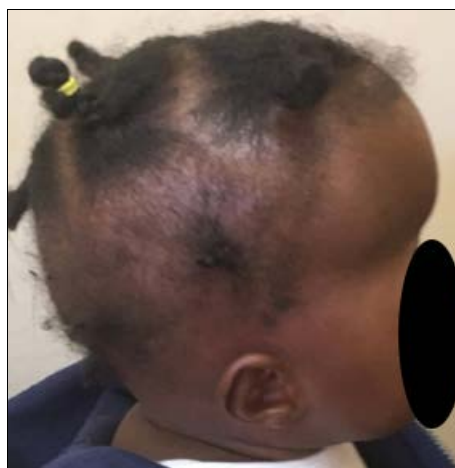

Fig 2: acrocephaly with occipital brachycephaly attributable to bicoronal synostosis A provisional diagnosis of Apert syndrome was made based on the above clinical features and relevant investigations advised.

Her hemogram was unremarkable. Renal and hepatic function tests were within normal limits for age. Radiographs of both hands showed complicated bilateral syndactyly with complete cutaneous fusion of all fingers with pre-axial rays in the web. Some of the phalanges were fused as a conglomerate mass of bones but metacarpal synostosis was not appreciated. Radiographs of the feet

demonstrated bilateral soft tissue syndactyly of all the toes but no associated phalangeal or metatarsal synostosis. Cranial ultrasound and CT scan head demonstrated bicoronal synostosis with bilateral exophthalmos but no brain abnormality. Cardiovascular investigations including ECG and echocardiography demonstrated a mild 0.5 cm septum secundum left to right Atrial Septal Defect.

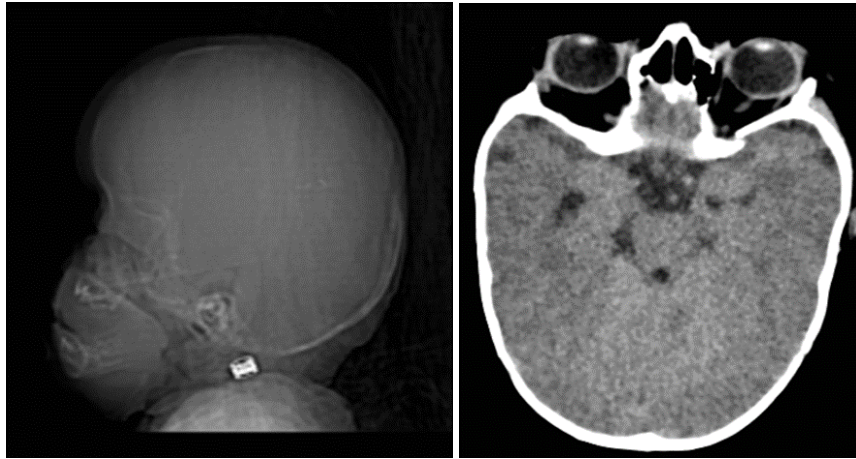


Fig 3: A. Sagittal head CT tomography demonstrating brachycephaly and acrocephaly. B. axial CT head demonstrating exophthalmos.

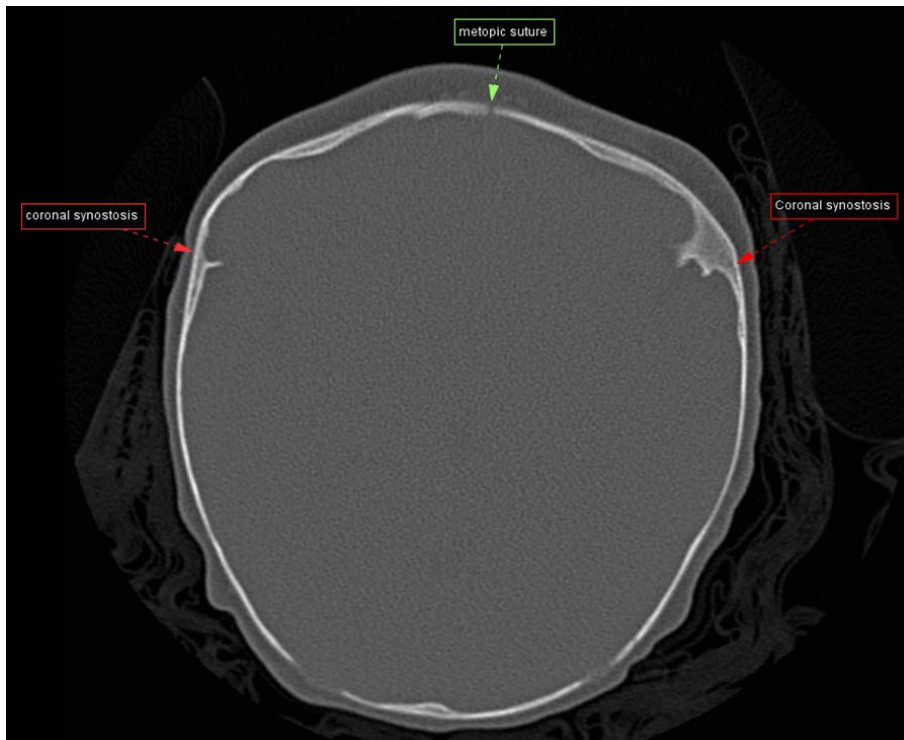


Fig 4: axial CT bone window demonstrating bicoronal synostosis with shallow anterior cranial fossa

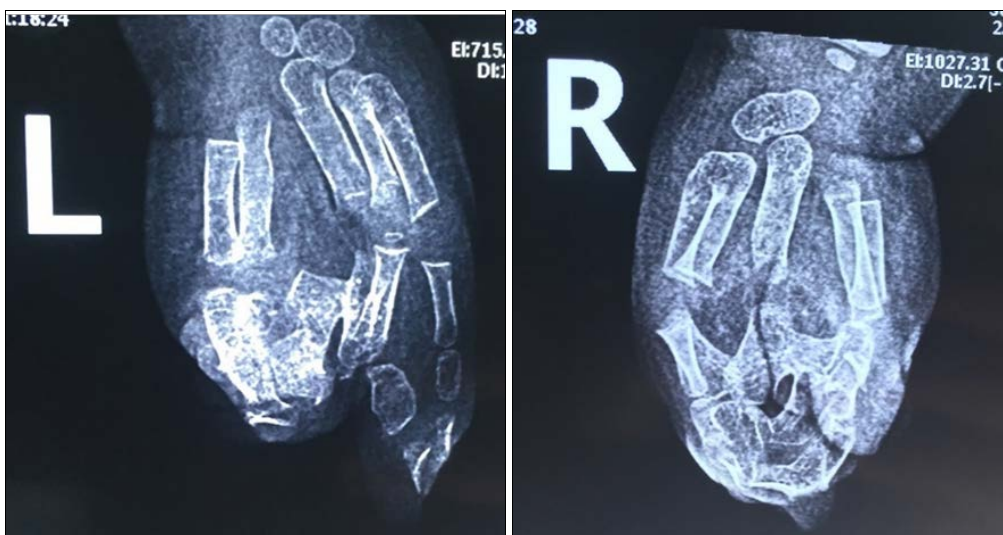

Fig 5: hand radiographs demonstrating complicated phalangeal synostosis into a conglomerate mass with associated symphalangism. Right hand radiograph demonstrating 1st and 2nd proximal metacarpal synostosis.

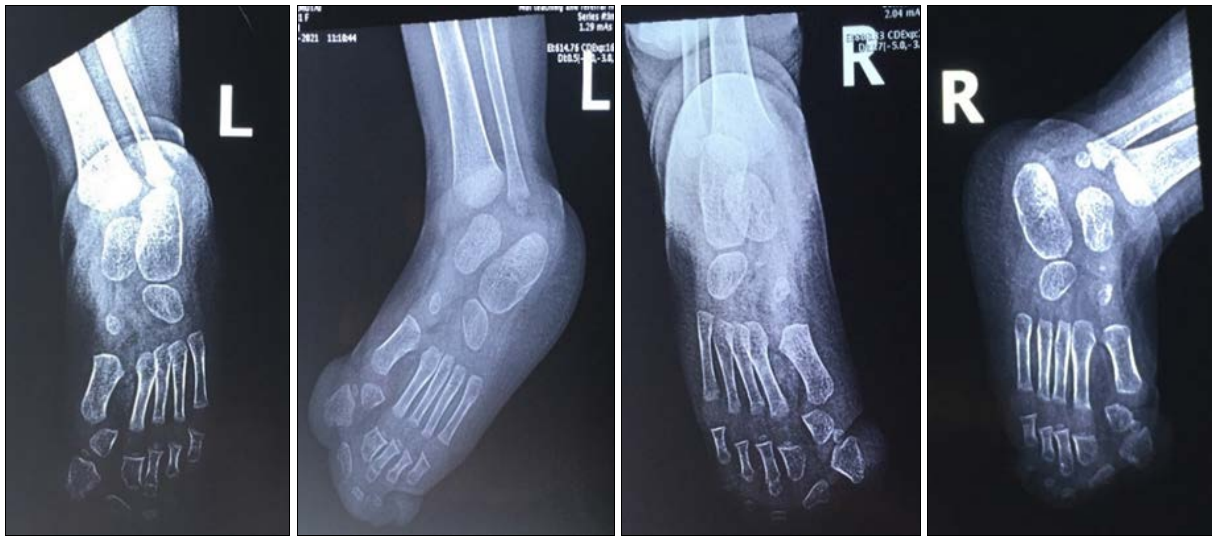

Fig 6: dedicated bilateral feet Xrays demonstrating complete soft tissue simple syndactyly with no bony synostosis.

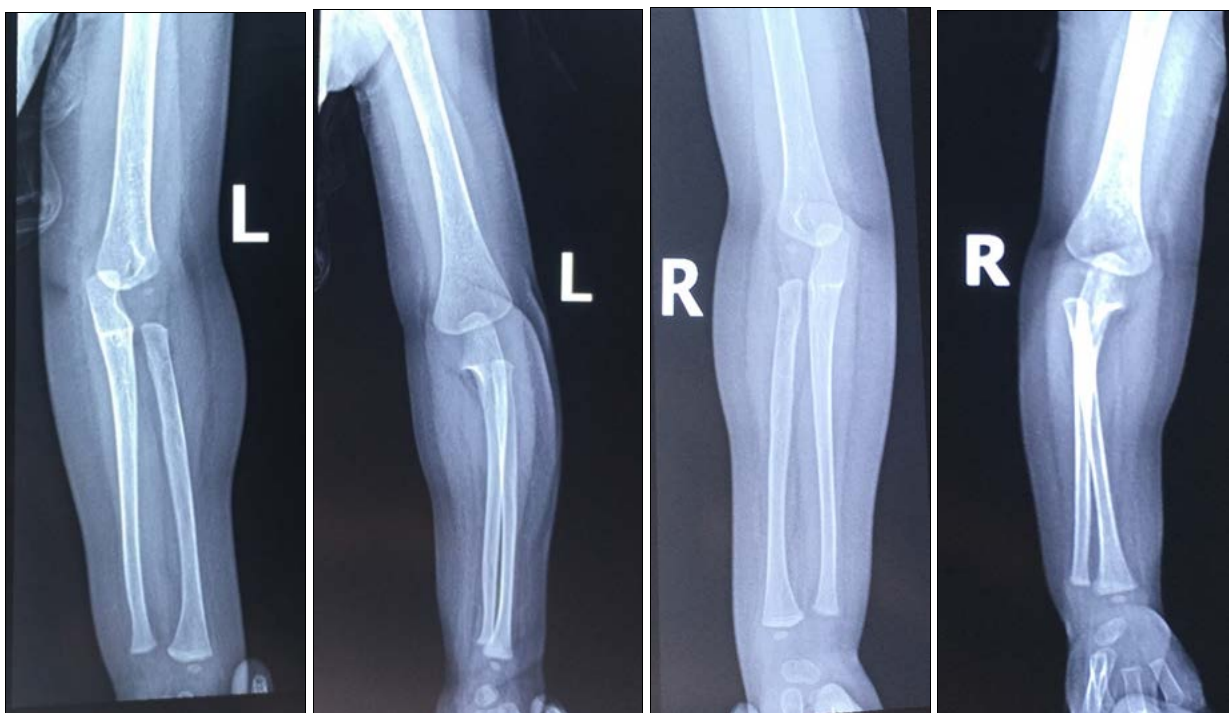

Fig 7: Normal radiusulnar Xrays AP + Lateral with no associated radial head dysplasia.

Subsequent reviews demonstrated a slight psychomotor developmental delay at 4 months denoted by the absence of head support, and grip was hard to appreciate because of the syndactyly. At 11 months however she was able to reach out for objects and she could vocalise with language limited to sounds in syllables.

Apert syndrome was diagnostically made supported by the following findings (in the absence of karyotyping and molecular tests):

Clinical findings: classical craniosynostosis with craniofacial dysmorphism, complex syndactyly of the four limbs and noted developmental delay.

Paraclinical investigative arguments: bicoronal synostosis and hand and foot syndactyly with associated symphalangism with associated atrial septal defect confirmed on echocardiogram

The confirmatory diagnostic test involving karyotyping and proteomic molecular biology for the chromosome 10 (locus q25, Ser252Trp and Pro253Arg) FGFR 2 mutation was limited by the high patient cost implication and the unavailability of this resource in our setup.

Instituted interventions included a multidisciplinary plastic and orthopaedic hand specialist surgeons staged syndactyly release carried out at 10 months of age.

The initial surgery employed a modified flat technique with the objective being to release and reconstruct the thumb bilaterally due to the expected digit length differences to avoid growth disturbances. The surgery had initially been slotted for at 4-6 months of age as per literature recommendation but due to withholding of elective surgeries as per the COVID 19 pandemic guidelines the earliest the surgery could be slotted was at 10 months of age. Planned coronal suture release/cranioplasty by the neurosurgery team was not possible due to the delays by the

covid 19 pandemic. The ASD was categorised small at 0.5cm and managed conservatively.

We did a zigzag z-plasty advancement dorsal fasciocutaneous flap presurgical mark up with apices centred on the estimated interphalangeal joints. A dorsal rectangular commissure sized at $\frac{3}{4}$ of the proximal phalanx length was made. Ideal mark-ups in extension were not possible due to the underlying symphalangism. Synostosis was separated using a chisel. The underlying neurovascular bundles were identified and protected. Intraoperative challenges involved aberrant anatomy due to the more

complex deformity and inability to delineate the Cleland ligament to aid in protected neurovascular dissection. Full thickness skin grafts harvested from the inguinal crease were used to close the deficits as needed. Closure with absorbable sutures was done. Initial outpatient clinic review demonstrated good early outcomes without any flap necrosis. The patient is currently on bimonthly orthopaedic and plastic surgical follow ups with no current concerns and no surgical site concerns. The second stage of the surgery is slotted 6 months post operatively in order to facilitate full recovery and healing of the surgical site.

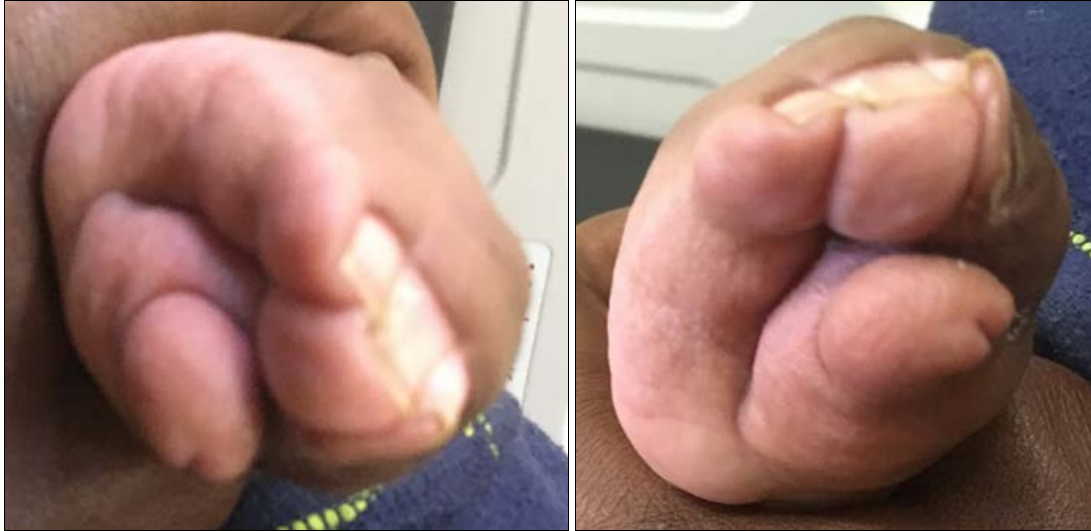

Fig 8: Post-surgical review at 6 weeks/findings demonstrating no discernible features of creep.

Discussion

Apert syndrome is a rare congenital acrocephalosyndactyly anomaly occurring with a reported frequency of 1 in 65,000 live births [5]. It belongs to the five literature-described craniosynostosis syndromes resulting from allelic (C to G at position 755) mutations of the fibroblast growth-factor receptor 2 (FGFR2) gene [1]. The first documented case was described by Apert in 1906, with the proposed name acrocephalosyndactyly, having described the anomalies characteristic to this syndrome. Though rare some occurrences of apert syndrome and management in Africa have been reported [2, 8] but local studies/findings could not be identified during the literature search used for this report. The dysmorphic features involve the extremities and the skull with associated cognitive delays and mental retardation [1, 2, 4].

The orthopaedic features characteristic of this syndrome (most of which were demonstrable in our case) are:

1. Simple hand and foot syndactyly.
2. short (radially-deviated) thumb
3. symphalangism in both hands
4. Single grooved nail bed
5. Premature craniosynostosis

Of the Non-Orthopedic anomalies expected (ventriculomegaly, corpus callosum agenesis, congenital heart anomalies (VSD, ASD, coarctation of aorta, dextrocardia), pulmonary aplasia, hypertrophic pyloric stenosis, polycystic kidney and hydronephrosis [4] mild ASD was noted in our case. Documented associated orthopaedic-specific features including very short or absent neck of scapula, small and dysmorphic capitulum multiple

epiphyseal dysplasia and flat radial head [4] were not appreciated in our patient.

However in our case we found a complicated syndactyly corresponding to the type IVb Haas Type [6] extension of the Temtamy and McKusick classification [7] with a cup/mitten like complicated bilateral hand syndactyly with symphalangism and single fused furrowed nail and simple bilateral sock foot syndactyly similar to that befitting Haas type IV -Andersen-Hansen subtype b [6].

The primary surgical objective in syndactyly is to create a functional and esthetic hand by separating the fused digits and create a normal web space [5]. The recommended timing of syndactyly separation is from 3 to 24 months. Complex/complicated syndactylies benefit more from staged surgeries ≥ 3 months apart and some studies have demonstrated good outcomes [5] but in our current case due to the Covid-19 pandemic these timelines were delayed with our first surgery at 10 months of age.

Syndactyly release is among the commonest congenital hand surgical procedures [9]. Due to the increased surface area of the separated fingers and inadequacies at the rectangular neo-commissure sides proximally skin grafts, like in our case, are often used despite advances in graft less techniques [5, 9]. Based on the complex nature of our bilateral syndactyly we staged our surgery as described in literature with favourable initial outcomes [8].

Currently no approved cure for Apert syndrome exists, but, symptomatically, interventions may be instituted to facilitate normalcy in activities of daily living. Prenatally, second trimester prenatal ultrasound and amniocentesis with amniotic fluid karyotyping studies can detect this defect, prognosis explained and a judicious decision taken.

Postnatal management (like in our case) depends on team work by orthopaedic hand surgeon, plastic and reconstructive surgeons, paediatricians, neuroradiologist, and paediatric surgeon and paediatric anaesthetist.

Prenatal diagnosis is through amniocentesis with amniotic fluid karyotyping and gene analysis, but sparsity of genetic testing laboratories and high cost implications limits this option in our set up. Postnatal, the characteristic morphological anomalies (skull and extremities) are suggestive and highly diagnostic of Apert syndrome as described in our case. In our region, there is overt absence of dedicated cytogenetic laboratories with reliance on foreign or external laboratories.

These confirmatory diagnostic resource limitations have also been noticed in other studies and the classical clinical and paraclinical findings have sometimes been the only evidence that some authors have relied upon to make a diagnosis of Apert syndrome^[2, 10].

The management of Apert syndrome involves a multidisciplinary approach with the prescription of a therapeutic schedule.

Conclusions

This case report made it possible to highlight the confirmatory diagnostic limitations of doing molecular/karyotyping studies for this rare syndrome and the multidisciplinary management options and possible challenges even in the midst of the COVID -19 pandemic.

Statements

Acknowledgement

The authors would like to acknowledge the jovial, energetic young inspiring infant without which this article would not have been possible and her overly forthcoming mother.

Statement of Ethics

Study approval statement: The case study is approval exempt but has met the ethical considerations during its formulation.

Consent to publish statement: written informed consent (attached) was obtained from the parent for publication of the details of the medical case and any accompanying images.

Conflict of Interest Statement

The authors have no conflicts of interest to declare.

Funding Sources

The study was fully funded by the researchers and no external funding/sponsorship was sought.

References

1. Ibrahim OA, Chiu ES, McCarthy JG, Mohammadi M. Understanding the molecular basis of Apert syndrome. *Plastic and Reconstructive Surgery* 2005;115:264-70.
2. Barro M, Ouedraogo YS, Nacro FS, Sanogo B, Kombasséré SO, Ouermi AS *et al.* Apert syndrome: Diagnostic and management problems in a resource-limited country. *Pediatr Rep* 2019;11(4):78-80.
3. Saritha S, Sumangala S, Supriya G, Kumar M. Apert syndrome Acrocephalo syndactyly: A case report. *Int J Res Med Sci* 2013;1(1):36.

4. Datta S, Saha S, Kar A, Mondal S, Basu S. Apert syndrome. *J Assoc Physicians India* 2014;62(9):845-7.
5. Fearon JA. Treatment of the hands and feet in Apert syndrome: An evolution in management. *Plast Reconstr Surg* 2003;112(1):1-12.
6. Malik S. Syndactyly: Phenotypes, genetics and current classification. *European Journal of Human Genetics* 2012;20:817-24.
7. Temtamy SA, McKusick VA. The genetics of hand malformations 1978.
8. Chira M, Kortor J. Management of complicated syndactyly in Apert's syndrome: our experience. *Niger J Plast Surg* 2009, 5(2).
9. Barabás AG, Pickford MA. Results of syndactyly release using a modification of the Flatt technique. *J Hand Surg Eur* 2014;39(9):984-8.
10. Kumar T, Arora N, Puri G, Konidena A. Apert's syndrome: A rare case. *J Indian Acad Oral Med Radiol* 2016;28(1):83.